

**DATE PRESENTING CLINICAL SIGNS**

5/23/22

Presented for routine wellness. History of heart murmur first ausculted 1/6 October 2021. Worsening murmur to 2-3/6 ausculted on recent exam 5/19/22. Dog is asymptomatic at home. Senior screening labs showed mild elevation of ALKP.

PATIENT

Baby Love Wallace

Current Medications: Preventions only.

Lab Results: 5/19/22 ALKP 157. BUN 38. T4 normal, CBC normal. 4DX negative.

Date of Previous IntraPet Ultrasound: No previous.

Sedation: Not required to complete full diagnostic ultrasound.

Stat Report: Not requested.

Imaging Performed By: Andi Parkinson BS RDMS

SPECIES

Canine

BREED

Chihuahua

ULTRASONOGRAPHIC EXAMINATION OF THE ABDOMEN**Urinary System**

The urinary bladder, trigone, and pelvic urethra are normal in thickness and the mucosal surface is smooth.

The bladder lumen is moderately distended with anechoic urine. No masses, inflammatory changes or calculi are observed. The region of the trigone is normal.

SEX

Female, spayed

AGE

9/5/2007

The left kidney is normal size (2.95 cm in length); normal shape and architecture with smooth peripheral margins. There is a normal 1:3 cortex to medulla ratio with mild to moderate loss of corticomedullary distinction. There is no evidence of pyelectasia, nephroliths, infarcts or hydroureter.

WEIGHT

5.7 lbs.

The right kidney is normal size (2.69 cm in length); normal shape and architecture with smooth peripheral margins. There is a normal 1:3 cortex to medulla ratio with mild to moderate loss of corticomedullary distinction. There is no evidence of pyelectasia, nephroliths, infarcts or hydroureter.

INTERPRETED BY

Andrea Nicastro, DVM,
Diplomate ACVIM
(Small Animal Internal
Medicine)

Adrenal Glands

The left adrenal gland is normal size (0.36 cm at cranial pole) (0.46 cm at caudal pole) (1.16 cm in length); normal shape; homogenous parenchyma. The glandular echogenicity and detail are unremarkable. Capsule, cortex, and medullary definition are normal. The phrenicoabdominal vein and surrounding vasculature are normal.

HOSPITAL NAME

Everhart VH

The right adrenal gland is normal size (0.42 cm at cranial pole) (0.43 cm at caudal pole) (1.08 cm in length); normal shape; homogenous parenchyma. The glandular echogenicity and detail are unremarkable. Capsule, cortex, and medullary definition are normal. The phrenicoabdominal vein and surrounding vasculature are normal.

REFERRING VET

Dr. Notarangelo

Spleen

The spleen is normal in size (1.16 cm in width at the level of the hilus) with a normal capsular contour. There is appropriate echogenicity and echotexture. No focal lesions are observed. Splenic vasculature is normal.

INVOICE**Liver**

The liver is subjectively small in size with normal curvilinear peripheral contours. The parenchyma is hypoechoic relative to the spleen with a slightly nodular appearance. Vascular and biliary tracts are of normal volume with no evidence of congestion. The portal vein: caudal vena cava ratio is approximately 1:1. The gall bladder lumen is moderately distended. The wall is thin and smooth. A small amount of echogenic debris is observed within the lumen, some of which is gravity-dependent and some of which is suspended. The cystic and common bile ducts are normal/not seen.

Gastrointestinal

The stomach and intestine are free of stasis and exhibit normal peristaltic activity. The gastric lumen is not distended. The gastric wall and pylorus are normal in thickness with a normal layering pattern. The pyloric outflow tract is patent. The small intestinal lumen is not dilated. The small intestinal wall thickness is normal with a normal layering pattern and appropriate mural detail. Discreet masses are not identified. The colonic wall is normal. No obstructive disease is noted.

Pancreas

The region of the pancreas is isoechoic relative to surrounding omental fat. No obvious parenchymal abnormalities are observed. There is no evidence of regional inflammation or effusion.

Free Abdomen

The peritoneal cavity is normal. There is no evidence of inflammation or effusion. The abdominal lymph nodes are normal/not visible.

ULTRASONOGRAPHIC FINDINGS

Primary Findings:

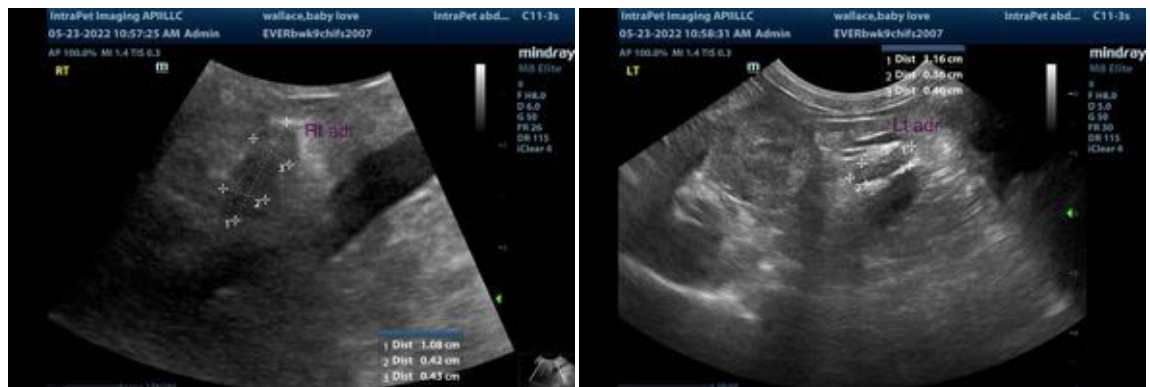- The microhepatica may be a normal variant for this patient or may be secondary to chronic hepatic disease or portal hypoplasia. The hepatic nodules may be secondary to regenerative nodular hyperplasia, inflammatory disease, fibrosis, other.

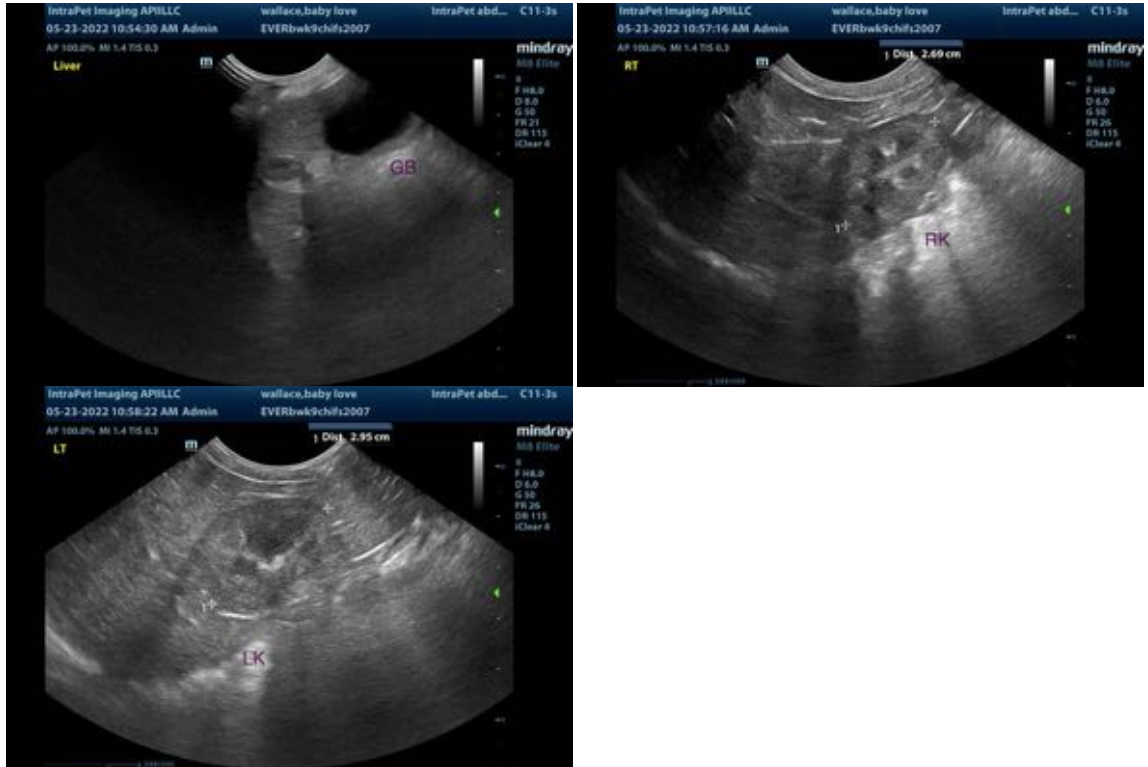
Secondary Findings:

- Bilateral non-specific chronic age-related renal changes.

INTERPRETATION OF THE FINDINGS & FURTHER RECOMMENDATIONS

Consider pre- and post-prandial serum bile acids to assess hepatic function. If abnormal, hepatic tissue sampling (i.e., surgical biopsy) may be necessary to get a definitive diagnosis. Otherwise, consider serial monitoring (i.e., every 3-4 months) of the patient's liver values to assess for progression.





The information and recommendations provided are based on the images presented by the referring veterinarian. No evaluation can be communicated regarding pathology that was not visible in the image/video clips provided.

Thank you for this referral. If the clinical or image interpretation does not parallel your findings or if I can be of any further assistance please contact me.

Andrea Nicastro, DVM, Diplomate ACVIM (*Small Animal Internal Medicine*)
Andrea.nicastro@sonopath.com