



**PATIENT**

Duke Eyring

**SPECIES**

Canine

**BREED**

Labrador Retr

**SEX**

Male Neutered

**AGE**

1/9/2015

**WEIGHT**

85.8 lb/38.9186 kg

**INTERPRETED BY**

Andrea Nicastrò DVM  
Diplomate ACVIM  
(Sm Animal Internal Med)

**IMAGING  
PERFORMED BY**

Andrea Nicastrò DVM  
Diplomate ACVIM  
(Sm Animal Internal Med)

**HOSPITAL NAME**

Sun Dog Cat Moon

**REFERRING VET**

Dr Fetterolf

**INVOICE**

23043

**DATE**

5-21-26

**PRESENTING CLINICAL SIGNS**

- Started urinating in house 3 times over recent period, including at 3 AM (unusual behavior)
- Client reports he typically holds urine well and has never urinated in house before
- Still urinating outside normally but requiring more frequent trips (3 AM outing unusual)
- Normal appetite and eating habits
- Always drinks large amounts of water
- PE - cranial to mid organomegaly

Abnormal lab-work values:

- AST (SGOT) 301 15-66 IU/L HIGH
- ALT (SGPT) 596 12-118 IU/L HIGH
- Alk Phosphatase 3038 5-131 IU/L HIGH
- GGTP 33 1-12 IU/L HIGH Result Verified
- Total Bilirubin 0.8 0.1-0.3 mg/dL HIGH
- Cholesterol 382 92-324 mg/dL HIGH
- Triglycerides 259 29-291 mg/dL
- Amylase 1441 290-1125 IU/L HIGH
- PrecisionPSL 361 24-140 U/L HIGH
- Platelet Count 506 170-400 103/mL HIGH
- T4 0.5 0.8-3.5 mg/dL LOW

U/A:

- Specific Gravity 1.015 1.015-1.050
- pH 7.0 5.5-7.0
- Protein 2+
- Inactive sediment
- Current Medications: Librela, Carprofen, Gabapentin

- Senior bloodwork panel
- Sedated radiographs of hips, stifles, thorax, abdomen, carpi, and tarsi

Radiology Report  
Patient: Duke Eyring  
Date: 2025-10-06

These were screening radiographs for mobility issues.  
Radiographic Impressions

1. Multifocal degenerative joint disease affecting the spine (thoracic and lumbar), shoulders, elbows, stifles, and metacarpophalangeal joints. The hip changes are considered a likely normal variant and not clinically significant.
2. Hepatomegaly.
3. Mild, generalized bronchial pattern, likely an incidental aging change.
4. History of bilateral TPLO surgery with stable implants and moderate secondary osteoarthritis.
5. Overweight body condition.

**ULTRASONOGRAPHIC EXAMINATION OF THE ABDOMEN**



**PATIENT**

Duke Eyring

**SPECIES**

Canine

**BREED**

Labrador Retr

**SEX**

Male Neutered

**AGE**

1/9/2015

**WEIGHT**

85.8 lb/38.9186 kg

**INTERPRETED BY**

Andrea Nicastro DVM  
Diplomate ACVIM  
(Sm Animal Internal Med)

**IMAGING  
PERFORMED BY**

Andrea Nicastro DVM  
Diplomate ACVIM  
(Sm Animal Internal Med)

**HOSPITAL NAME**

Sun Dog Cat Moon

**REFERRING VET**

Dr Fetterolf

**INVOICE**

23043

**DATE**

5-21-26

**Urinary System**

The urinary bladder is moderately distended. The wall in the region of the apex is mildly-thickened (up to 0.51 cm) with an irregular mucosal surface. The wall tapers to a normal thickness as it extends towards the cystourethral junction. A large amount of echogenic- mineralized debris/sand is observed within the lumen. No distinct cystic calculi are observed. The region of the trigone and the proximal urethra, visible to a depth of 2.0 cm, are normal.

The prostate is normal in size (0.98 cm in width) and shape. Parenchyma is homogenous. The prostatic urethra appears normal without evidence of dilation or obstruction.

The left kidney is normal in size (7.68 cm in length) with a normal shape, architecture and smooth peripheral margins. There is a normal 1:3 cortex to medulla ratio with minimal- to mild loss of corticomedullary distinction. There is no evidence of pyelectasia, nephroliths, infarcts or hydroureter. Renal vasculature is normal.

The right kidney is normal in size (7.77 cm in length) with a normal shape, architecture and smooth peripheral margins. There is a normal 1:3 cortex to medulla ratio with minimal- to mild loss of corticomedullary distinction. There is no evidence of pyelectasia, nephroliths, infarcts or hydroureter. Renal vasculature is normal.

**Adrenal Glands**

The left adrenal gland is normal in size (0.82 cm at cranial pole) (0.78 cm at caudal pole) with a normal shape and homogenous parenchyma. The glandular echogenicity and detail are unremarkable. Capsule, cortex, and medullary definition are normal. The phrenicoabdominal vein and surrounding vasculature are normal.

The right adrenal gland is normal in size (1.34 cm at cranial pole) (0.84 cm at caudal pole) with a normal shape and homogenous parenchyma. The glandular echogenicity and detail are unremarkable. Capsule, cortex, and medullary definition are normal. The phrenicoabdominal vein and surrounding vasculature are normal.

**Spleen**

The spleen is overall normal in size (1.79 cm in width at the level of the hilus). A 1.17 x 1.07 cm hyperechoic- to heterogenous nodule is observed at the mid- to caudal aspect. A few hyperechoic nodules are also seen in other parts of the parenchyma. The remaining parenchyma is of appropriate echogenicity and echotexture. Splenic vasculature is normal with no evidence of thrombosis.

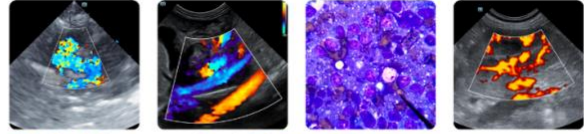
**Liver**

The liver is enlarged, with irregular peripheral contours. An 11.5 x 7.5 cm well-circumscribed, isoechoic- to heterogenous mass with hyperechoic foci is arising from the left side at the caudal aspect. In the remainder of the liver, the parenchyma is isoechoic relative to the spleen, and mildly heterogenous. Hepatic vasculature and intrahepatic biliary tracts are of normal volume with no evidence of congestion. The portal vein to caudal vena cava ratio is approximately 1: 1.

The gallbladder lumen is moderately distended. The wall is thin and smooth. A moderate amount of aggregated, echogenic, partially dependent sludge is observed within the lumen. The cystic and common bile ducts are normal/not seen.

**Gastrointestinal**

The gastric lumen is not distended. The gastric wall is normal in thickness with a normal layering pattern. The small intestinal lumen is not dilated. The small intestinal wall is normal in thickness with a normal layering pattern and appropriate mural detail. Discreet masses are not identified. The colonic wall is normal. There is no evidence of an obstructive pattern.



**PATIENT**

Duke Eyring

**SPECIES**

Canine

**BREED**

Labrador Retr

**SEX**

Male Neutered

**AGE**

1/9/2015

**WEIGHT**

85.8 lb/38.9186 kg

**INTERPRETED BY**

Andrea Nicastrò DVM  
Diplomate ACVIM  
(Sm Animal Internal Med)

**IMAGING  
PERFORMED BY**

Andrea Nicastrò DVM  
Diplomate ACVIM  
(Sm Animal Internal Med)

**HOSPITAL NAME**

Sun Dog Cat Moon

**REFERRING VET**

Dr Fetterolf

**INVOICE**

23043

**DATE**

5-21-26

**Pancreas**

The right limb of the pancreas is visible with normal curvilinear peripheral contours. The parenchyma is largely isoechoic relative to surrounding omental fat and slightly heterogenous in appearance. The pancreatic duct is visible but not overtly dilated. There is no evidence of peripancreatic inflammation or effusion.

**Lymph Nodes**

The abdominal lymph nodes are normal/not visible.

**Free Abdomen**

There is no obvious evidence of free fluid.

**Other**

A brief echocardiogram reveals no evidence of pericardial effusion or obvious right atrial/auricular mass.

**ULTRASONOGRAPHIC FINDINGS**

**Primary Findings**

- Large left caudal hepatic mass. Neoplasia (i.e., adenoma, adenocarcinoma, round cell tumor, sarcoma) is suspected, with a low possibility of a non-neoplastic process. The diffuse hepatic changes are nonspecific and could be secondary to inflammatory disease (i.e., cholangiohepatitis, chronic hepatitis), Leptospirosis, hepatotoxicosis, infiltrative neoplasia (i.e., lymphoma), vacuolar hepatopathy, regenerative nodular hyperplasia, other hepatopathy, or some combination thereof.

- The gallbladder changes could be consistent with cholestasis, fasting, or an emerging mucocele.
- The larger splenic nodule is suggestive of a myelolipoma, with a lower possibility of more insidious splenic pathology. The smaller hyperechoic nodules are most consistent with myelolipomas
- Urinary bladder debris/sand with wall changes suggestive of cystitis

**Secondary Findings**

- The pancreatic changes are most consistent with age-related parenchymal remodeling, potentially secondary to a prior inflammatory episode, early fibrosis or chronic pancreatitis.
- Minor bilateral nonspecific age-related renal changes

**INTERPRETATION OF THE FINDINGS & FURTHER RECOMMENDATIONS**

- Three-view thoracic radiographs are recommended to assess for pulmonary metastases. If there is no evidence of pulmonary metastatic disease, consider excisional biopsy of the hepatic mass. Also obtain biopsies of the other liver lobes. The gall bladder should also be assessed at the time of surgery. Fine-needle aspiration of the mass can be considered prior to surgery. However, it can be difficult to differentiate hyperplasia, from adenoma, from adenocarcinoma cytologically. Histopathology will likely be necessary to get a definitive diagnosis.
- Given the gall bladder changes, Ursodeoxycholic acid (Ursodiol) is recommended. Serial sonographic monitoring (e.g., every 4-6 weeks) of the gall bladder is recommended to assess for progression to a fully formed mucocele. If progression occurs, a cholecystectomy may be warranted.



**PATIENT**

Duke Eyring

- Given the urinary bladder wall changes and the patient's clinical signs, consider a urine culture and sensitivity to assess for occult infection.

**SPECIES**

Canine

**BREED**

Labrador Retr

**SEX**

Male Neutered

**AGE**

1/9/2015

**WEIGHT**

85.8 lb/38.9186 kg

**INTERPRETED BY**

Andrea Nicastro DVM  
 Diplomate ACVIM  
 (Sm Animal Internal Med)

**IMAGING PERFORMED BY**

Andrea Nicastro DVM  
 Diplomate ACVIM  
 (Sm Animal Internal Med)

**HOSPITAL NAME**

Sun Dog Cat Moon

**REFERRING VET**

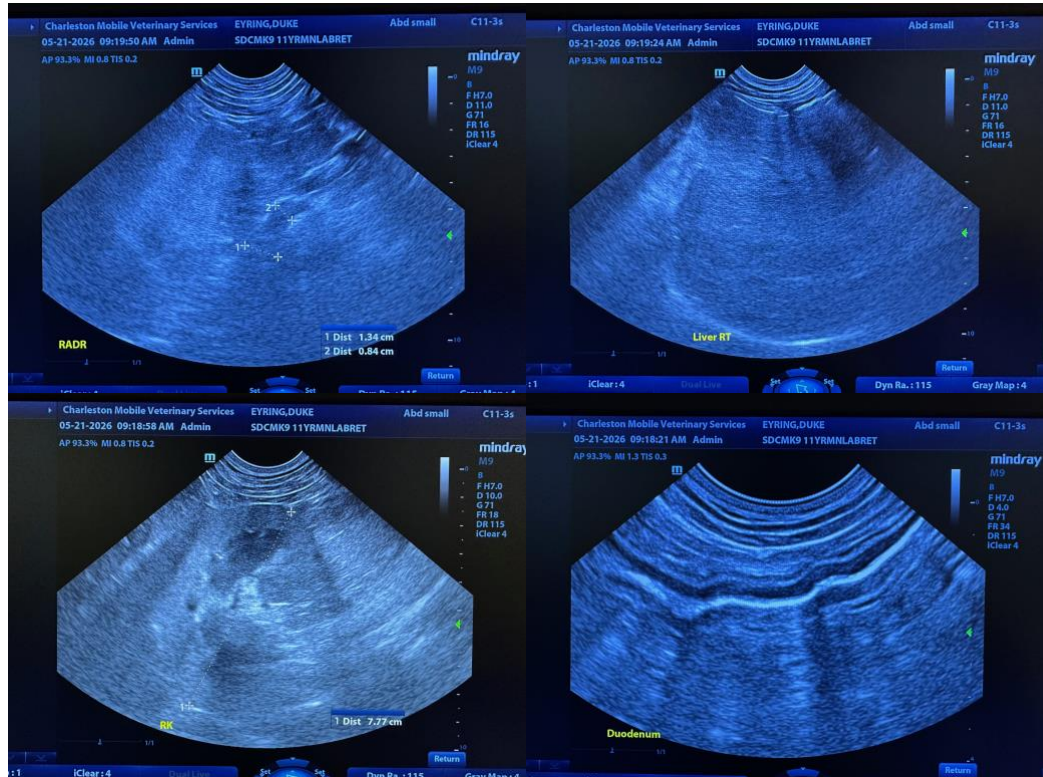
Dr Fetterolf

**INVOICE**

23043

**DATE**

5-21-26





**PATIENT**

Duke Eyring

**SPECIES**

Canine

**BREED**

Labrador Retr

**SEX**

Male Neutered

**AGE**

1/9/2015

**WEIGHT**

85.8 lb/38.9186 kg

**INTERPRETED BY**

Andrea Nicastrò DVM  
 Diplomate ACVIM  
 (Sm Animal Internal Med)

**IMAGING PERFORMED BY**

Andrea Nicastrò DVM  
 Diplomate ACVIM  
 (Sm Animal Internal Med)

**HOSPITAL NAME**

Sun Dog Cat Moon

**REFERRING VET**

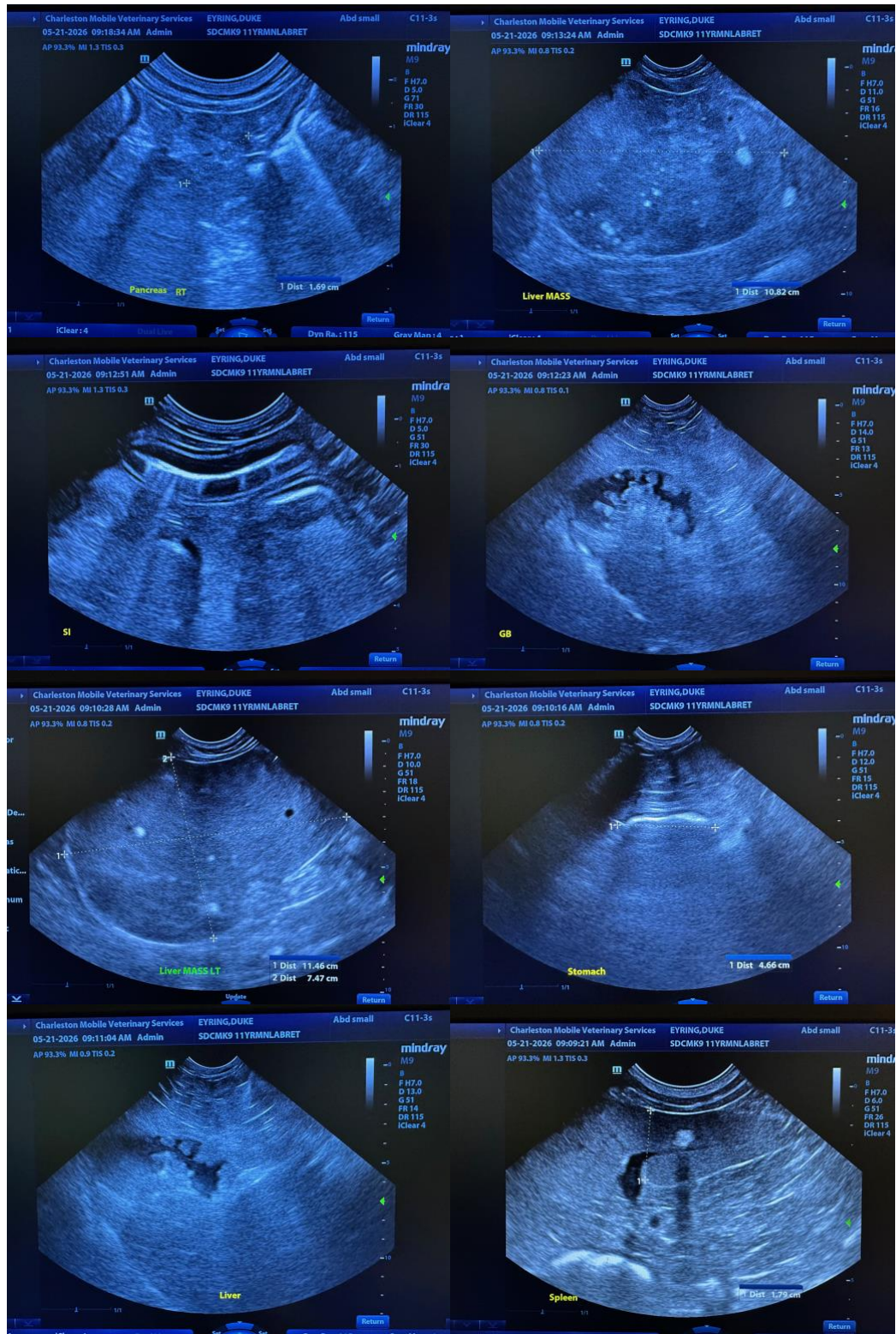
Dr Fetterolf

**INVOICE**

23043

**DATE**

5-21-26





**PATIENT**

Duke Eyring

**SPECIES**

Canine

**BREED**

Labrador Retr

**SEX**

Male Neutered

**AGE**

1/9/2015

**WEIGHT**

85.8 lb/38.9186 kg

**INTERPRETED BY**

Andrea Nicastro DVM  
 Diplomate ACVIM  
 (Sm Animal Internal Med)

**IMAGING PERFORMED BY**

Andrea Nicastro DVM  
 Diplomate ACVIM  
 (Sm Animal Internal Med)

**HOSPITAL NAME**

Sun Dog Cat Moon

**REFERRING VET**

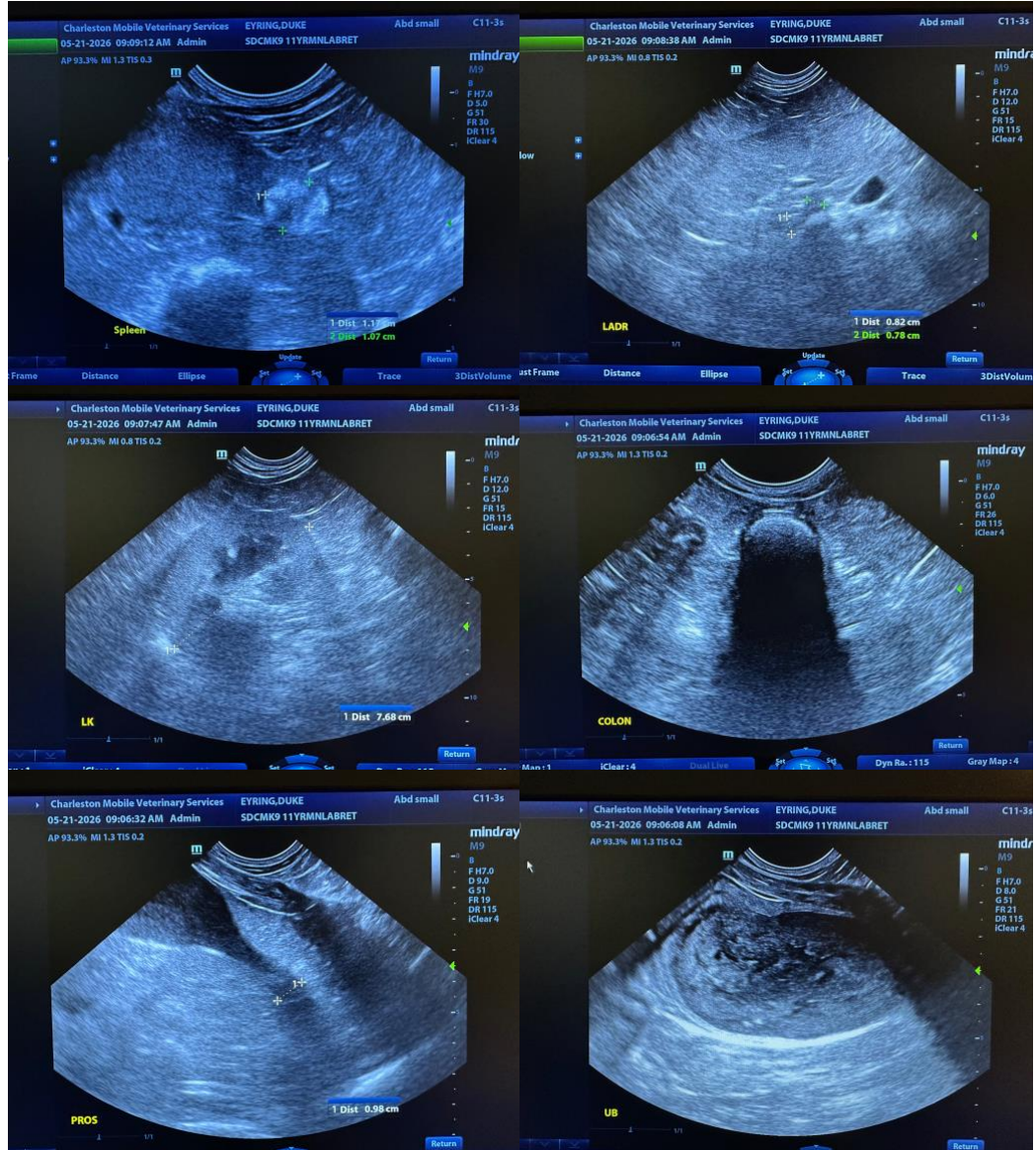
Dr Fetterolf

**INVOICE**

23043

**DATE**

5-21-26



The information and recommendations provided are based on the images presented by the referring veterinarian/sonographer. No evaluation can be communicated regarding pathology that was not visible in the image/video clips provided.

Thank you for this referral. If the clinical or image interpretation does not parallel your findings or if I can be of any further assistance, please contact me.

**Andrea Nicastro, MPH, DVM, Diplomate DACVIM (Small Animal Internal Medicine)**  
[info@SonoPath.com](mailto:info@SonoPath.com)