

PATIENT

Max Yousif

PRESENTING CLINICAL SIGNS

SPECIES

Canine

History: 9 yo MN Lab mix with history of diarrhea and decreased appetite. Symptoms started about a month ago. At that time lab work showed increased PSL followed by mild to moderate increases in ALT and ALP. Patient was prescribed i/d low fat diet, amoxicillin and metronidazole. Stools improved but are still soft. ALT has resolved but ALP is still moderately increased, and CPL has increased. No pain on abdominal palpation but patient is losing muscle mass.

BREED

Lab Mix

Abnormal PE/Chem/CBC/UA Results: See attached

SEX

Neutered Male

Urinary System

The urinary bladder and visible portion of the pelvic urethra are normal for the degree of luminal distension. The urine is anechoic with no evidence of debris. Cystic calculi and discrete masses are not observed. The region of the trigone and the visible of the proximal urethra are normal.

AGE

9 years

The prostate is normal in size (0.81 cm in width) and shape. Parenchyma is homogenous. The prostatic urethra appears normal without evidence of dilation or obstruction.

WEIGHT

68 lbs

The left kidney is normal size (7.23 cm in length); normal shape and architecture with smooth peripheral margins. There is a normal 1:3 cortex to medulla ratio with normal corticomedullary distinction. There is no evidence of pyelectasia, nephroliths, infarcts or hydronephrosis. Renal vasculature is normal.

INTERPRETED BY

Andrea Nicastro,
DVM, Diplomate
ACVIM (Small Animal
Internal Medicine)

The right kidney is normal size (7.35 cm in length); normal shape and architecture with smooth peripheral margins. There is a normal 1:3 cortex to medulla ratio with minimal to moderate loss of corticomedullary distinction. A 0.78 cm cortical cyst is visualized at the caudal aspect. There is no evidence of pyelectasia, nephroliths, infarcts or hydronephrosis.

IMAGING PERFORMED BY

Emily Kirk

Adrenal Glands

The caudal pole is visualized and is normal in size (0.71 cm in width), with a normal shape, glandular echogenicity and detail. Surrounding vasculature appears normal.

HOSPITAL NAME

Shiloh AH

The region of the right adrenal gland is evaluated. No obvious pathology is observed.

Spleen

The spleen is normal in size (2.41 cm in width at the level of the hilus) with a normal capsular contour. There is appropriate echogenicity and echotexture. One-two, small, ill-defined hypoechoic nodules are observed, the largest measuring 0.73 cm in diameter. Splenic vasculature is normal.

REFERRING VET

Emily Kirk

Liver

INVOICE

10950

The liver is subjectively prominent in size with swollen curvilinear peripheral contours. The parenchyma is isoechoic relative to the spleen and exhibits mild heterogeneity. No distinct focal lesions are observed. Hepatic vasculature and biliary tracts are of normal volume with no evidence of congestion.

DATE

5/20/22

The gall bladder lumen is moderately distended. The wall is thin and smooth. A small amount of mostly gravity dependent debris is observed within the lumen. The cystic and common bile ducts are normal/not seen.

Gastrointestinal

The gastric lumen is not distended. The gastric wall is normal in thickness with a normal layering pattern. The small intestinal lumen is not dilated. The small intestinal wall thickness is normal with a normal layering pattern and appropriate mural detail. Discreet masses are not identified. The colonic wall is normal. No obstructive disease is noted.

Pancreas

The region of the pancreas is isoechoic relative to surrounding omental fat. No obvious parenchymal abnormalities are observed. There is no evidence of regional inflammation or effusion.

Free Abdomen

The peritoneal cavity is normal. There is no evidence of inflammation or effusion. The abdominal lymph nodes are normal/not visible.

ULTRASONOGRAPHIC FINDINGS

Primary Findings

- The diffuse hepatic changes are non-specific and could be consistent with vacuolar hepatopathy, regenerative nodular hyperplasia, and/or age-related remodeling. Inflammatory and infiltrative disease are considered less likely.

Secondary Findings

- The hypoechoic trends toward the benign (i.e., foci of lymphoid hyperplasia, extramedullary hematopoiesis, or similar). However, emerging neoplasia cannot be completely excluded.
- Minor, bilateral, age-related renal changes

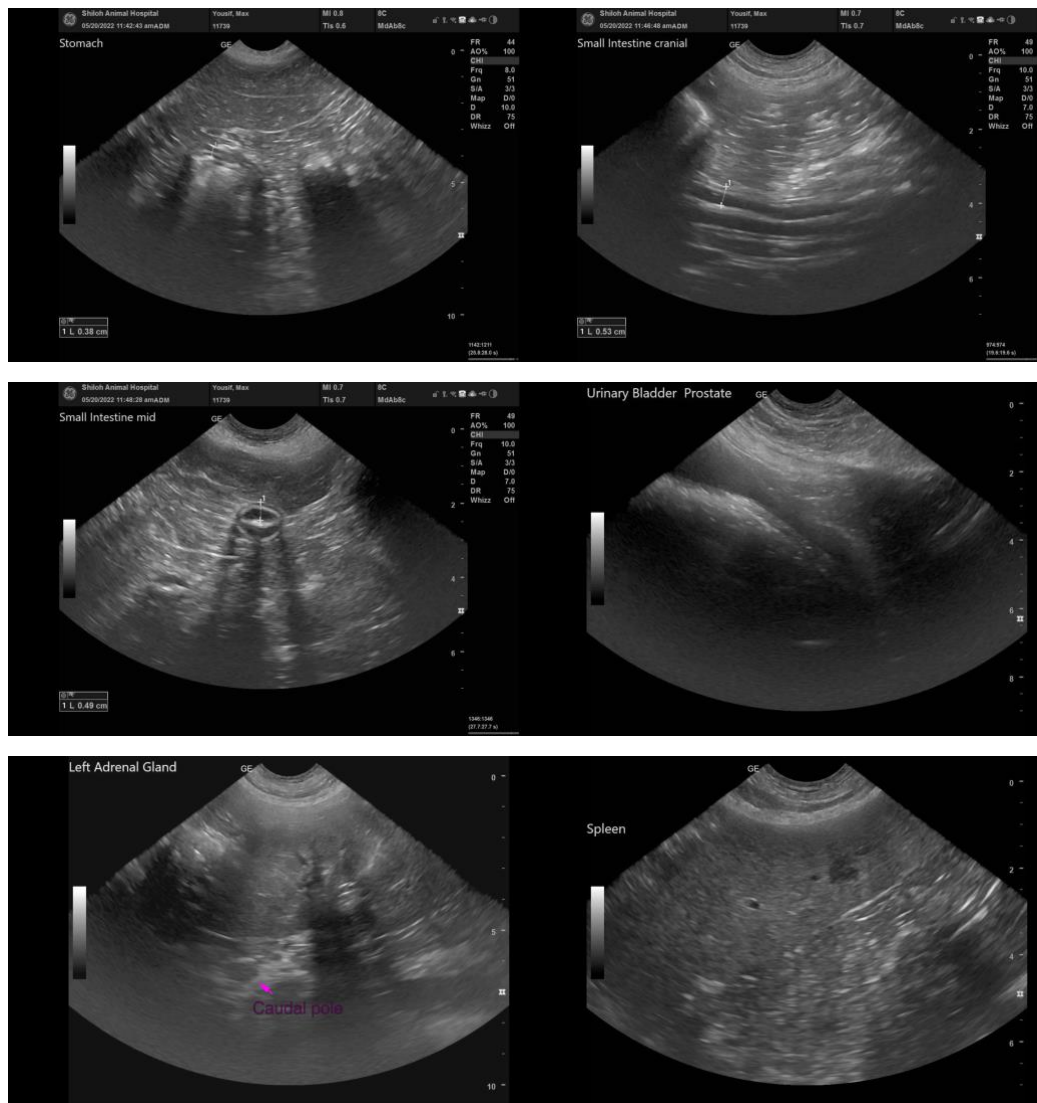
INTERPRETATION OF THE FINDINGS & FURTHER RECOMMENDATIONS

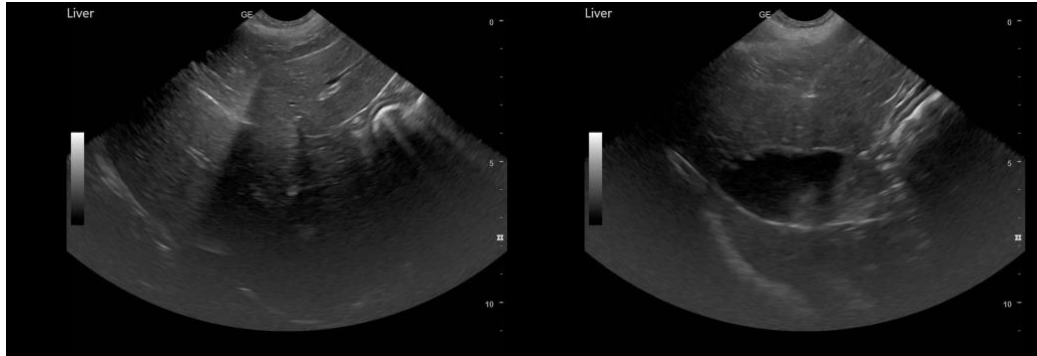
Serial monitoring (i.e., every 3-4 months) of the patient's liver values is recommended. If values continue to increase, a repeat abdomen ultrasound +/- a more advanced hepatic work-up (i.e., tissue sampling) may be warranted.

Regarding the diarrhea, the following diagnostics/treatment recommendations can be considered:

1. Serum cobalamin, folate, PLI and TLI
2. A fecal evaluation for ova/Giardia

3. Prophylactic deworming with Fenbendazole at 50 mg/kg once a day for 5 days is recommended. Repeat above protocol in 3 weeks.
4. A 6-week limited antigen diet trial to assess for food allergies.
5. Consider a 4-week course of Tylosin at 15-20 mg/kg by mouth every 12 hours as empirical treatment for small intestinal bacterial overgrowth.
6. A resting cortisol level to screen for hypoadrenocorticism. If resting cortisol level is < 2.0 mcg/dL, an ACTH stimulation test is recommended.
7. Depending on the results of the above diagnostics/therapeutics, endoscopic or surgical gastrointestinal biopsies may be warranted. Three-view thoracic radiographs should be performed prior to any anesthetic event.





The information and recommendations provided are based on the images presented by the referring veterinarian/sonographer. No evaluation can be communicated regarding pathology that was not visible in the image/video clips provided.

Thank you for this referral. If the clinical or image interpretation does not parallel your findings or if I can be of any further assistance, please contact me.

Andrea Nicastro, DVM, Diplomate DACVIM (Small Animal Internal Medicine)
info@SonoPath.com