

**DATE PRESENTING CLINICAL SIGNS**

5/2/22

Presented for 1 week history of hematuria. Historically diabetic patient, recent bilateral enucleation due to uncontrolled KCS and cataracts. PE: pink mm, euhydrated, normal auscultation, potbellied appearance, thin flaking skin, 1cm red dermal mass on R stifle.

**PATIENT**

Pearl McCully

Current Medications: Vetsulin 7 units BID.

Radiographs: Enlarged liver, suspect bladder with abnormal increased opacity - mineralization or neoplasia (cannot rule out other cavitated mass), possibly enlarged spleen

Date of Previous IntraPet Ultrasound: 5/6/2020.

**SPECIES**

Canine

Sedation: Not required to complete full diagnostic ultrasound.

Stat Report: Not requested.

Imaging Performed By: Rachel Brillhart, RDMS.

**BREED**

Yorkshire Terrier

**ULTRASONOGRAPHIC EXAMINATION OF THE ABDOMEN****Urinary System****SEX**

Female, spayed

The urinary bladder is moderately distended. Air opacities are observed within the lumen. The dorsal wall appears to be irregular +/- thickened with possible hyperechoic to mineralized opacities along the mucosal surface. The visible portion of the proximal urethra is normal.

**AGE**

9/16/2010

The left kidney is normal size (5.38 cm in length) with a normal shape, smooth peripheral margins and normal internal architecture. There is mild to moderate loss of corticomedullary distinction. Pinpoint hyperechoic to mineralized foci are observed within the cortex. Several hyperechoic shadowing diverticular foci are observed. Moderate pyelectasia is present (0.43 cm in the longitudinal plane). There is no evidence of infarcts or hydronephrosis. Renal vasculature is normal.

**WEIGHT**

11.9 lbs.

The right kidney is normal in size (5.85 cm in length) with a normal shape, smooth peripheral margins and normal internal architecture. There is mild to moderate loss of corticomedullary distinction. Pinpoint hyperechoic to mineralized foci are observed within the cortex. Several hyperechoic shadowing diverticular foci are observed. Mild pyelectasia is present (0.33 cm in the longitudinal plane). There is no evidence of infarcts or hydronephrosis. Renal vasculature is normal.

**INTERPRETED BY**

Andrea Nicastro, DVM,  
 Diplomate ACVIM  
 (Small Animal Internal  
 Medicine)

**Adrenal Glands**

The left adrenal gland is enlarged (0.78 cm at cranial pole) (0.86 cm at caudal pole) (2.67 cm in length) with a slightly irregular shape. The parenchyma is hypoechoic with loss of glandular detail. No focal lesions are observed. The phrenicoabdominal vein and surrounding vasculature are normal.

**HOSPITAL NAME**

Eastern AH

The right adrenal gland is enlarged (0.92 cm at cranial pole) (0.88 cm at caudal pole) (1.89 cm in length) with a slightly irregular shape. The parenchyma is hypoechoic with loss of glandular detail. No focal lesions are observed. The phrenicoabdominal vein and surrounding vasculature are normal.

**REFERRING VET**

Dr. Cusack

**Spleen**

The spleen is subjectively normal in size (1.05 cm in width at the level of the hilus) with normal curvilinear peripheral contours. The parenchyma is of appropriate echogenicity and echotexture. Small hyperechoic to mineralized foci are observed throughout the organ. Splenic vasculature is normal with no evidence of thrombosis.

**INVOICE**

13285

**Liver**

The liver is subjectively prominent in size with swollen curvilinear peripheral contours. The parenchyma is isoechoic relative to the spleen and exhibits mild heterogeneity. No distinct focal lesions are observed. Hepatic vasculature and biliary tracts are of normal volume with no evidence of congestion. The gall bladder lumen is distended. The wall is thin and smooth. A large amount of aggregated, echogenic

suspended debris/sludge is observed within the lumen. The cystic and common bile ducts are normal/not seen.

### ***Gastrointestinal***

The stomach and intestine are free of stasis and exhibit normal peristaltic activity. The gastric lumen is mildly to moderately distended with ingesta. The gastric wall and pylorus are normal in thickness with a normal layering pattern. The pyloric outflow tract is patent. The small intestinal lumen is not dilated. The small intestinal wall thickness is normal with a normal layering pattern and appropriate mural detail. Discreet masses are not identified. The colonic wall is normal. No obstructive disease is noted.

### ***Pancreas***

A portion of the pancreas is obscured by the gastric distention. In the visualized portion of the right limb, the pancreas is visible/prominent with minimal deviation from the normal peripheral contours. The parenchyma is hyperechoic relative to surrounding omental fat and mottled in appearance. No distinct focal lesions are observed. The pancreatic duct is not overtly dilated.

### ***Free Abdomen***

The peritoneal cavity is normal. There is no evidence of inflammation or effusion. The abdominal lymph nodes are normal/not visible.

## **ULTRASONOGRAPHIC FINDINGS**

### **Primary Findings:**

- The urinary bladder wall changes are consistent with emphysematous cystitis with possible mineralizations along the dorsal wall or within the lumen.

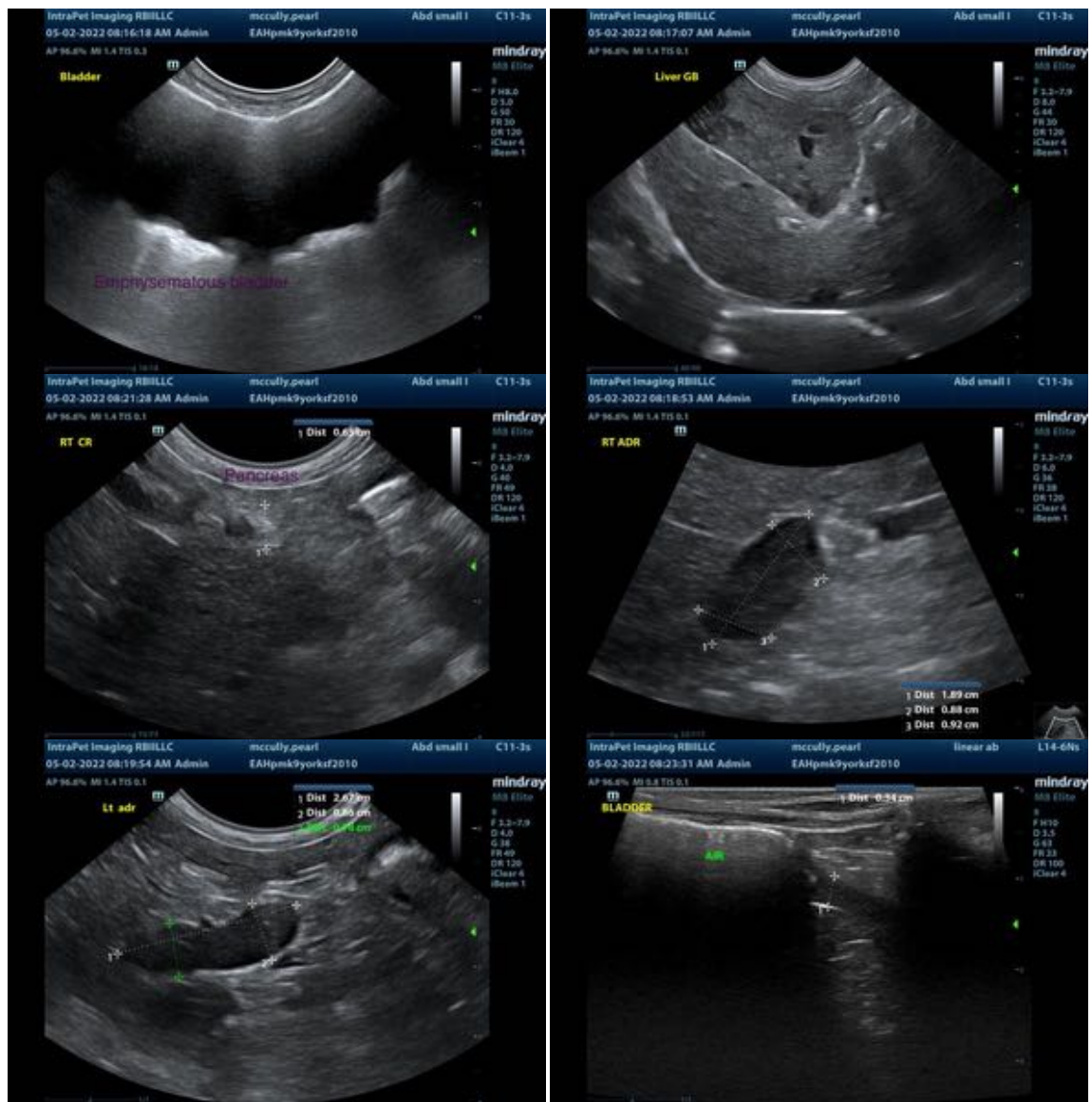
### **Secondary Findings:**

- Bilateral, chronic age-related renal changes with dystrophic mineralization and pyelectasia.
- Mild bilateral adrenomegaly. Changes are similar to the previous sonogram.
- The splenic changes are consistent with dystrophic mineralization. This finding is common with endocrinopathies.
- The diffuse hepatic changes are non-specific and could be consistent with vacuolar hepatopathy, regenerative nodular hyperplasia, and/or age-related remodeling. Inflammatory and infiltrative disease are considered less likely.
- Gallbladder debris/sludge could be consistent with cholestasis, early mucocele or less likely, fasting.
- The pancreatic changes are most consistent with age-related parenchymal remodeling, potentially secondary to a prior inflammatory episode, early fibrosis or chronic pancreatitis.

## **INTERPRETATION OF THE FINDINGS & FURTHER RECOMMENDATIONS**

- A urine culture and sensitivity is recommended. Once the urinary tract infection has cleared, consider a repeat ultrasound to assess for the presence of cystic calculi, which are difficult to observed due to gas artifact within the urinary bladder lumen.

- Consider testing for hyperadrenocorticism with a low-dose dexamethasone suppression test or ACTH stimulation test if clinical signs (i.e., PU/PD) develop in the future.
- Regarding the gall bladder sludge, consider initiation of Ursodiol or repeating an ultrasound in 4 weeks, preferably 2 hours after a small meal. If changes are similar to today's sonogram, Ursodiol can be considered at that time.



The information and recommendations provided are based on the images presented by the referring veterinarian. No evaluation can be communicated regarding pathology that was not visible in the image/video clips provided.

Thank you for this referral. If the clinical or image interpretation does not parallel your findings or if I can be

of any further assistance please contact me.

Andrea Nicastro, DVM, Diplomate ACVIM (*Small Animal Internal Medicine*)  
Andrea.nicastro@sonopath.com