

PATIENT PRESENTING CLINICAL SIGNS

PATIENT Ellie Brown
SPECIES Canine
BREED Labrador retriever
SEX Female, spayed

History: sedated with butorphanol and dexdormitor- P had a negative reaction to butorphanol; panting, hyperthermia, vocalizing- returned a few hours later after P received an IVC and gave full dose of propofol- P still panting heavily and challenging to scan-resistant to sedation- 26343 Ellie Brown Canine Labrador Retriever Spayed Female 4.1 62.2 lb Medication Strength Dosing Instructions Last given Glucosamine Fish Oil Procedure: AUS, lab work (Total Body Function) Current Problem List: Chronic pu/pd: DDx CDI, NDI, PPD, Pituitary disease, Adrenal disease, renal disease Presenting Complaint: Px presented for first examination with me on 4/21/22. Owner reports that px has been pu/pd for several years no cause identified with pDVM. pDVM records show several UAs going back to 2018, on initial UA there was bacteria, does not appear that cultures were ever performed. Chem/CBC WNL. Last UA showed USG 1.004 (7/2020) with pDVM Performed UA+UMIC on 4/21/22 - negative for infection. USG 1.003 When performing U/S guided cystocentesis for urine sample, noted that urinary bladder seemed to be located very far cranially and possibly a structure located caudal to the urinary bladder Pertinent Diagnostic Results: 4/21/22 UA+UMIC USG 1.003 pH 7.5 UMIC - negative

AGE ULTRASONOGRAPHIC EXAMINATION OF THE ABDOMEN

4.1 Years *Urinary System*

WEIGHT 62.2 Pounds

The urinary bladder, trigone, and pelvic urethra are normal in thickness and the mucosal surface is smooth. The bladder lumen is distended with anechoic urine. No masses, inflammatory changes or calculi are observed. Ureteral papillae and visualized portion of the proximal urethra, visible to a depth of 2 cm, are normal.

INTERPRETED BY

Andrea Nicastro, DVM,
Diplomate ACVIM
(Small Animal Internal
Medicine)

The left kidney is normal size (6.94 cm in length); normal shape and architecture with smooth peripheral margins. There is a normal 1:3 cortex to medulla ratio with normal corticomedullary distinction. There is no evidence of pyelectasia, nephroliths, infarcts or hydroureter.

The right kidney is normal size (5.97 cm in length); normal shape and architecture with smooth peripheral margins. There is a normal 1:3 cortex to medulla ratio with normal corticomedullary distinction. There is no evidence of pyelectasia, nephroliths, infarcts or hydroureter.

IMAGING PERFORMED BY

Loetitia Saint-Jacques, RVT

Adrenal Glands

The left adrenal gland is normal size (0.36 cm at cranial pole) (0.49 cm at caudal pole)(2.23 cm in length); normal shape; homogenous parenchyma. The glandular echogenicity and detail are unremarkable. Capsule, cortex, and medullary definition are normal. The phrenicoabdominal vein and surrounding vasculature are normal.

HOSPITAL NAME

Truckee meadows VH

The right adrenal gland is normal size (0.91 cm at cranial pole) (0.63 cm at caudal pole) (2.46 cm in length); normal shape; homogenous parenchyma. The glandular echogenicity and detail are unremarkable. Capsule, cortex, and medullary definition are normal. The phrenicoabdominal vein and surrounding vasculature are normal.

REFERRING VET

Dr. Rachel K

Spleen

INVOICE

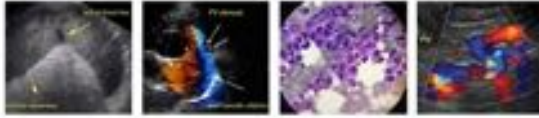
13301

The spleen is normal in size (1.87 cm in width at the level of the hilus) with a normal capsular contour. There is appropriate echogenicity and echotexture. No focal lesions are observed. Splenic vasculature is normal.

DATE

5/2/2022

Liver



PATIENT

Ellie Brown

The liver is subjectively normal in size with normal contours and structure. There is appropriate echogenicity and echotexture. No overt structural evidence of inflammatory, infiltrative or regenerative pathology is evident. Vascular and biliary tracts are of normal volume with no evidence of congestion. No pathological hepatic lymphadenopathy observed. The gall bladder lumen is moderately distended. The wall is thin and smooth. Luminal contents are anechoic. The cystic and common bile ducts are normal/not seen.

SPECIES

Canine

Gastrointestinal

BREED

Labrador retriever

The gastric lumen is not distended. The gastric wall is normal in thickness with a normal layering pattern. The small intestinal lumen is not dilated. The small intestinal wall thickness is normal with a normal layering pattern and appropriate mural detail. Discreet masses are not identified. The colonic wall is normal. No obstructive disease is noted.

SEX

Female, spayed

Pancreas

The region of the pancreas is isoechoic relative to surrounding omental fat. No obvious parenchymal abnormalities are observed. There is no evidence of regional inflammation or effusion.

AGE

4.1 Years

Free Abdomen

The peritoneal cavity is normal. There is no evidence of inflammation or effusion. A 1.74 cm sublumbar lymph node is visualized. The node is normal in shape and echogenicity. A few prominent mesenteric lymph nodes are also seen, the largest measuring 1.00 cm in length.

WEIGHT

62.2 Pounds

ULTRASONOGRAPHIC FINDINGS

INTERPRETED BY

Andrea Nicastro, DVM,
Diplomate ACVIM
(*Small Animal Internal
Medicine*)

- The lymph node changes are most consistent with reactive lymphadenitis or lymphoid hyperplasia.

IMAGING PERFORMED BY

Loetitia Saint-Jacques, RVT

*An obvious cause for the patient's PU/PD is not identified in this study. Considerations include underlying metabolic issue (i.e., occult hepatic dysfunction, hypoadrenocorticism), urinary tract infection (less likely given the negative urine culture), Leptospirosis (less likely given the chronicity of PU/PD), psychogenic polydipsia, diabetes insipidus (central or nephrogenic), other. Given the patient's age and normal ALP, Cushing's disease is considered extremely unlikely.

HOSPITAL NAME

Truckee meadows VH

INTERPRETATION OF THE FINDINGS & FURTHER RECOMMENDATIONS

REFERRING VET

Dr. Rachel K

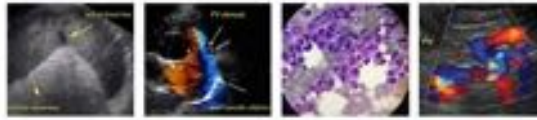
- Baseline lab work (CBC, chemistry panel and T4) is recommended, if not already performed.
- Consider pre- and post-prandial serum bile acids to assess for occult hepatic dysfunction.
- Leptospirosis testing can also be considered. However, given the chronicity of the PU/PD, this differential is considered less likely, and testing may be of low yield
- Consider a resting cortisol level to screen for hypoadrenocorticism.
- If the above diagnostics are inconclusive, consider a DDAVP trial to assess for central diabetes insipidus. If results are normal, a modified water deprivation test may be warranted to evaluate for psychogenic polydipsia and nephrogenic diabetes insipidus.

INVOICE

13301

DATE

5/2/2022



PATIENT

Ellie Brown

SPECIES

Canine

BREED

Labrador retriever

SEX

Female, spayed

AGE

4.1 Years

WEIGHT

62.2 Pounds

INTERPRETED BY

Andrea Nicastro, DVM,
Diplomate ACVIM
(Small Animal
Medicine)

IMAGING PERFORMED BY

Loetitia Saint-Jacques, RVT

HOSPITAL NAME

Truckee meadows VH

REFERRING VET

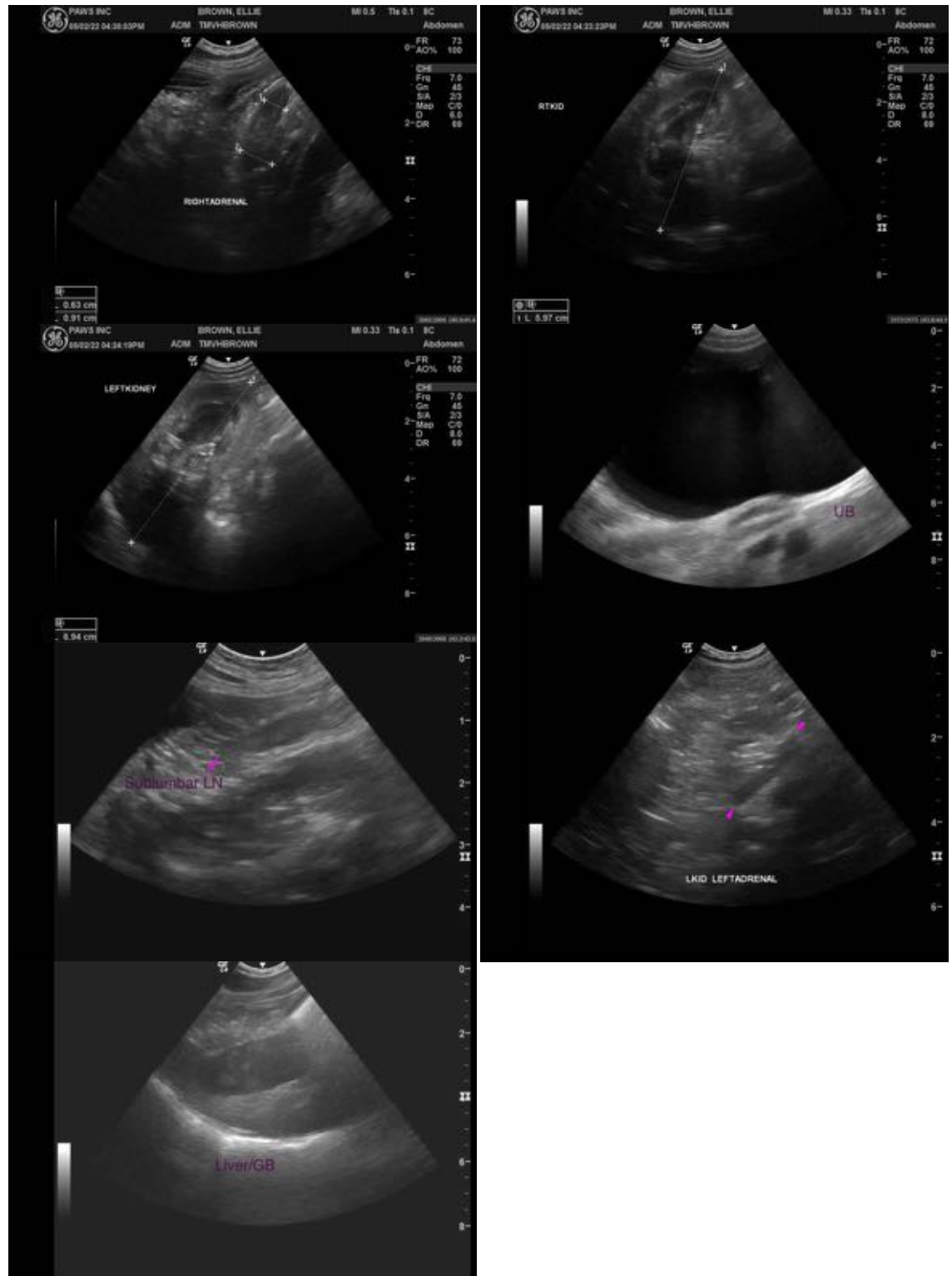
Dr. Rachel K

INVOICE

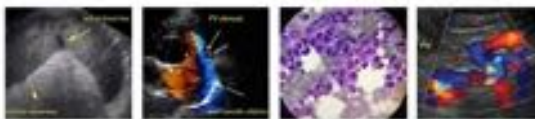
13301

DATE

5/2/2022



The information and recommendations provided are based on the images presented by the referring veterinarian/sonographer. No evaluation can be communicated regarding pathology that was not visible



PATIENT in the image/video clips provided.

Ellie Brown Thank you for this referral. If the clinical or image interpretation does not parallel your findings or if I can be of any further assistance, please contact me.

SPECIES Andrea Nicastro, DVM, Diplomate ACVIM (*Small Animal Internal Medicine*)

Canine andrea.nicastro@sonopath.com

BREED

Labrador retriever

SEX

Female, spayed

AGE

4.1 Years

WEIGHT

62.2 Pounds

INTERPRETED BY

Andrea Nicastro, DVM,
Diplomate ACVIM
(*Small Animal Internal
Medicine*)

**IMAGING PERFORMED
BY**

Loetitia Saint-Jacques, RVT

HOSPITAL NAME

Truckee meadows VH

REFERRING VET

Dr. Rachel K

INVOICE

13301

DATE

5/2/2022