

**DATE PRESENTING CLINICAL SIGNS**

5/2/22

P presented for a dental cleaning 4/28/22. ALP was elevated so the dental was postponed, and bile acids testing was performed. The post prandial bile acid was elevated so an abdominal ultrasound was recommended.

PATIENT

Bridy El Din

Current Medications: None.

Lab Results: Neutrophilia 14,570 (3000-12,000), ALP 551 (20-150), Glucose 124 (60-110).

Pre- bile acids were 8, post was 26.1.

Date of Previous IntraPet Ultrasound: No previous.

Sedation: Not required to complete full diagnostic ultrasound.

Stat Report: Not requested.

SPECIES

Canine

BREED

Maltipoo

Imaging Performed By: Andi Parkinson, RDMS.

ULTRASONOGRAPHIC EXAMINATION OF THE ABDOMEN**SEX**

Female, spayed

Urinary System

The urinary bladder is moderately distended. The wall is normal in thickness with a smooth mucosal surface. At least one tiny cystic calculus is observed. The region of the trigone is normal.

AGE

8/7/2010

The left kidney is normal size (4.29 cm in length); normal shape and architecture with smooth peripheral margins. There is a normal 1:3 cortex to medulla ratio with moderate loss of corticomedullary distinction. There is no evidence of pyelectasia, nephroliths, infarcts or hydroureter.

WEIGHT

14 lbs.

The right kidney is normal size (4.52 cm in length); normal shape and architecture with smooth peripheral margins. There is a normal 1:3 cortex to medulla ratio with moderate loss of corticomedullary distinction. There is no evidence of pyelectasia, nephroliths, infarcts or hydroureter.

INTERPRETED BY

Andrea Nicastro, DVM,
Diplomate ACVIM
(*Small Animal Internal
Medicine*)

Adrenal Glands

The left adrenal gland is normal size (0.43 cm at cranial pole) (0.52 cm at caudal pole) (1.76 cm in length); normal shape; homogenous parenchyma. The glandular echogenicity and detail are unremarkable. Capsule, cortex, and medullary definition are normal. The phrenicoabdominal vein and surrounding vasculature are normal.

HOSPITAL NAME

Charm City VH

The right adrenal gland is normal size (0.42 cm at cranial pole) (0.42 cm at caudal pole) (1.79 cm in length); normal shape; homogenous parenchyma. The glandular echogenicity and detail are unremarkable. Capsule, cortex, and medullary definition are normal. The phrenicoabdominal vein and surrounding vasculature are normal.

REFERRING VET

Dr. Eavers

Spleen

The spleen is normal in size (1.08 cm in width at the level of the hilus) with a normal capsular contour. There is appropriate echogenicity and echotexture. No focal lesions are observed. Splenic vasculature is normal.

INVOICE

13303

Liver

The liver is subjectively normal in size with normal curvilinear peripheral contours. The parenchyma is isoechoic relative to the spleen and exhibits mild heterogeneity. No distinct focal lesions are observed. Hepatic vasculature and biliary tracts are of normal volume with no evidence of congestion. The portal vein: caudal vena cava ratio is approximately 1:1. The gall bladder lumen is moderately distended. The wall is thin and smooth. A small to moderate amount of aggregated echogenic stranding debris/sludge is observed within the lumen. The cystic and common bile ducts are normal/not seen.

Gastrointestinal

The gastric lumen is not distended. The gastric wall is normal in thickness with a normal layering pattern. The small intestinal lumen is segmentally dilated with chyme. The small intestinal wall thickness is normal with a normal layering pattern and appropriate mural detail. Discreet masses are not identified. The colonic wall is normal. No obstructive disease is noted.

Pancreas

The right limb of the pancreas is visible with normal curvilinear peripheral contours. The parenchyma is largely isoechoic relative to surrounding omental fat and slightly mottled in appearance. The pancreatic duct is visible but not overtly dilated. There is no evidence of peripancreatic inflammation or effusion.

Free Abdomen

The peritoneal cavity is normal. There is no evidence of inflammation or effusion. The abdominal lymph nodes are normal/not visible.

ULTRASONOGRAPHIC FINDINGS

Primary Findings:

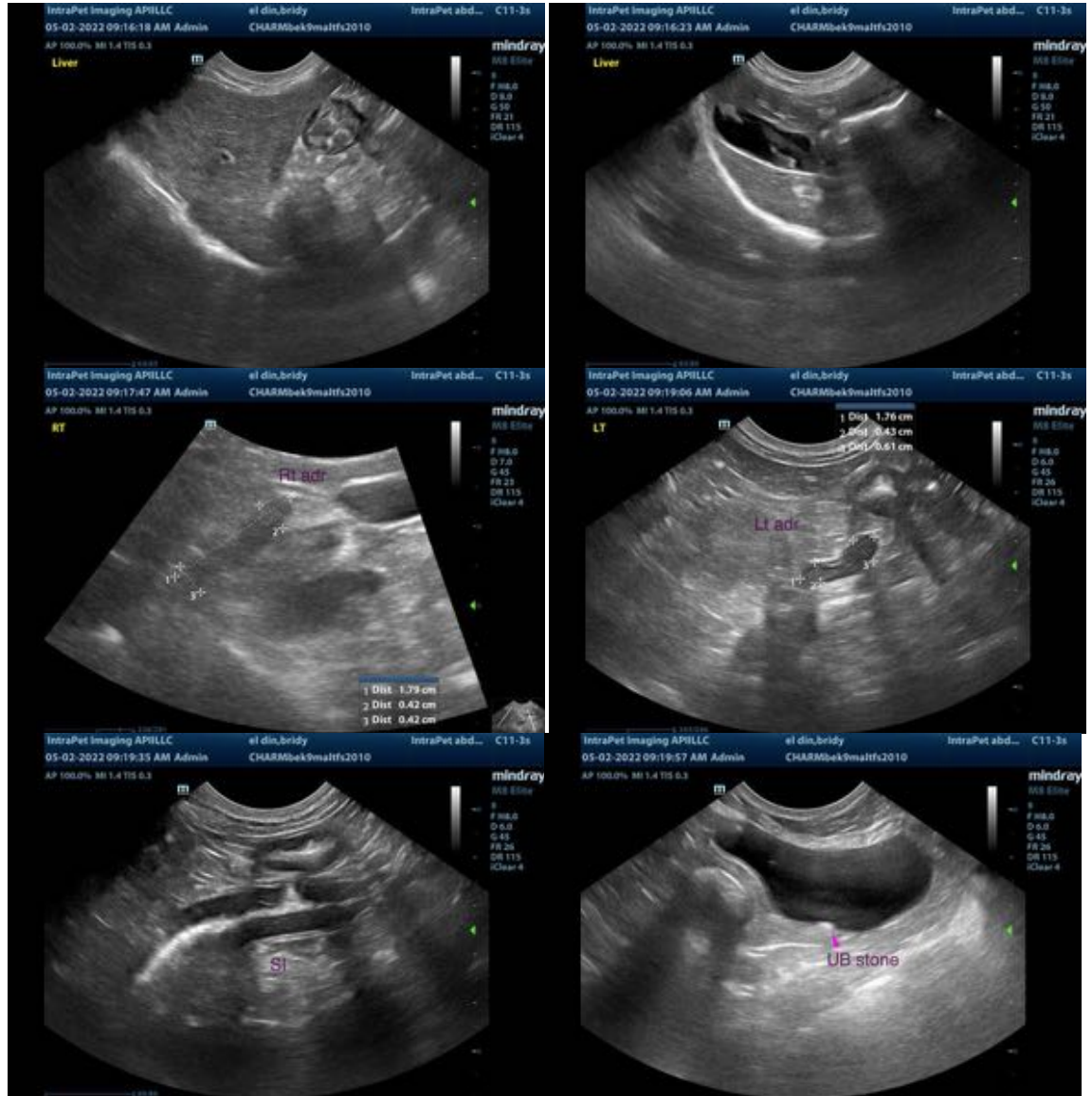
- The diffuse hepatic changes are non-specific and could be consistent with vacuolar hepatopathy, regenerative nodular hyperplasia, and/or age-related remodeling. Inflammatory and infiltrative disease are considered less likely.
- Gallbladder debris, non-mucocele.
- Tiny cystic calculus/calculi.

Secondary Findings:

- Age-related pancreatic remodeling +/- fibrosis. Mild chronic pancreatitis is also a possibility, particularly if the patient exhibits a positive Murphy's sign.
- Bilateral chronic age-related renal changes.

INTERPRETATION OF THE FINDINGS & FURTHER RECOMMENDATIONS

- If an aggressive approach is desired, hepatic tissue sampling (i.e., fine needle aspirate or surgical biopsy) can be considered. Surgical biopsies are preferred in that they are more likely to provide a definitive diagnosis. If pursued, extra tissue samples for copper quantitation as well as aerobic and anaerobic bile cultures are recommended.
- If a more conservative approach is desired, serial monitoring (i.e., every 3-4 months) of the patient's liver values is recommended. If values continue to increase, a repeat abdominal ultrasound +/- hepatic tissue sampling may be warranted.
- Regarding the urinary bladder stones, if they are causing clinical signs, consider surgical removal with submission for analysis and culture or an attempt at medical dissolution. If the patient is not exhibiting clinical signs, consider a recheck ultrasound in 1-2 months to see if they have passed or if they have increased in size/number.



The information and recommendations provided are based on the images presented by the referring veterinarian. No evaluation can be communicated regarding pathology that was not visible in the image/video clips provided.

Thank you for this referral. If the clinical or image interpretation does not parallel your findings or if I can be of any further assistance please contact me.

Andrea Nicastro, DVM, Diplomate ACVIM (*Small Animal Internal Medicine*)
 Andrea.nicastro@sonopath.com