

**PATIENT PRESENTING CLINICAL SIGNS**

**Buddy Dinunzio** History: FUO, low neutrophil count 192, temp 100.7 degrees today. Current meds: Doxycycline and Carprofen injection.  
Abnormal PE/Chem/CBC/UA Results: Neutrophils 192, ALP 241. Phos. 2.2, glucose 50, magnesium 1.3, sodium 137, T4 <0.5, WBC 2.4, PLTs 65. No U/A.

**SPECIES**

Canine

**ULTRASONOGRAPHIC EXAMINATION OF THE ABDOMEN**

**BREED**

**Urinary System**

Mixed

The urinary bladder, trigone, and pelvic urethra are normal in thickness and the mucosal surface is smooth. The bladder lumen is moderately distended with anechoic urine. No masses, inflammatory changes or calculi are observed. Ureteral papillae and visualized portion of the proximal urethra, visible to a depth of 2 cm, are normal.

**SEX**

Neutered Male

The prostate is normal in size (1.34 cm in length) (0.83 cm in width) and shape. Parenchyma is homogenous. The prostatic urethra appears normal without evidence of dilation or obstruction.

**AGE**

6 years

The left kidney is normal size (4.69 cm in length); normal shape and architecture with smooth peripheral margins. There is a normal 1:3 cortex to medulla ratio with normal corticomedullary distinction. There is no evidence of pyelectasia, nephroliths, infarcts or hydroureter. Renal vasculature is normal.

**WEIGHT**

23 lbs

The right kidney is normal size (5.09 cm in length); normal shape and architecture with smooth peripheral margins. There is a normal 1:3 cortex to medulla ratio with normal corticomedullary distinction. There is no evidence of pyelectasia, nephroliths, infarcts or hydroureter. Renal vasculature is normal.

**INTERPRETED BY**

Andrea Nicastro,  
DVM, Diplomate  
ACVIM (*Small Animal  
Internal Medicine*)

**Adrenal Glands**

The left adrenal gland is normal size (0.43 cm at cranial pole) (0.43 cm at caudal pole) (1.78 cm in length); normal shape; homogenous parenchyma. The glandular echogenicity and detail are unremarkable. Capsule, cortex, and medullary definition are normal. The phrenicoabdominal vein and surrounding vasculature are normal.

**IMAGING PERFORMED BY**

Kelly Vazquez

The right adrenal gland is normal size (0.73 cm at cranial pole) (0.54 cm at caudal pole) (1.84 cm in length); normal shape; homogenous parenchyma. The glandular echogenicity and detail are unremarkable. Capsule, cortex, and medullary definition are normal. The phrenicoabdominal vein and surrounding vasculature are normal.

**HOSPITAL NAME**

Berkely Heights

**Spleen**

The spleen is normal in size (1.30 cm in width at the level of the hilus) with a normal capsular contour. There is appropriate echogenicity and echotexture. No focal lesions are observed. Splenic vasculature is normal.

**REFERRING VET**

Dr. Seltzer

**Liver**

The liver is subjectively normal in size with normal contours and structure. There is appropriate echogenicity and echotexture. No overt structural evidence of inflammatory, infiltrative, or regenerative

**INVOICE**

10932

**DATE**

5/19/22

pathology is evident. Vascular and biliary tracts are of normal volume with no evidence of congestion. No pathological hepatic lymphadenopathy observed.

The gall bladder is of normal contours and contains some dependent echogenic debris. The wall is normal in thickness. No choleliths are observed. The cystic and common bile ducts are normal/not seen.

### ***Gastrointestinal***

A 1.29 cm shadowing structure is observed within the lumen, near the pyloric antrum. The apical area of gastric wall in the region of the fundus is mildly to moderately thickened (up to 0.64 cm) with retention of the normal layering pattern. The remaining gastric wall is normal in thickness with a normal layering pattern. The small intestinal lumen is focally and mildly dilated with chyme in one area. In this region, a small, shadowing structure is visualized. The remaining small intestinal lumen is not dilated. The small intestinal wall is normal in thickness with a normal layering pattern and appropriate mural detail. The ileocecolic junction and colonic wall are normal. There is no evidence of an obstructive pattern.

### ***Pancreas***

The region of the pancreas is isoechoic relative to surrounding omental fat. No obvious parenchymal abnormalities are observed. There is no evidence of regional inflammation or effusion.

### ***Free Abdomen***

The peritoneal cavity is normal. There is no evidence of inflammation or effusion. The abdominal lymph nodes are normal/not visible.

## **ULTRASONOGRAPHIC FINDINGS**

### **Primary Findings**

- Possible gastric foreign body (versus normal ingesta). The focal gastric wall thickening is most consistent with an inflammatory process. However, emerging neoplasia cannot be excluded.
- The shadowing material within the small intestine likely represents transient foreign material. There is no obvious evidence of obstruction at this time.

\*An obvious cause for the patient's fever and bicytopenia is not identified in this study. Considerations include underlying infection, inflammatory process, neoplasia, autoimmune disease, other.

## **INTERPRETATION OF THE FINDINGS & FURTHER RECOMMENDATIONS**

Further work-up could include the following:

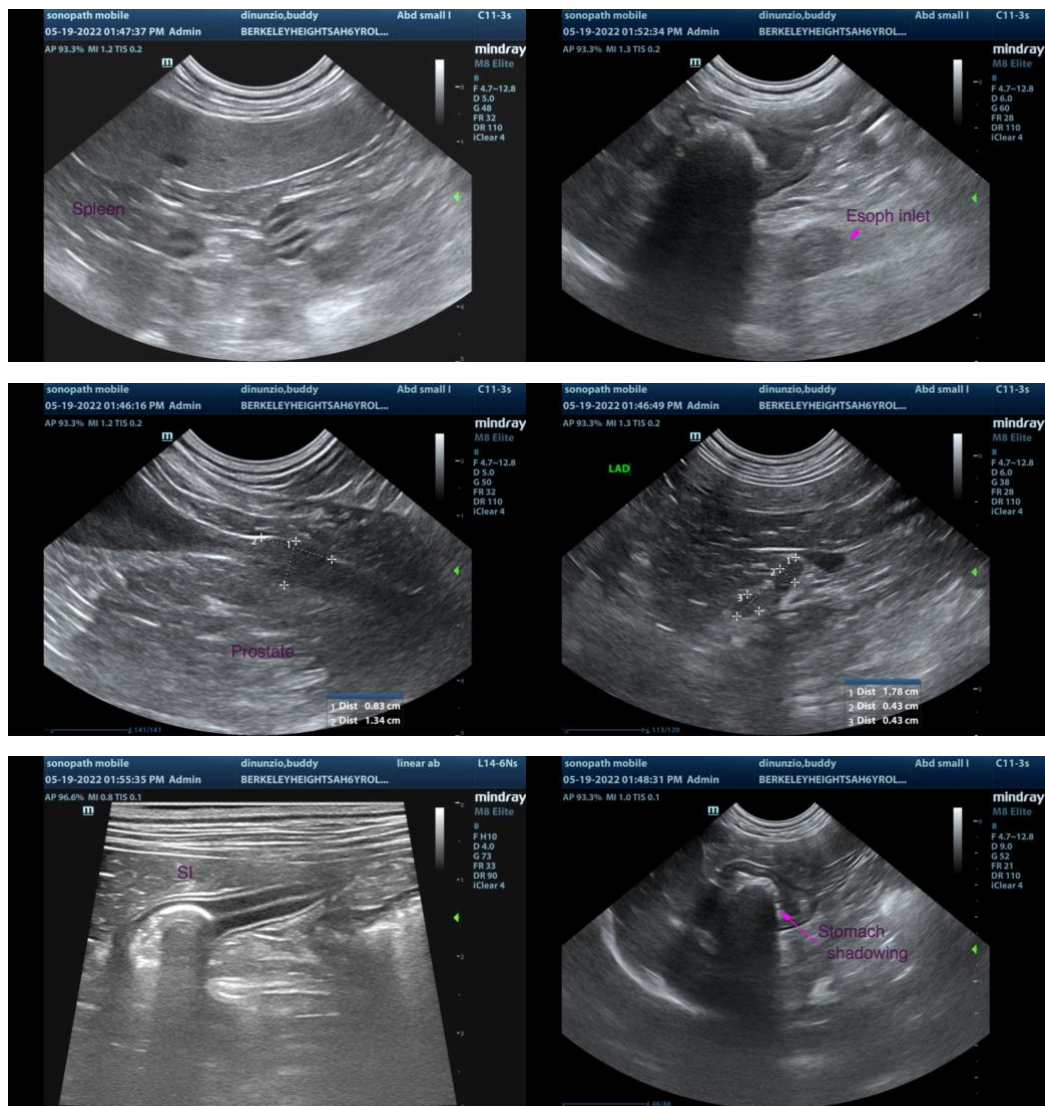
1. Urine culture and sensitivity
2. Three-view thoracic radiographs
3. Echocardiogram to assess for evidence of valvular endocarditis

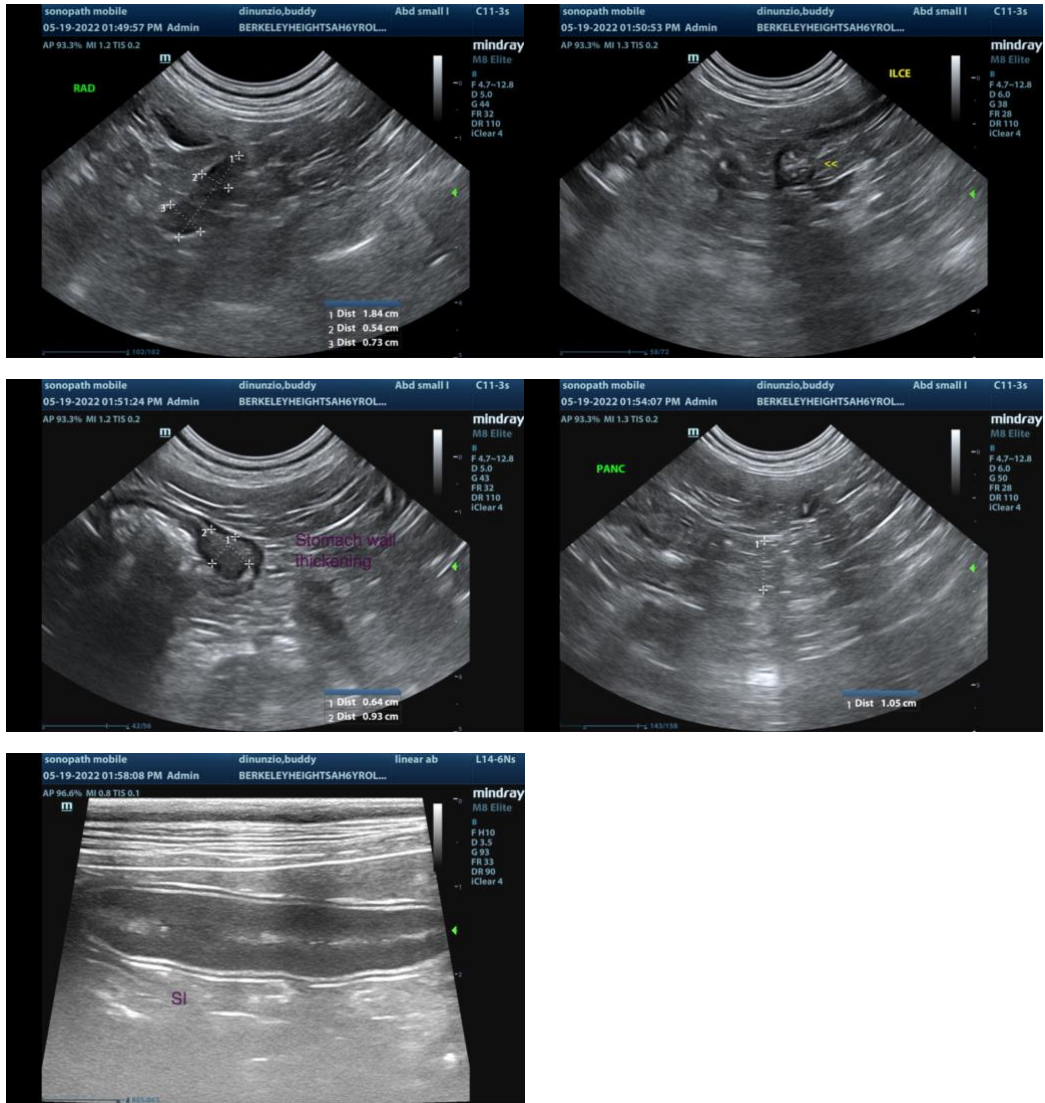
4. Comprehensive tick panel (Send to NC State)
5. +/- bone marrow aspirate
6. Thorough neurologic and orthopedic examinations.

Depending on the results of the above diagnostics, arthrocentesis with submission of joint fluid for cytologic evaluation and culture +/- a cerebral spinal fluid tap may be warranted. The platelet count should be stabilized prior to performing invasive procedures.

While awaiting test results a continuation of broad-spectrum antibiotics and supportive care is recommended.

Regarding the possible gastric foreign material, consider repeat abdominal imaging (i.e., radiographs or ultrasound) in 24-48 hours to determine if the shadowing structure has passed into the small intestine.





The information and recommendations provided are based on the images presented by the referring veterinarian/sonographer. No evaluation can be communicated regarding pathology that was not visible in the image/video clips provided.

Thank you for this referral. If the clinical or image interpretation does not parallel your findings or if I can be of any further assistance, please contact me.

**Andrea Nicastro, DVM, Diplomate DACVIM (Small Animal Internal Medicine)**  
[info@SonoPath.com](mailto:info@SonoPath.com)