



**PATIENT**

Arlo Paddison

**SPECIES**

Canine

**BREED**

Cavalier King Charles Spaniel

**SEX**

Neutered Male

**AGE**

4 years

**WEIGHT**

35 lbs

**INTERPRETED BY**

Andrea Nicastro, DVM,  
Diplomate ACVIM  
(Small Animal Internal  
Medicine)

**IMAGING  
PERFORMED BY**

Kelly Reschny

**HOSPITAL NAME**

Village Centre AH

**REFERRING VET**

Dr. Kunnath

**INVOICE**

10935

**DATE**

5/19/22

**PRESENTING CLINICAL SIGNS**

History: clinically healthy, elevated pancreatic indicator meds: pregabalin, prednisone  
Abnormal PE/Chem/CBC/UA Results: PSL 532(24-140), all other values WNI

**ULTRASONOGRAPHIC EXAMINATION OF THE ABDOMEN**

**Urinary System**

The urinary bladder, trigone, and pelvic urethra are normal in thickness and the mucosal surface is smooth. The bladder lumen is moderately distended with anechoic urine. No masses, inflammatory changes or calculi are observed. Ureteral papillae and visualized portion of the proximal urethra, visible to a depth of 2 cm, are normal.

The prostate is normal in size (0.82 cm in width) and shape. Parenchyma is homogenous. The prostatic urethra appears normal without evidence of dilation or obstruction.

The left kidney is normal size (5.71 cm in length); normal shape and architecture with smooth peripheral margins. There is a normal 1:3 cortex to medulla ratio with normal corticomedullary distinction. There is no evidence of pyelectasia, nephroliths, infarcts or hydronephrosis. Renal vasculature is normal.

The right kidney is normal size (5.67 cm in length); normal shape and architecture with smooth peripheral margins. There is a normal 1:3 cortex to medulla ratio with normal corticomedullary distinction. There is no evidence of pyelectasia, nephroliths, infarcts or hydronephrosis. Renal vasculature is normal.

**Adrenal Glands**

The left adrenal gland is normal size (0.48 cm at cranial pole) (3.70 cm at caudal pole) (1.95 cm in length); normal shape; homogenous parenchyma. The glandular echogenicity and detail are unremarkable. Capsule, cortex, and medullary definition are normal. The phrenicoabdominal vein and surrounding vasculature are normal.

The right adrenal gland is normal size (1.26 cm at cranial pole) (0.49 cm at caudal pole) (1.98 cm in length); normal shape; homogenous parenchyma. The glandular echogenicity and detail are unremarkable. Capsule, cortex, and medullary definition are normal. The phrenicoabdominal vein and surrounding vasculature are normal.

**Spleen**

The spleen is normal in size (1.85 cm in width at the level of the hilus) with a normal capsular contour. There is appropriate echogenicity and echotexture. No focal lesions are observed. Splenic vasculature is normal.

**Liver**

The liver is subjectively normal in size with normal contours and structure. There is appropriate echogenicity and echotexture. No overt structural evidence of inflammatory, infiltrative, or regenerative pathology is evident. Vascular and biliary tracts are of normal volume with no evidence of congestion. No pathological hepatic lymphadenopathy observed.



**PATIENT**

Arlo Paddison

The gall bladder lumen is moderately distended. The wall is thin and smooth. Luminal contents are anechoic. The cystic and common bile ducts are normal/not seen.

**SPECIES**

Canine

**Gastrointestinal**

The gastric lumen is not distended. The gastric wall is normal in thickness with a normal layering pattern. The small intestinal lumen is not dilated. The small intestinal wall thickness is normal with a normal layering pattern and appropriate mural detail. Discreet masses are not identified. The colonic wall is normal. The colonic lumen contains shadowing fecal material. There is no evidence of an obstructive pattern.

**BREED**

Cavalier King Charles Spaniel

**SEX**

Neutered Male

**Pancreas**

The region of the pancreas is isoechoic relative to surrounding omental fat. No obvious parenchymal abnormalities are observed. There is no evidence of regional inflammation or effusion.

**AGE**

4 years

**Free Abdomen**

The peritoneal cavity is normal. There is no evidence of inflammation or effusion. The abdominal lymph nodes are normal/not visible.

**WEIGHT**

35 lbs

**ULTRASONOGRAPHIC FINDINGS**

**Primary Findings**

- Unremarkable abdomen. An obvious cause for the elevated PSL is not identified in this study. Low-grade pancreatitis cannot be excluded but is not evident grossly. It should be noted that the PSL can be elevated with non-pancreatic diseases.

**INTERPRETED BY**

Andrea Nicastro, DVM,  
Diplomate ACVIM  
(Small Animal Internal  
Medicine)

**IMAGING PERFORMED BY**

Kelly Reschny

**INTERPRETATION OF THE FINDINGS & FURTHER RECOMMENDATIONS**

- Consider performing a cPLI (Send to Texas A&M) to better evaluate for pancreatitis.

**HOSPITAL NAME**

Village Centre AH

**REFERRING VET**

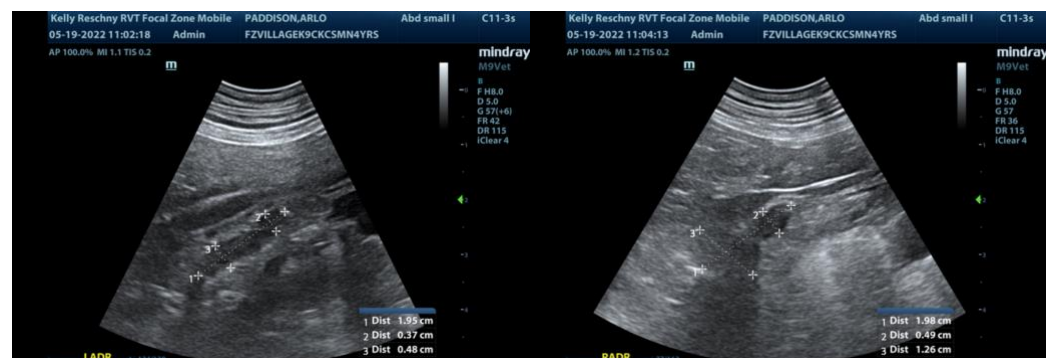Dr. Kunnath

**INVOICE**

10935

**DATE**

5/19/22





**PATIENT**

Arlo Paddison

**SPECIES**

Canine

**BREED**

Cavalier King Charles Spaniel

**SEX**

Neutered Male

**AGE**

4 years

**WEIGHT**

35 lbs

**INTERPRETED BY**

Andrea Nicastro, DVM,  
Diplomate ACVIM  
(Small Animal Internal  
Medicine)

**IMAGING  
PERFORMED BY**

Kelly Reschny

**HOSPITAL NAME**

Village Centre AH

**REFERRING VET**

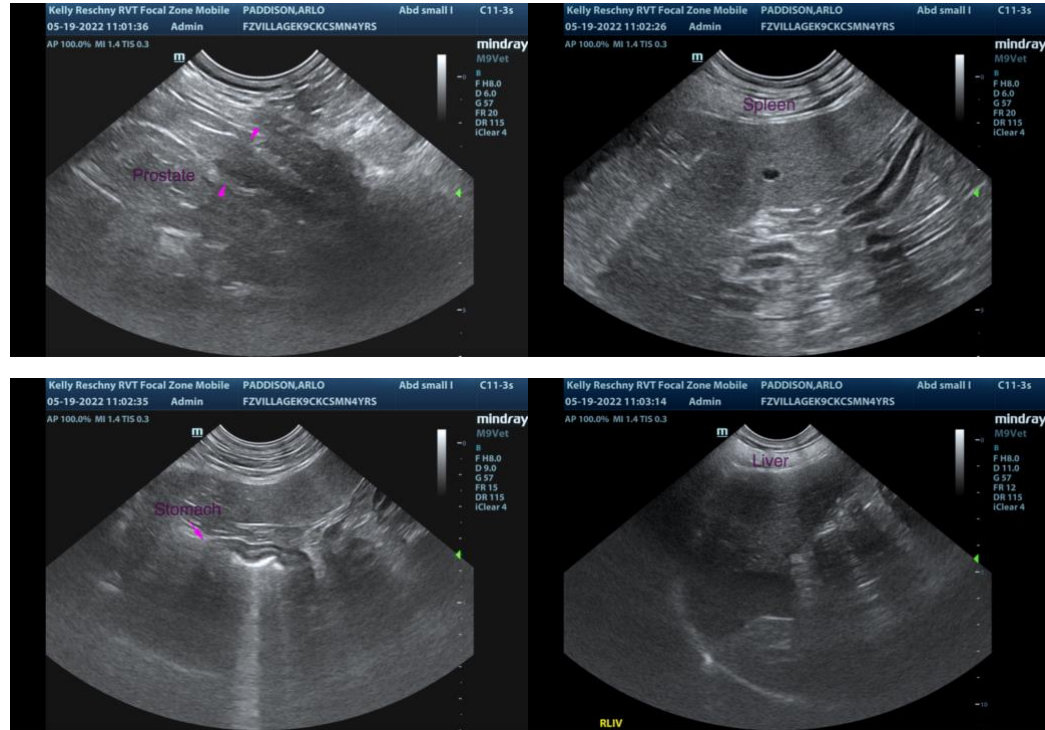
Dr. Kunnath

**INVOICE**

10935

**DATE**

5/19/22



The information and recommendations provided are based on the images presented by the referring veterinarian/sonographer. No evaluation can be communicated regarding pathology that was not visible in the image/video clips provided.

Thank you for this referral. If the clinical or image interpretation does not parallel your findings or if I can be of any further assistance, please contact me.

**Andrea Nicastro, DVM, Diplomate DACVIM (Small Animal Internal Medicine)**  
info@SonoPath.com