

PATIENT PRESENTING CLINICAL SIGNS

Andy Melampy

SPECIES

Canine

BREED

Sheltie

SEX

Neutered Male

AGE

7 years

WEIGHT

24.6 lbs

History: Presented 4/22/22 for annual exam where we performed annual CBC/Chem/UA/T4/4DX. Patient has continued to do amazing, no changes or increase in appetite, water intake, urinations. Currently on HSD metabolic + mobility. Bloodwork showed elevated ALP and protein in urine, other values WNL. Presented 5/16/22 for a recheck urine with UPC to lab and ALP. ALP crept up and UPC showed significant protein presented. Presented today for abdominal ultrasound. Continuing to do well at home and owner did not have any concerns.

Abnormal PE/Chem/CBC/UA Results: BP: 1) 154/93 (105) 2) 154/96 (114) 3) 158/98 (121) UPC (2.7) and ALP 545. Urine Specific Gravity 1.036. Inactive urine sediment.

ULTRASONOGRAPHIC EXAMINATION OF THE ABDOMEN

Urinary System

The urinary bladder, trigone, and pelvic urethra are normal in thickness and the mucosal surface is smooth. The bladder lumen is moderately distended with anechoic urine. No masses, inflammatory changes or calculi are observed. Ureteral papillae and visualized portion of the proximal urethra, visible to a depth of 2 cm, are normal.

The prostate is normal in size (1.05 cm in width) and shape. Parenchyma is homogenous. The prostatic urethra appears normal without evidence of dilation or obstruction.

INTERPRETED BY

Andrea Nicastro,
DVM, Diplomate
ACVIM (*Small Animal
Internal Medicine*)

The left kidney is normal size (4.75 cm in length); normal shape and architecture with smooth peripheral margins. There is a normal 1:3 cortex to medulla ratio with minimal to moderate loss of corticomedullary distinction. There is no evidence of pyelectasia, nephroliths, infarcts or hydroureter.

IMAGING PERFORMED BY

Dr. Jo Goodman

The right kidney is normal size (5.18 cm in length); normal shape and architecture with smooth peripheral margins. There is a normal 1:3 cortex to medulla ratio with minimal to moderate loss of corticomedullary distinction. There is no evidence of pyelectasia, nephroliths, infarcts or hydroureter.

HOSPITAL NAME

Evandale-Blue Ash PH

Adrenal Glands

The left adrenal gland is normal size (0.48 cm at cranial pole) (0.50 cm at caudal pole); normal shape; homogenous parenchyma. The glandular echogenicity and detail are unremarkable. Capsule, cortex, and medullary definition are normal. The phrenicoabdominal vein and surrounding vasculature are normal.

REFERRING VET

Dr. Jo Goodman

The right adrenal gland is normal size (1.66 cm at cranial pole) (0.60 cm at caudal pole) (2.14 cm in length); normal shape; homogenous parenchyma. The glandular echogenicity and detail are unremarkable. Capsule, cortex, and medullary definition are normal. The phrenicoabdominal vein and surrounding vasculature are normal.

INVOICE

10940

DATE

5/19/22

Spleen

The spleen is normal in size (1.28 cm in width at the level of the hilus) with a normal capsular contour. There is appropriate echogenicity and echotexture. No focal lesions are observed. Splenic vasculature is normal.

Liver

The liver is subjectively normal to slightly prominent in size with normal curvilinear peripheral contours. The parenchyma is hypoechoic relative to the spleen and homogenous in appearance. No distinct focal lesions are observed. Hepatic vasculature and intrahepatic biliary tracts are of normal volume with no evidence of congestion.

The gall bladder lumen is moderately distended. The wall is thin and smooth. A small/scant amount of gravity dependent, echogenic debris is observed within the lumen. The cystic and common bile ducts are normal/not seen.

Gastrointestinal

The stomach and intestine are free of stasis and exhibit normal peristaltic activity. The gastric lumen is not distended. The gastric wall and pylorus are normal in thickness with a normal layering pattern. The pyloric outflow tract is patent. The small intestinal lumen is not dilated. The small intestinal wall thickness is normal with a normal layering pattern and appropriate mural detail. Discreet masses are not identified. The colonic wall is normal. No obstructive disease is noted.

Pancreas

The region of the pancreas is isoechoic relative to surrounding omental fat. No obvious parenchymal abnormalities are observed. There is no evidence of regional inflammation or effusion.

Free Abdomen

The peritoneal cavity is normal. There is no evidence of inflammation or effusion. A 1.54 cm medial iliac lymph node is visualized. The node is normal in shape and echogenicity.

ULTRASONOGRAPHIC FINDINGS

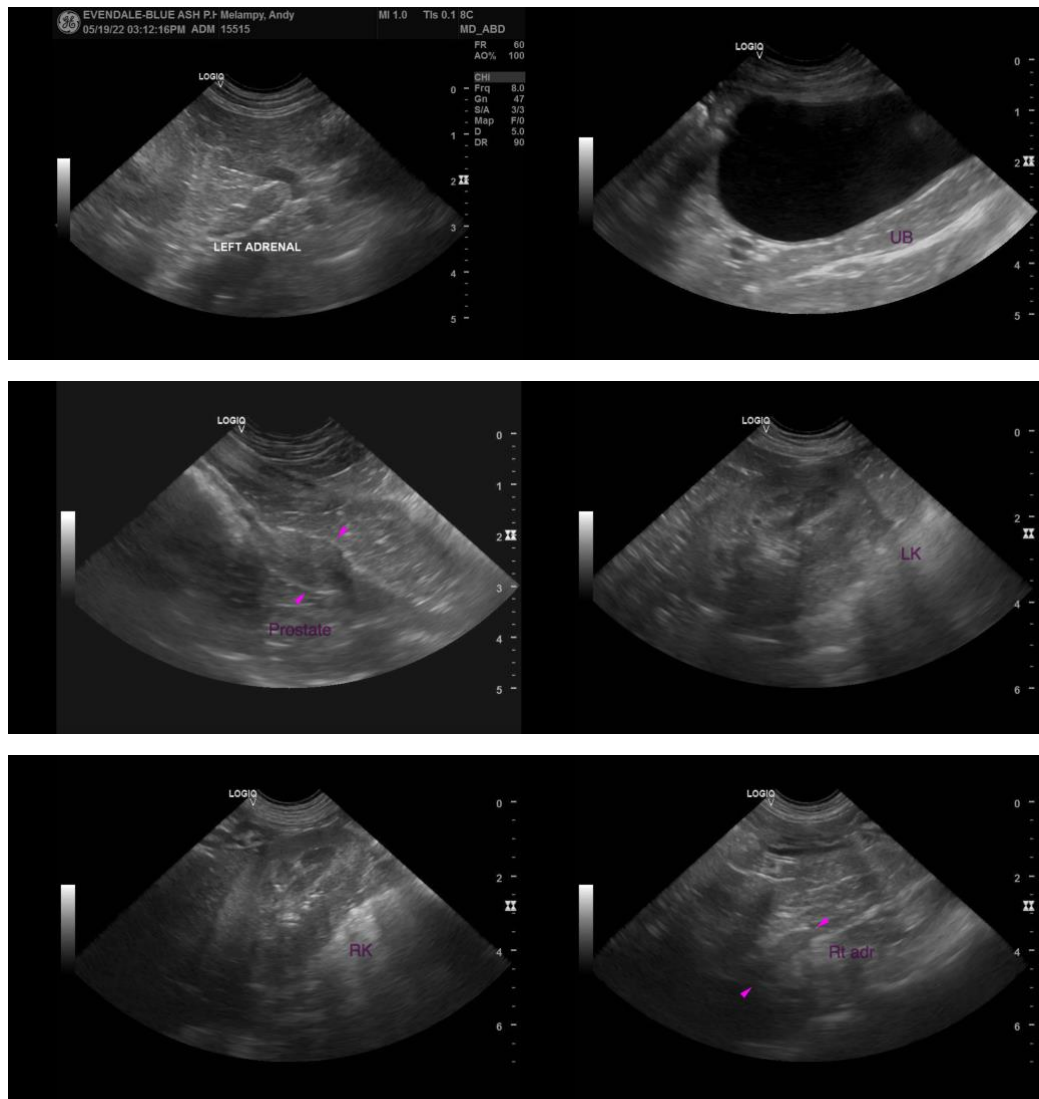
Primary Findings

- An obvious cause for the elevated ALP is not identified in this study. However, a benign hepatopathy (i.e., age-related remodeling, regenerative nodular hyperplasia, and/or a vacuolar hepatopathy) is suspected.
- Minor, bilateral, nonspecific, chronic renal changes. Given the elevated UPC, a protein-losing nephropathy (i.e., glomerulonephritis or less likely, amyloidosis) is suspected.

INTERPRETATION OF THE FINDINGS & FURTHER RECOMMENDATIONS

- Serial monitoring (i.e., every 3-4 months) of the patient's liver values is recommended. If values continue to increase, a repeat abdomen ultrasound +/- a more advanced hepatic work-up (i.e., tissue sampling) may be warranted.

- Given the suspected protein-losing nephropathy, the following can be considered:
 - Thoracic radiographs to assess for occult disease in the chest
 - Consider infectious disease testing (i.e., tick-borne, Leptospirosis), particularly if the clinical suspicion is high.
 - Angiotensin II receptor blocker (e.g., telmisartan)
 - Antithrombotic (e.g., clopidogrel at 2.5 mg/kg PO q 24 hours)
 - Omega-3 fatty acids (65 mg/kg of DHA and EPA combined daily)
 - Prescription renal diet
 - Baseline blood pressure measurement with serial monitoring thereafter
 - Routine monitoring of UPC and bloodwork (CBC, chemistry panel) to assess for progressive disease



The information and recommendations provided are based on the images presented by the referring veterinarian/sonographer. No evaluation can be communicated regarding pathology that was not visible in the image/video clips provided.

Thank you for this referral. If the clinical or image interpretation does not parallel your findings or if I can be of any further assistance, please contact me.

Andrea Nicastro, DVM, Diplomate DACVIM (Small Animal Internal Medicine)
info@SonoPath.com