


DATE PRESENTING CLINICAL SIGNS

5/18/26

Patient History: Suspected reoccurrence of mammary mass removed 9/2025 from left chain. Histopath previously declined. Hx of elevated liver values ALP > ALT. Firm 3 cm mass L mammary chain, cranial to previous incision

PATIENT

Lucy Fuentes

Current Medications: None at this time.

Labwork Results: Labwork not attached, reported as: 9/2025 ALP 1009, ALT 240 bilirubin 0.8. Repeat labwork pending. Thoracic radiographs clear of visible metastasis 9/2025. Updated radiographs pending

SPECIES

Feline

Date of Previous IntraPet Ultrasound: No previous.

Sedation: Not required to complete full diagnostic ultrasound.

Stat Report: Not requested.

BREED

Beagle mix

Imaging Performed by: Stephanie Warga RDCS, RVT.

ULTRASONOGRAPHIC EXAMINATION OF THE ABDOMEN
Urinary System

The urinary bladder wall is normal in thickness and the mucosal surface in the region of the apex is slightly irregular. The bladder is moderately distended. Luminal contents are anechoic. No cystic calculi are observed. The region of the trigone and the proximal urethra, visible to a depth of 2 cm, are normal.

SEX

Female, spayed

The left kidney is normal in size (5.52 cm in length) with a normal shape, architecture and smooth peripheral margins. There is a normal 1:3 cortex to medulla ratio with mild to moderate loss of corticomedullary distinction. There is no evidence of pyelectasia, nephroliths, infarcts or hydroureter. Renal vasculature is normal.

AGE

10/28/2014

The right kidney is normal in size (5.52 cm in length) with a normal shape, architecture and smooth peripheral margins. There is a normal 1:3 cortex to medulla ratio with normal corticomedullary distinction. There is no evidence of pyelectasia, nephroliths, infarcts or hydroureter. Renal vasculature is normal.

WEIGHT

17.8 kg.

INTERPRETED BY
Adrenal Glands

The left adrenal gland is mildly enlarged (0.66 cm at cranial pole) (0.98 cm at caudal pole) with slightly swollen peripheral contours. The glandular echogenicity and detail are unremarkable. The phrenicoabdominal vein and surrounding vasculature are normal.

The right adrenal gland is enlarged (1.26 cm at cranial pole) (1.01 cm at caudal pole) with swollen contours at the caudal aspect. The glandular echogenicity and detail are unremarkable. The phrenicoabdominal vein and surrounding vasculature are normal.

Andrea Nicastro, DVM,
Diplomate ACVIM
(Small Animal Internal
Medicine)

HOSPITAL NAME

Pleasantville AH

REFERRING VET

Dr. Gounaris

Spleen

The spleen is normal in size (1.44 cm in width at the level of the hilus) with a normal capsular contour. There is appropriate echogenicity and echotexture. Several meylolipomas are observed in the region of the hilus. Splenic vasculature is normal.

INVOICE

13728

Liver

The liver is normal to prominent in size with smooth peripheral contours. The parenchyma is isoechoic relative to the spleen and diffusely heterogeneous in appearance with a few ill-defined hypoechoic nodules, one of the nodules measuring 2.3 x 1.5 cm. At least one small hyperechoic nodule is also seen (1.89 x 1.32 cm). Vascular and biliary tracts are of normal volume with no evidence of congestion.

The gall bladder lumen is moderately distended. The wall is thin and smooth. A moderate to large amount of aggregated, echogenic, partially dependent sludge is observed within the lumen. The cystic and common bile ducts are normal/not seen.

Gastrointestinal

The gastric lumen is not distended. The gastric wall and pylorus are normal in thickness with a normal layering pattern. The pyloric outflow tract is patent. The small intestinal lumen is not dilated. The small intestinal wall is normal in thickness with a normal layering pattern and appropriate mural detail. Discreet masses are not identified. The colonic wall is normal. The colonic lumen contains shadowing fecal material. There is no obvious evidence of an obstructive pattern.

Pancreas

The right limb of the pancreas is visible with normal curvilinear peripheral contours. The parenchyma is largely isoechoic relative to surrounding omental fat and slightly mottled in appearance. The pancreatic duct is visible but not overtly dilated. There is no evidence of peripancreatic inflammation or effusion.

Lymph nodes

A 0.79 x 0.62 cm lymph node is observed at the aortic trifurcation. In addition, a 3.80 x 0.45 cm mesenteric lymph node is seen.

Free Abdomen

The peritoneal cavity is normal. There is no evidence of inflammation or effusion.

Other

A 3.6 x 2.2 cm heterogeneous subcutaneous mass is visualized.

ULTRASONOGRAPHIC FINDINGS

Primary Findings:

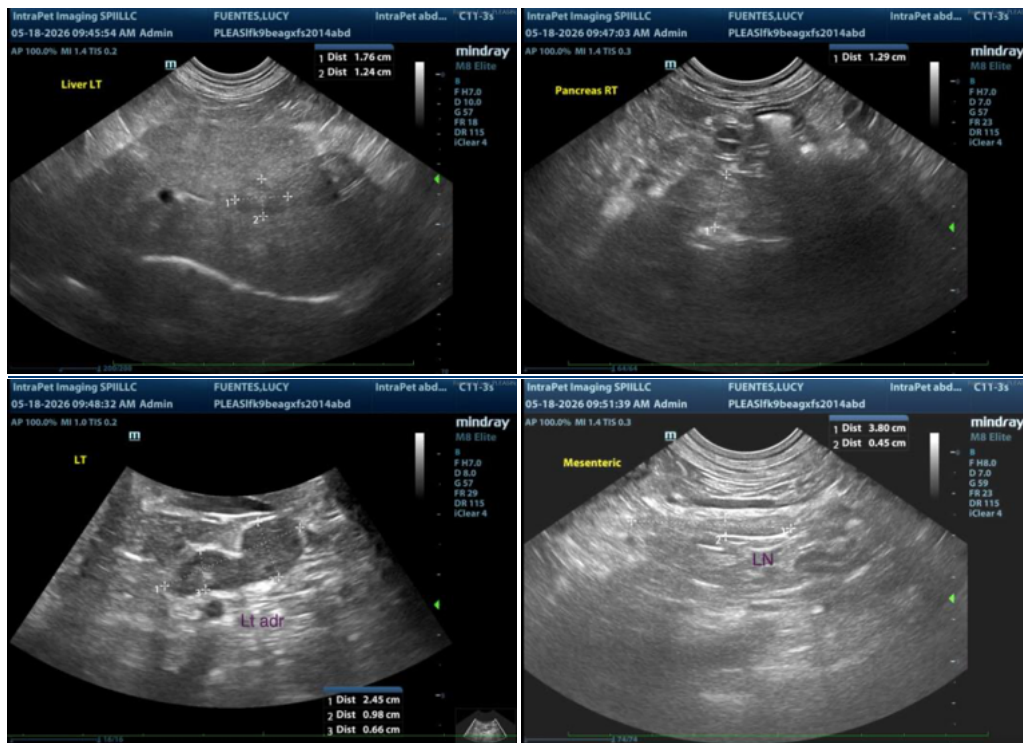
- The gallbladder changes are suggestive of a developing mucocele.
- The diffuse hepatic changes are non-specific and could be consistent with vacuolar hepatopathy, regenerative nodular hyperplasia, and/or age-related remodeling. Inflammatory disease, infiltrative neoplasia and other hepatopathies are considered less likely.
- Bilateral adrenomegaly
- Subcutaneous mass

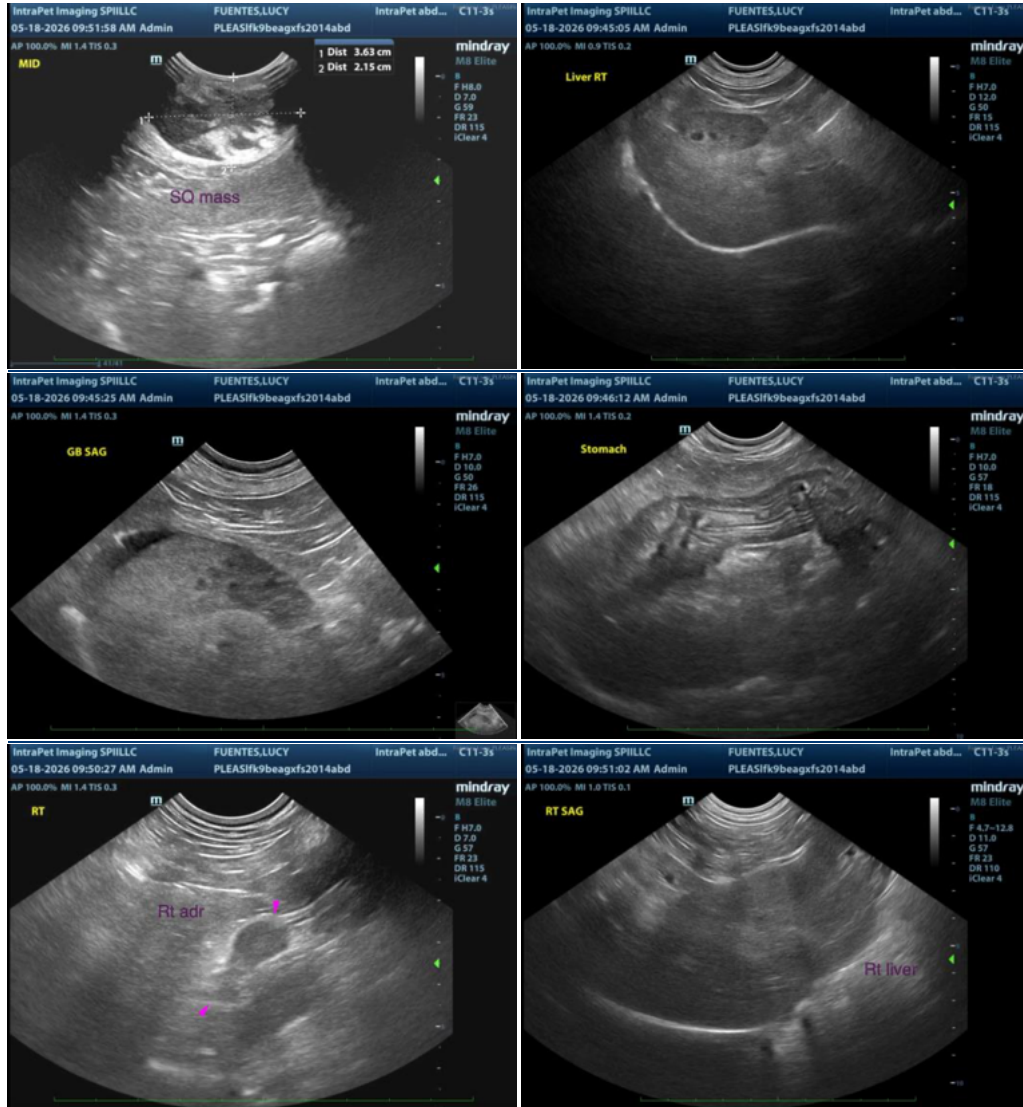
Secondary Findings:

- Bilateral nonspecific, age-related renal changes
- The pancreatic changes are most consistent with age-related parenchymal remodeling, potentially secondary to a prior inflammatory episode, early fibrosis or chronic pancreatitis.
- The prominent abdominal lymph nodes are most consistent with reactive lymphadenitis or lymphoid hyperplasia. Neoplastic infiltration is considered less likely.

INTERPRETATION OF THE FINDINGS & FURTHER RECOMMENDATIONS

- Regarding the elevated liver values, hepatic tissue sampling (i.e., aspirates or biopsies) can be considered (if clotting status is appropriate). Alternatively, if a more conservative approach is desired, consider serial monitoring (i.e., every 3-4 months) of the patient's liver values. If liver values continue to increase, a repeat abdominal ultrasound +/- hepatic tissue sampling may be warranted.
- Given the gall bladder changes, Ursodeoxycholic acid (Ursodiol) is recommended. Serial sonographic monitoring (e.g., every 6-8 weeks) of the gall bladder is recommended to assess for progression to a fully formed mucocele. If progression occurs, a cholecystectomy may be warranted.
- Consider testing for hyperadrenocorticism with a low-dose dexamethasone suppression test or ACTH stimulation test if clinical signs (i.e., PU/PD) develop in the future.
- Regarding the subcutaneous mass, consider the following:
 1. Three-view thoracic radiographs are recommended to assess for pulmonary metastases.
 2. Fine needle aspiration of the mass or excisional biopsy





The information and recommendations provided are based on the images presented by the referring veterinarian/sonographer. No evaluation can be communicated regarding pathology that was not visible in the image/video clips provided.

Thank you for this referral. If the clinical or image interpretation does not parallel your findings or if I can be of any further assistance please contact me.

Andrea Nicastro, MPH, DVM, Diplomate DACVIM (Small Animal Internal Medicine) info@SonoPath.com