



**DATE PRESENTING CLINICAL SIGNS**

5/18/26

**Patient History:** Presented for chronic diarrhea. At presentation, was bright, alert, and responsive. Has been recently developed hematochezia and stools have remain unresolved over the last ~1-2 weeks.

**PATIENT**

Bailey Lankford

**Current Medications:** N/A.

**Labwork Results:** Labwork not submitted. Reported as cPLI elevated/gray zone, Monocytosis, Eosinophilia

**Date of Previous IntraPet Ultrasound:** No previous.

**Sedation:** Not required to complete full diagnostic ultrasound.

**Stat Report:** Not requested.

**Imaging Performed by:** Andi Parkinson, BS, RDMS.

**SPECIES**

Canine

**BREED**

Havanese mix

**SEX**

Male, neutered

**AGE**

3/8/2015

**WEIGHT**

23.2 lbs.

**INTERPRETED BY**

Andrea Nicastro, DVM,  
Diplomate ACVIM  
(Small Animal Internal  
Medicine)

**HOSPITAL NAME**

Timonium AH

**REFERRING VET**

Dr. Dmiszewicki

**INVOICE**

13730

**ULTRASONOGRAPHIC EXAMINATION OF THE ABDOMEN**

**Urinary System**

The urinary bladder wall is moderately distended. The wall is normal in thickness. The mucosal surface is slightly irregular. A small amount of gravity-dependent mineralized sand is observed within the lumen. The region of the trigone is normal.

The prostate is not definitively visualized due to its pelvic location.

The left kidney is normal in size (4.56 cm in length) with a normal shape, architecture and smooth peripheral margins. There is a normal 1:3 cortex to medulla ratio with mild to moderate loss of corticomedullary distinction. Small non-obstructive mineralized foci are visualized. There is no evidence of pyelectasia, infarcts or hydroureter. At least one small cortical cyst is seen.

The right kidney is normal in size (4.91 cm in length) with a normal shape, architecture and smooth peripheral margins. There is a normal 1:3 cortex to medulla ratio with mild to moderate loss of corticomedullary distinction. Small non-obstructive mineralized foci are visualized. There is no evidence of pyelectasia, infarcts or hydroureter.

**Adrenal Glands**

The left adrenal gland is normal in size (0.44 cm at cranial pole) (0.47 cm at caudal pole) with a normal shape and homogenous parenchyma. The glandular echogenicity and detail are unremarkable. Capsule, cortex, and medullary definition are normal. The phrenicoabdominal vein and surrounding vasculature are normal.

The right adrenal gland is normal in size (0.65 cm at cranial pole) (0.56 cm at caudal pole) with a normal shape and homogenous parenchyma. The glandular echogenicity and detail are unremarkable. Capsule, cortex, and medullary definition are normal. The phrenicoabdominal vein and surrounding vasculature are normal.

**Spleen**

The spleen is normal in size (1.53 cm in width at the level of the hilus) with a normal capsular contour. There is appropriate echogenicity and echotexture. No focal lesions are observed. Splenic vasculature is normal.

**Liver**

The liver is normal to slightly prominent in size with smooth peripheral contours. The parenchyma is isochoic relative to the spleen and exhibits mild heterogeneity. No distinct focal lesions are observed. Hepatic vasculature and biliary tracts are of normal volume with no evidence of congestion.

The gall bladder lumen is moderately distended. The wall is thin and smooth. A small to moderate amount of mobile echogenic to mineralized debris/sand is observed within the lumen. The cystic and common bile ducts are normal/not seen.

### ***Gastrointestinal***

The gastric lumen is not distended. The gastric wall and pylorus are normal in thickness with a normal layering pattern. The pyloric outflow tract is patent. The small intestinal lumen is not dilated. The small intestinal wall is normal in thickness with a normal layering pattern and appropriate mural detail. Discreet masses are not identified. The colonic wall is normal. There is no evidence of an obstructive pattern.

### ***Pancreas***

The region of the pancreas is isoechoic relative to surrounding omental fat. No obvious parenchymal abnormalities are observed. There is no evidence of regional inflammation or effusion.

### ***Lymph nodes***

At least one prominent mesenteric lymph node is visualized measuring 2.98 x 0.52 cm.

### ***Free Abdomen***

There is no obvious evidence of free fluid.

## **ULTRASONOGRAPHIC FINDINGS**

- The hepatic changes are nonspecific and could be secondary to inflammatory disease (i.e., cholangiohepatitis, chronic hepatitis), Leptospirosis, hepatotoxicosis, infiltrative neoplasia (i.e., lymphoma), vacuolar hepatopathy, regenerative nodular hyperplasia, other hepatopathy, or some combination thereof. Correlation with the patient's liver values is recommended.
- Gallbladder debris/sand, non-mucocele
- Urinary bladder sand
- Bilateral nonspecific, age-related renal changes with non-obstructive nephrolithiasis
- The prominent abdominal lymph nodes are most consistent with reactive lymphadenitis or lymphoid hyperplasia. Neoplastic infiltration is considered less likely.

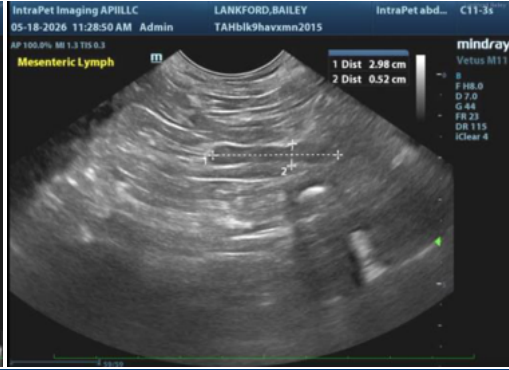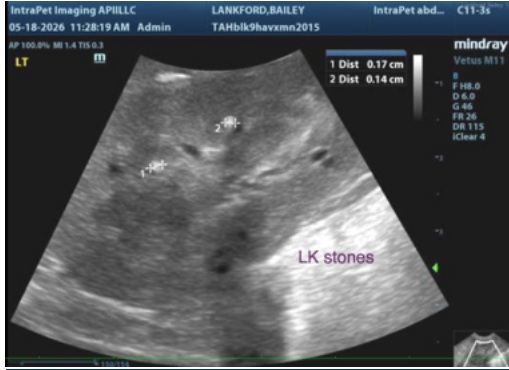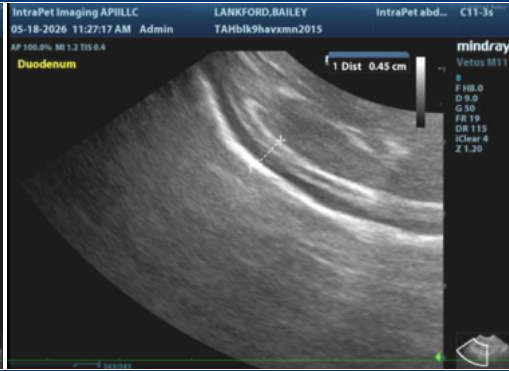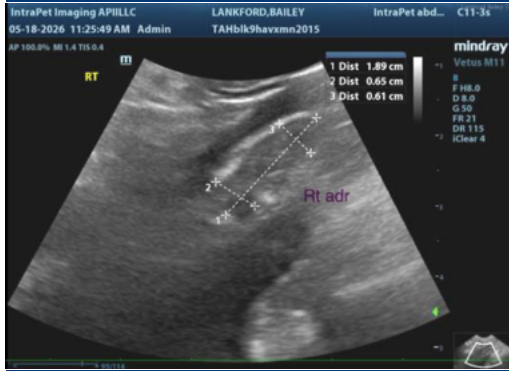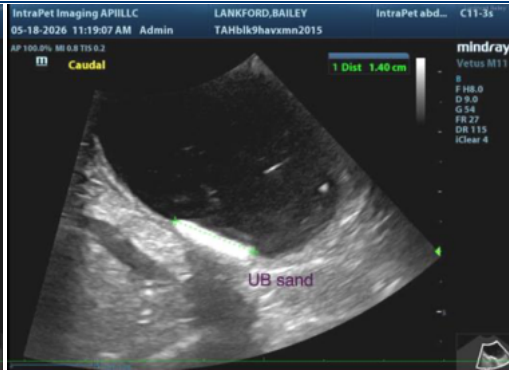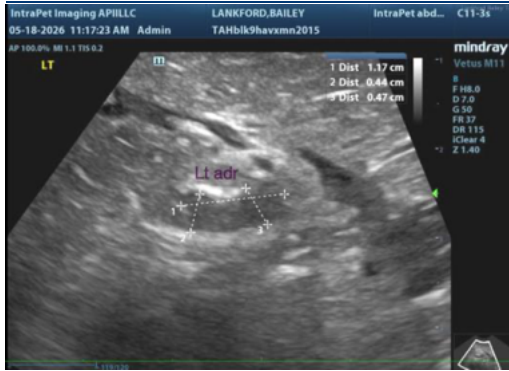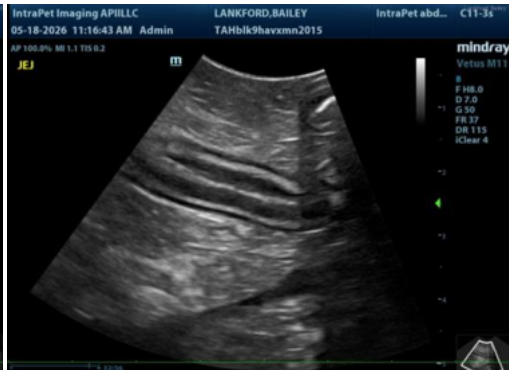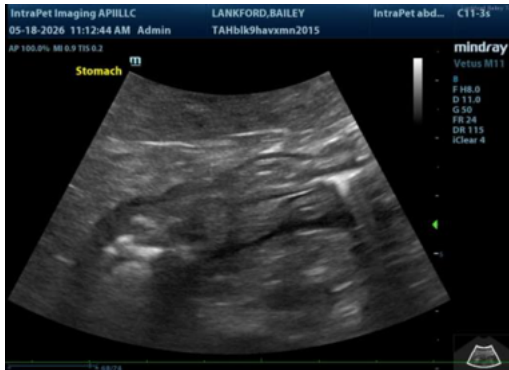\*\*An obvious cause for the patient's clinical signs is not definitively identified in this study. Considerations include a microscopic enteropathy (i.e., food allergy/intolerance, inflammatory bowel disease, infectious/parasitic disease), underlying metabolic issue, other.

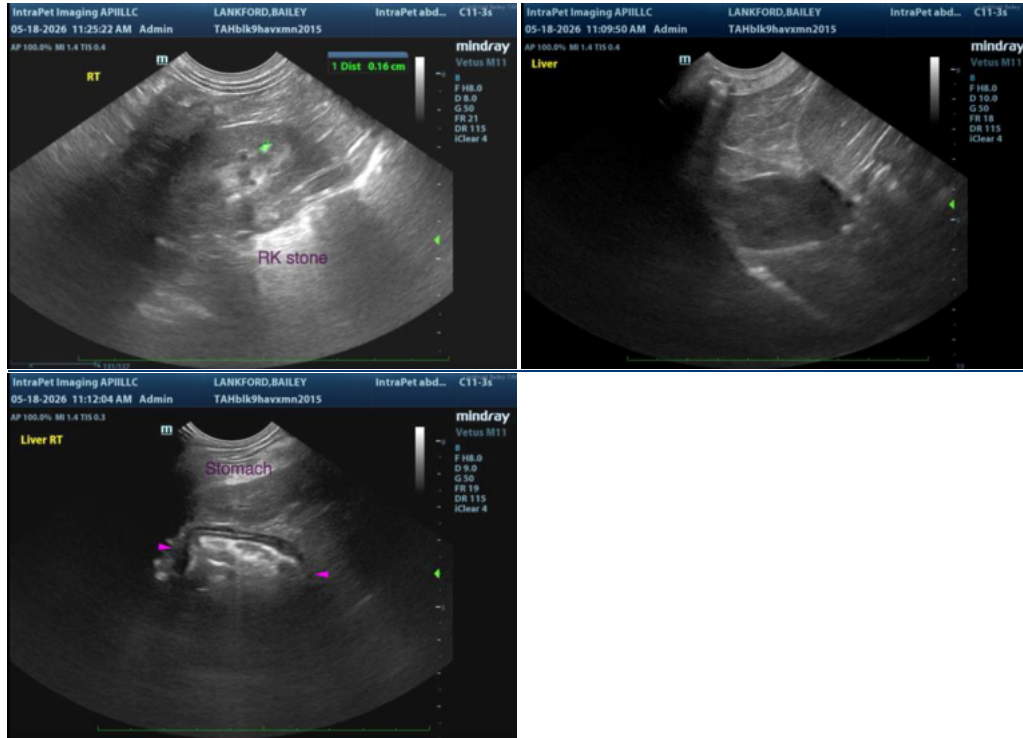
## **INTERPRETATION OF THE FINDINGS & FURTHER RECOMMENDATIONS**

The following diagnostics/treatment recommendations can be considered:

- A minimum database including a CBC chemistry panel, urinalysis and T4 is recommended (if not already performed).
- Texas GI panel including serum cobalamin, folate, PLI, TLI and resting cortisol level
- Fecal evaluation for ova/Giardia
- Prophylactic deworming with Fenbendazole.
- 3-4 week hypoallergenic or hydrolyzed protein diet trial
- Initiation of a probiotic with a high colony count +/- fiber supplement (i.e., psyllium).

Depending on the results of the above diagnostics/therapeutics, endoscopic or surgical gastrointestinal biopsies may be warranted. Three-view thoracic radiographs should be performed prior to any anesthetic event.





The information and recommendations provided are based on the images presented by the referring veterinarian/sonographer. No evaluation can be communicated regarding pathology that was not visible in the image/video clips provided.

Thank you for this referral. If the clinical or image interpretation does not parallel your findings or if I can be of any further assistance please contact me.

Andrea Nicastro, MPH, DVM, Diplomate DACVIM (Small Animal Internal Medicine) [info@SonoPath.com](mailto:info@SonoPath.com)