

**DATE PRESENTING CLINICAL SIGNS**

5/17/22

Patient presents for evaluation of loose stool and otherwise clinically normal. Elevated FPL noted on labwork otherwise WNL.

PATIENT

Charlie Kottyan

Current Medications: None current but treating for pancreatitis. Will be on Gabapentin for scan.

Lab Results: Elevated FPL.

Date of Previous IntraPet Ultrasound: No previous.

Sedation: Not required to complete full diagnostic ultrasound.

Stat Report: Not requested.

SPECIES

Feline

Imaging Performed By: Andi Parkinson, BS, RDMS.

BREED

Domestic shorthair

ULTRASONOGRAPHIC EXAMINATION OF THE ABDOMEN**Urinary System**

The urinary bladder, trigone, and pelvic urethra are normal in thickness and the mucosal surface is smooth.

The bladder lumen is moderately distended with anechoic urine. No masses, inflammatory changes or calculi are observed. The cystourethral junction and visible portion of the proximal urethra are normal.

SEX

Male, neutered

The left kidney is normal size (4.13 cm in length) with a slightly irregular shape. There is a normal 1:3 cortex to medulla ratio with moderate loss of corticomedullary distinction. There is no evidence of pyelectasia, nephroliths or hydroureter.

AGE

1/1/2008

The right kidney is normal size (4.03 cm in length); normal shape and architecture with smooth peripheral margins. There is a normal 1:3 cortex to medulla ratio with moderate loss of corticomedullary distinction.

There is no evidence of pyelectasia, nephroliths, infarcts or hydroureter.

WEIGHT

11 lbs.

Adrenal Glands

The left adrenal gland is normal in size (0.42 cm width). Normal shape and glandular echogenicity. The phrenicoabdominal vein and surrounding vasculature are normal.

INTERPRETED BY

Andrea Nicastro, DVM,
Diplomate ACVIM
(Small Animal Internal
Medicine)

The region of the right adrenal gland is evaluated. No obvious pathology is observed.

Spleen

The spleen is normal in size (0.87 cm in width at the level of the hilus) with a normal capsular contour. There is appropriate echogenicity and echotexture. No focal lesions are observed. Splenic vasculature is normal.

HOSPITAL NAME

Perry Hall AH

Liver

The liver is subjectively normal in size with normal contours and structure. There is appropriate echogenicity and echotexture. No overt structural evidence of inflammatory, infiltrative or regenerative pathology is evident. Vascular and biliary tracts are of normal volume with no evidence of congestion. No pathological hepatic lymphadenopathy observed. The portal vein: caudal vena cava ratio is approximately 1:1. The gall bladder lumen is moderately distended. The wall is thin and smooth. Luminal contents are anechoic. The cystic and common bile ducts are visible/tortuous but not overtly dilated.

REFERRING VET

Dr. Miller

INVOICE

13379

Gastrointestinal

The stomach and intestine are free of stasis and exhibit normal peristaltic activity. The gastric lumen is not distended. The gastric wall and pylorus are normal in thickness with a normal layering pattern. The pyloric outflow tract is patent. The small intestinal lumen is not dilated. The small intestinal wall thickness is normal with a normal layering pattern and appropriate mural detail. Discreet masses are not identified. The ileocecal colic junction and colonic wall are normal. No obstructive disease is noted.

Pancreas

The pancreas is diffusely prominent to enlarged with irregular peripheral contours. The parenchyma is hypoechoic relative to surrounding omental fat and mottled in appearance with numerous varying sized ill-defined hypoechoic nodules throughout the organ. The pancreatic duct is visible but not overtly dilated (0.18 cm in diameter). There is no evidence of peripancreatic effusion.

Free Abdomen

There is no evidence of free fluid. The abdominal lymph nodes are normal/not visible.

ULTRASONOGRAPHIC FINDINGS

Primary Findings:

- The pancreatic changes are most consistent with chronic pancreatitis with benign nodular hyperplasia. Pancreatic neoplasia is also a possibility but considered less likely.

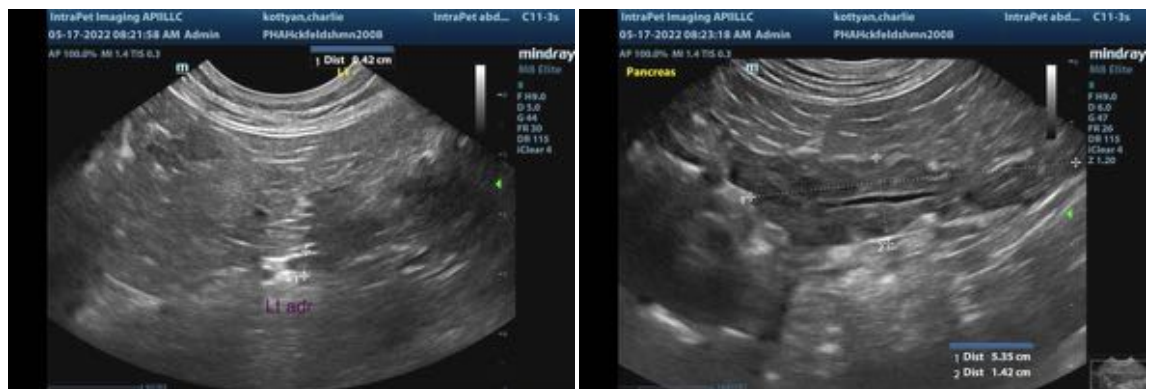
Secondary Findings:

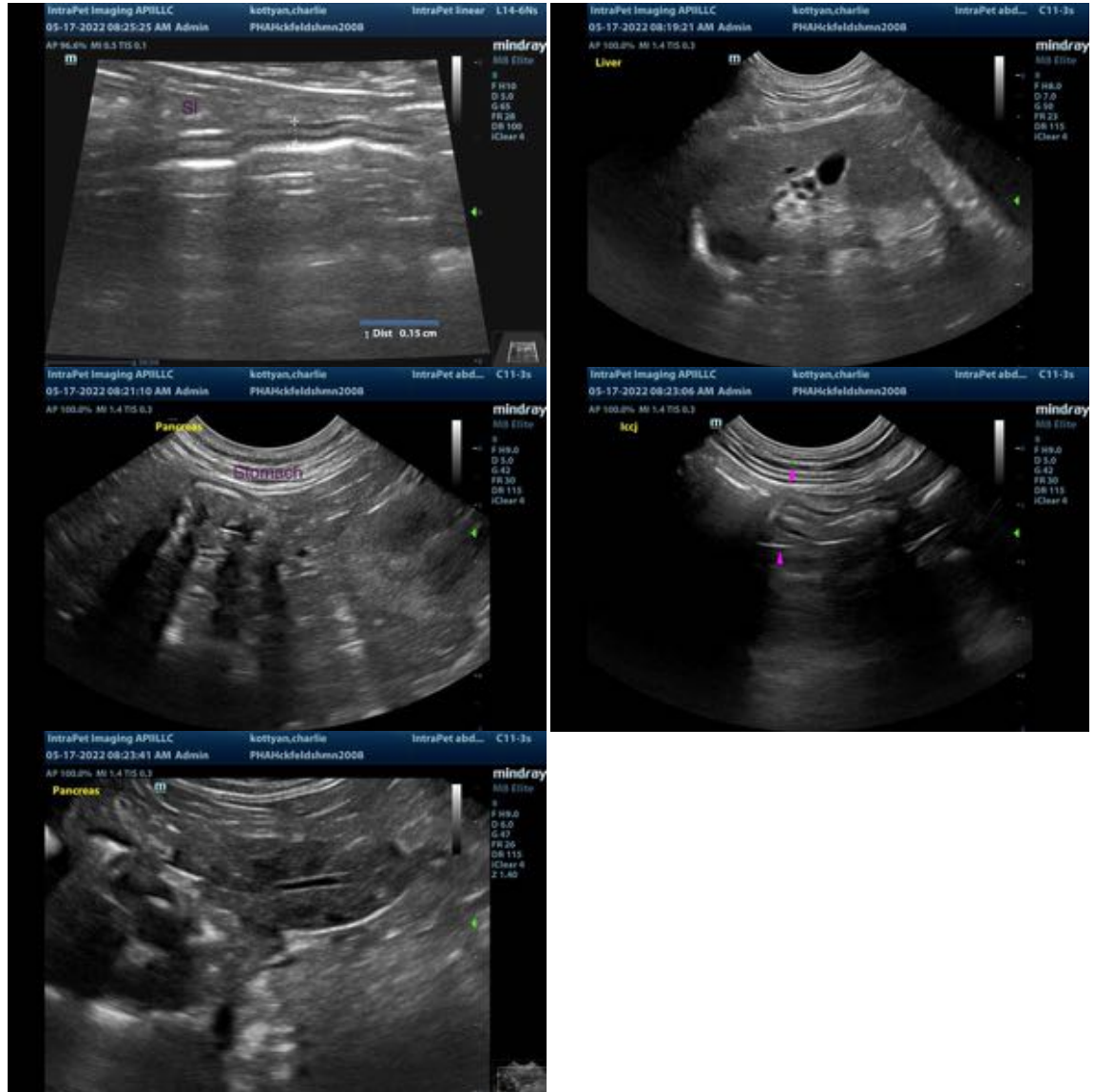- Bilateral, age-related renal changes.

*A definitive cause for the patient's clinical signs is not identified in this study. Considerations include chronic pancreatitis, microscopic gastrointestinal disease (i.e., inflammatory bowel disease, food allergy/intolerance), underlying metabolic issue, other.

INTERPRETATION OF THE FINDINGS & FURTHER RECOMMENDATIONS

- A fecal evaluation for ova/Giardia, if not already performed.
- Prophylactic deworming with Fenbendazole at 50 mg/kg once a day for 5 days is recommended. Repeat above protocol in 3 weeks.
- A GI panel (send to Texas A&M) is also recommended.
- A 6-week limited antigen diet trial to assess for food allergies
- Depending on the results of the above diagnostics/therapeutics, GI biopsies (i.e., endoscopic or surgical) may be necessary to get a definitive diagnosis. Given the patient's age, thoracic radiographs are recommended prior to anesthesia to assess cardiopulmonary status.





The information and recommendations provided are based on the images presented by the referring veterinarian. No evaluation can be communicated regarding pathology that was not visible in the image/video clips provided.

Thank you for this referral. If the clinical or image interpretation does not parallel your findings or if I can be of any further assistance please contact me.

Andrea Nicastro, DVM, Diplomate ACVIM (*Small Animal Internal Medicine*)
 Andrea.nicastro@sonopath.com