



PATIENT

Leon Mazyck III

SPECIES

Canine

BREED

Golden Retriever

SEX

Neutered Male

AGE

8

WEIGHT

Not Provided

INTERPRETED BY

Andrea Nicastro DVM
Diplomate ACVIM
(Sm Animal Internal Med)

**IMAGING
PERFORMED BY**

Andrea Nicastro DVM
Diplomate ACVIM
(Sm Animal Internal Med)

HOSPITAL NAME

VCA Westbury AH

REFERRING VET

Heather Caughey DVM

INVOICE

23015

DATE

5-14-26

PRESENTING CLINICAL SIGNS

Patient is asymptomatic with 2+ proteinuria on a urinalysis. The remaining lab-work is otherwise unremarkable, except for a total calcium of 8.4. T4 normal. Fecal negative. USG 1.042 with inactive sediment.

ULTRASONOGRAPHIC EXAMINATION OF THE ABDOMEN

Urinary System

The urinary bladder wall is normal in thickness. The mucosal surface is smooth. The bladder is moderately distended. Luminal contents are anechoic. No cystic calculi are observed. The region of the trigone and the proximal urethra, visible to a depth of 4.5 cm, are normal.

The prostate is normal in size (1.01 cm in width) and shape. Parenchyma is homogenous. The prostatic urethra appears normal without evidence of dilation or obstruction.

The left kidney is normal in size (6.49 cm in length) with a normal shape, architecture and smooth peripheral margins. There is a normal 1:3 cortex to medulla ratio with normal corticomedullary distinction. There is no evidence of pyelectasia, nephroliths, infarcts or hydronephrosis. Renal vasculature is normal.

The right kidney is normal in size (5.96 cm in length) with a normal shape, architecture and smooth peripheral margins. There is a normal 1:3 cortex to medulla ratio with normal corticomedullary distinction. There is no evidence of pyelectasia, nephroliths, infarcts or hydronephrosis. Renal vasculature is normal.

Adrenal Glands

The left adrenal gland is normal in size (0.48 cm at cranial pole) (0.50 cm at caudal pole) with a normal shape and homogenous parenchyma. The glandular echogenicity and detail are unremarkable. Capsule, cortex, and medullary definition are normal. The phrenicoabdominal vein and surrounding vasculature are normal.

The right adrenal gland is normal in size (0.68 cm at cranial pole) (0.56 cm at caudal pole) with a normal shape and homogenous parenchyma. The glandular echogenicity and detail are unremarkable. Capsule, cortex, and medullary definition are normal. The phrenicoabdominal vein and surrounding vasculature are normal.

Spleen

The spleen is normal in size (1.63 cm in width at the level of the hilus) with a normal capsular contour. There is appropriate echogenicity and echotexture. No focal lesions are observed. Splenic vasculature is normal.

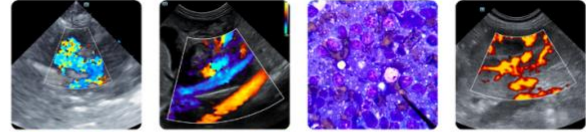
Liver

The liver is subjectively normal in size with normal contours and structure. There is appropriate echogenicity and echotexture. No overt structural evidence of inflammatory, infiltrative, or regenerative pathology is evident. Vascular and biliary tracts are of normal volume with no evidence of congestion. The portal vein to caudal vena cava ratio is approximately 1: 1.

The gallbladder is moderately-distended. The wall is normal in thickness. A 1.54 cm irregular cholelith or cluster of choleliths are observed within the lumen. The cystic and common bile ducts are normal/not seen.

Gastrointestinal

The gastric lumen is not distended. The gastric wall and pylorus are normal in thickness with a normal layering pattern. The pyloric outflow tract is patent. The small intestinal lumen is not dilated. The small intestinal wall is normal in thickness with a normal layering pattern and appropriate mural detail. Discreet



PATIENT

Leon Mazyck III

masses are not identified. The ileoceceocolic junction and colonic wall are normal. There is no evidence of an obstructive pattern.

SPECIES

Canine

Pancreas

The region of the pancreas is isoechoic relative to surrounding omental fat. No obvious parenchymal abnormalities are observed. There is no evidence of regional inflammation or effusion.

BREED

Golden Retriever

Lymph Nodes

The abdominal lymph nodes are normal/not visible.

SEX

Neutered Male

Free Abdomen

The peritoneal cavity is normal. There is no evidence of inflammation or effusion.

AGE

8

ULTRASONOGRAPHIC FINDINGS

Structurally unremarkable abdomen.

WEIGHT

Not Provided

INTERPRETATION OF THE FINDINGS & FURTHER RECOMMENDATIONS

A UPC is recommended (preferably on a free catch samples at home pooled over a 24–48-hour period). If the UPC is significantly elevated, further work-up (i.e., infectious disease testing, thoracic radiographs), along with therapy for protein-losing nephropathy, may be warranted.

INTERPRETED BY

Andrea Nicastrò DVM
 Diplomate ACVIM
 (Sm Animal Internal Med)

IMAGING PERFORMED BY

Andrea Nicastrò DVM
 Diplomate ACVIM
 (Sm Animal Internal Med)

HOSPITAL NAME

VCA Westbury AH

REFERRING VET

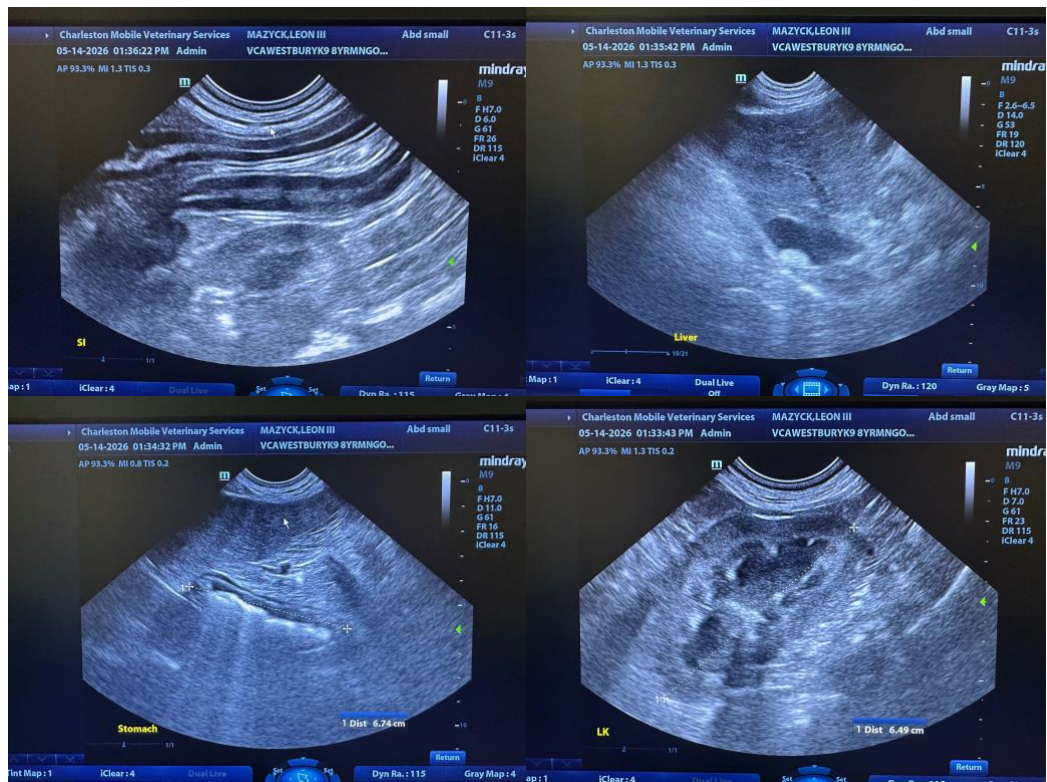
Heather Caughey DVM

INVOICE

23015

DATE

5-14-26





PATIENT

Leon Mazyck III

SPECIES

Canine

BREED

Golden Retriever

SEX

Neutered Male

AGE

8

WEIGHT

Not Provided

INTERPRETED BY

Andrea Nicastrò DVM
 Diplomate ACVIM
 (Sm Animal Internal Med)

IMAGING PERFORMED BY

Andrea Nicastrò DVM
 Diplomate ACVIM
 (Sm Animal Internal Med)

HOSPITAL NAME

VCA Westbury AH

REFERRING VET

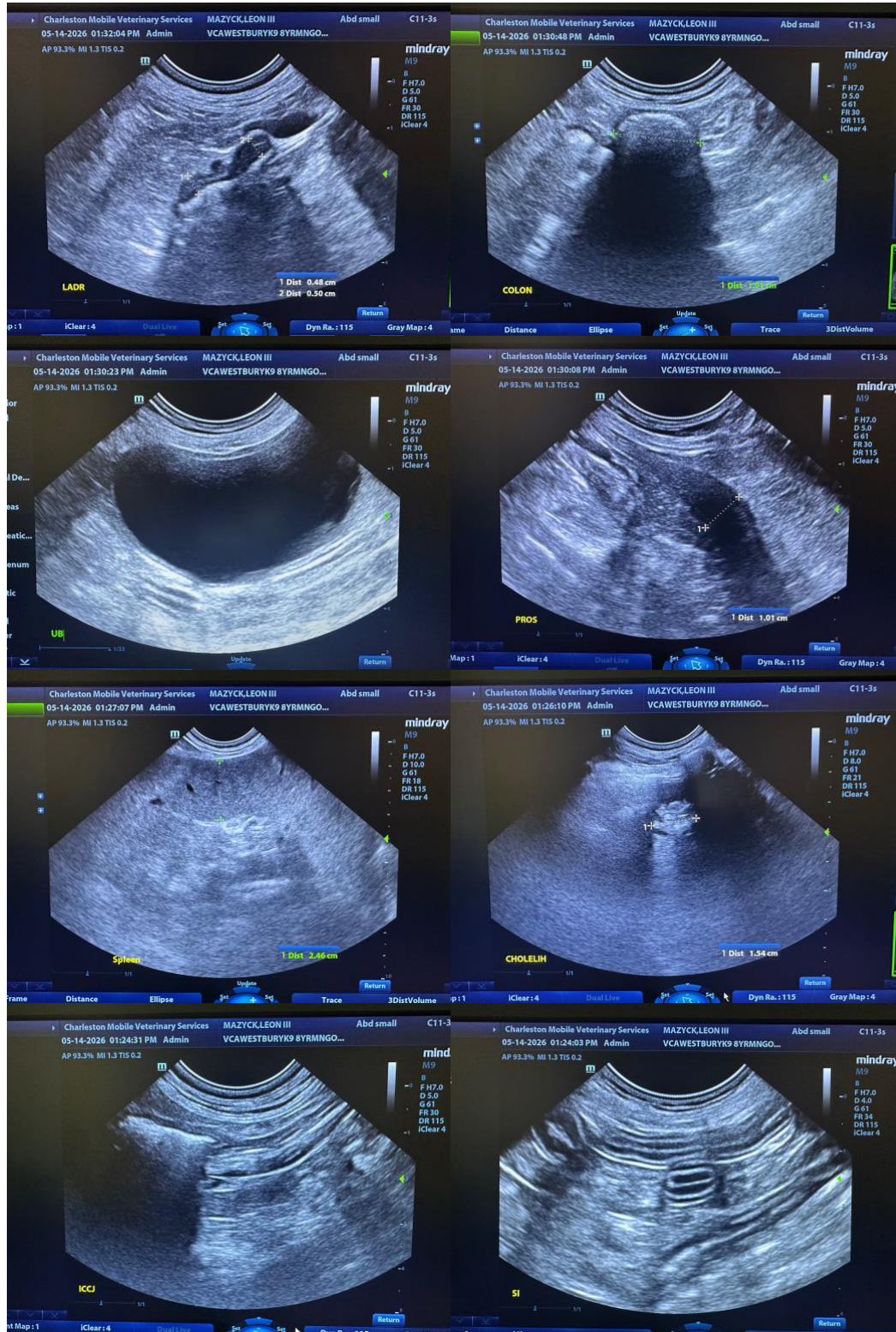
Heather Caughey DVM

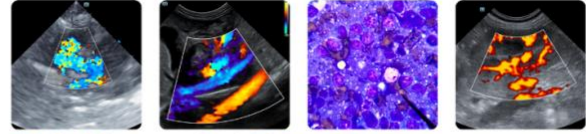
INVOICE

23015

DATE

5-14-26





PATIENT

Leon Mazyck III

SPECIES

Canine

BREED

Golden Retriever

SEX

Neutered Male

AGE

8

WEIGHT

Not Provided

INTERPRETED BY

Andrea Nicastro DVM
 Diplomate ACVIM
 (Sm Animal Internal Med)

IMAGING PERFORMED BY

Andrea Nicastro DVM
 Diplomate ACVIM
 (Sm Animal Internal Med)

HOSPITAL NAME

VCA Westbury AH

REFERRING VET

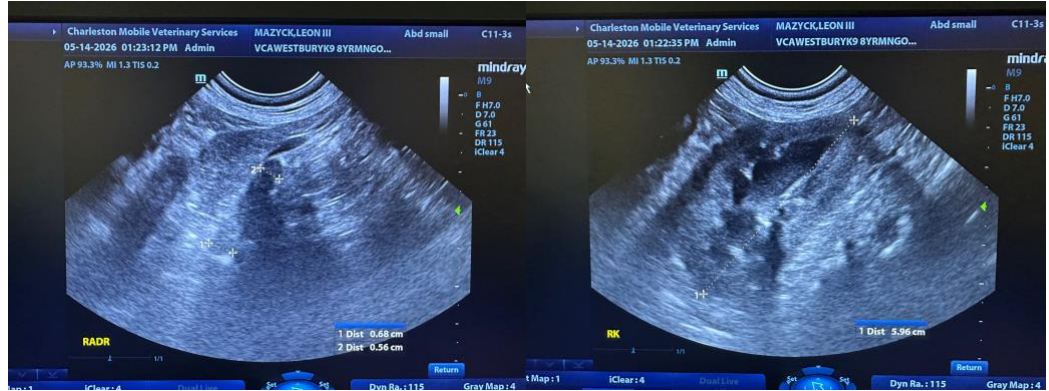
Heather Caughey DVM

INVOICE

23015

DATE

5-14-26



The information and recommendations provided are based on the images presented by the referring veterinarian/sonographer. No evaluation can be communicated regarding pathology that was not visible in the image/video clips provided.

Thank you for this referral. If the clinical or image interpretation does not parallel your findings or if I can be of any further assistance, please contact me.

Andrea Nicastro, MPH, DVM, Diplomate DACVIM (Small Animal Internal Medicine)
info@SonoPath.com