



PATIENT	PRESENTING CLINICAL SIGNS
Gomer Ortiz	History: still vomiting on and off since 4/28 re check
SPECIES	ULTRASONOGRAPHIC EXAMINATION OF THE ABDOMEN
Canine	Urinary System The urinary bladder, trigone, and pelvic urethra are normal in thickness and the mucosal surface is smooth. The bladder lumen is mildly distended with anechoic urine. No masses, inflammatory changes or calculi are observed. Ureteral papillae and visualized portion of the proximal urethra, visible to a depth of 2 cm, are normal.
BREED	
Bulldog Mix	The prostate is not definitively visualized due to its pelvic location.
SEX	
Neutered Male	The left kidney presented normal size (4.81 cm in length); normal shape and architecture with smooth peripheral margins. There is a normal 1:3 cortex to medulla ratio with normal corticomedullary distinction. There is no evidence of pyelectasia, nephroliths, infarcts or hydroureter. Renal vasculature is normal.
AGE	
1 year	The right kidney presented normal size (4.38 cm in length); normal shape and architecture with smooth peripheral margins. There is a normal 1:3 cortex to medulla ratio with normal corticomedullary distinction. There is no evidence of pyelectasia, nephroliths, infarcts or hydroureter. Renal vasculature is normal.
WEIGHT	Adrenal Glands The left adrenal gland is normal size (0.47 cm at cranial pole) (0.52 cm at caudal pole) (1.62 cm in length); normal shape; homogenous parenchyma. The glandular echogenicity and detail are unremarkable. Capsule, cortex, and medullary definition are normal. The phrenicoabdominal vein and surrounding vasculature are normal.
INTERPRETED BY	
Andrea Nicastro, DVM, Diplomate ACVIM (Small Animal Internal Medicine)	The right adrenal gland is normal size (0.75 cm at cranial pole) (0.60 cm at caudal pole) (2.15 cm in length); normal shape; homogenous parenchyma. The glandular echogenicity and detail are unremarkable. Capsule, cortex, and medullary definition are normal. The phrenicoabdominal vein and surrounding vasculature are normal.
IMAGING PERFORMED BY	Spleen The spleen is normal in size (1.08 cm in width at the level of the hilus) with a normal capsular contour. There is appropriate echogenicity and echotexture. No focal lesions are observed. Splenic vasculature is normal.
Jenn	Liver The liver is subjectively normal in size with normal contours and structure. There is appropriate echogenicity and echotexture. No overt structural evidence of inflammatory, infiltrative or regenerative pathology is evident. Vascular and biliary tracts are of normal volume with no evidence of congestion. No pathological hepatic lymphadenopathy observed.
HOSPITAL NAME	
Rockaway	
REFERRING VET	The gall bladder lumen is moderately distended. The wall is thin and smooth. Luminal contents are anechoic. The cystic and common bile ducts are normal.
Dr. Maniar	Gastrointestinal The stomach and intestine are free of stasis and exhibit normal peristaltic activity. The gastric lumen is not distended. The gastric wall and pylorus are normal in thickness with a normal layering pattern. The small intestinal lumen is not dilated. The small intestinal wall thickness is normal with a normal layering pattern
INVOICE	
10901	
DATE	
5/12/22	

and appropriate mural detail. Discreet masses are not identified. The colonic wall is normal. No obstructive or overt infiltrative disease is noted.

Pancreas

The region of the pancreas is isoechoic relative to surrounding omental fat. No obvious parenchymal abnormalities are observed. There is no evidence of regional inflammation or effusion.

Free Abdomen

The peritoneal cavity is normal. There is no evidence of inflammation or effusion. The abdominal lymph nodes are normal/not visible.

ULTRASONOGRAPHIC FINDINGS

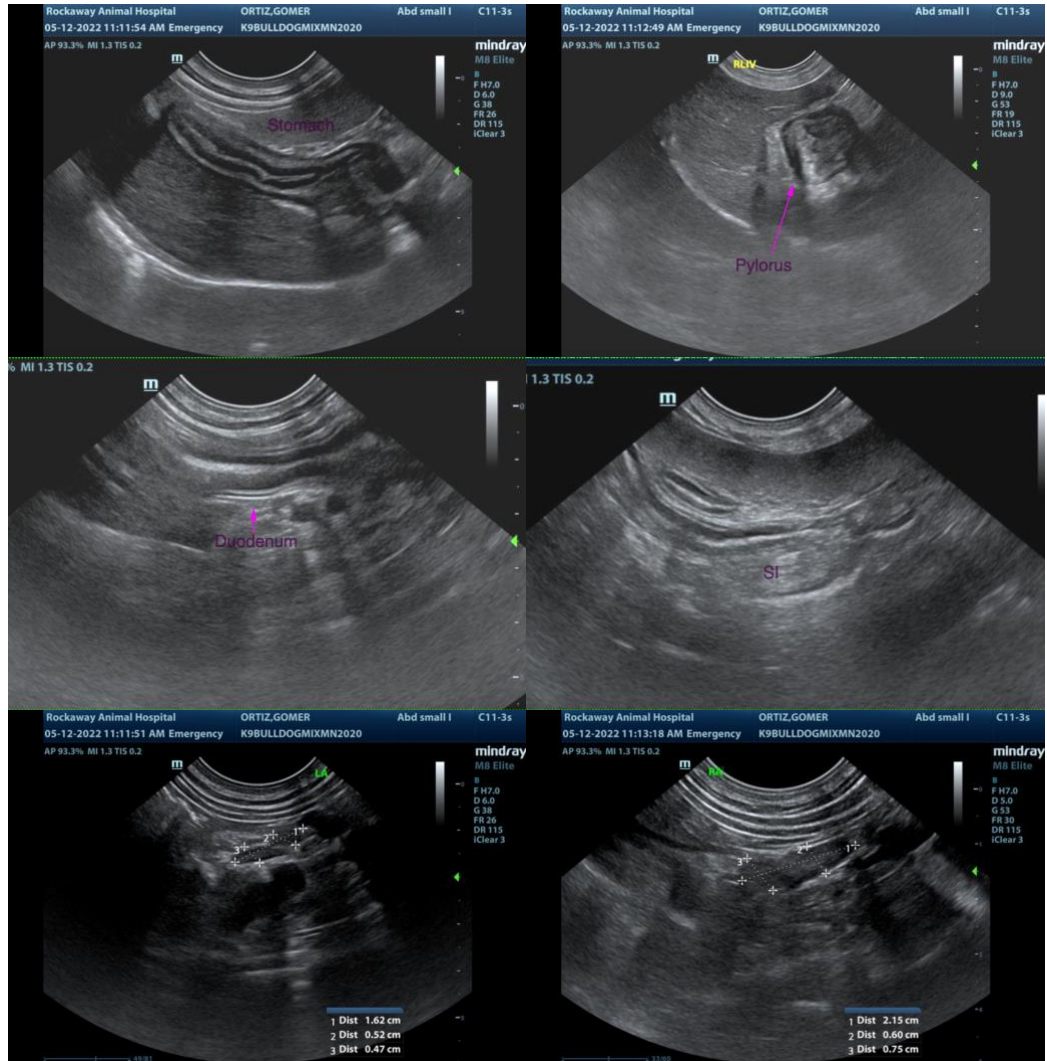
Primary Findings

- Unremarkable abdomen. An obvious cause for the patient's chronic vomiting is not identified in this study. Considerations include microscopic gastrointestinal disease (i.e., inflammatory bowel disease, food allergy/intolerance), underlying metabolic issue (i.e., hypoadrenocorticism), low-grade pancreatitis, other.

INTERPRETATION OF THE FINDINGS & FURTHER RECOMMENDATIONS

Given the chronicity of the vomiting, consider a more advanced GI workup, which could include the following:

1. Baseline lab work, including a CBC Chemistry panel, urinalysis and T4, if not already performed.
2. Three-view thoracic radiographs to assess cardiopulmonary status
3. Thoracic radiographs to assess for occult esophageal disease
4. Fecal evaluation for ova and Giardia
5. Malabsorption panel, including serum cobalamin and folate, TLI and PLI
6. A resting cortisol level to screen for hypoadrenocorticism. If resting cortisol level is < 2.0 mcg/dL, an ACTH stimulation test is recommended.
7. Pre-and postprandial serum bile acids to assess for occult hepatic dysfunction
8. Hypoallergenic diet trial
9. +/- gastrointestinal biopsies (i.e., endoscopic, or surgical)



The information and recommendations provided are based on the images presented by the referring veterinarian/sonographer. No evaluation can be communicated regarding pathology that was not visible in the image/video clips provided.

Thank you for this referral. If the clinical or image interpretation does not parallel your findings or if I can be of any further assistance, please contact me.

Andrea Nicastro, DVM, Diplomate DACVIM (Small Animal Internal Medicine)
info@SonoPath.com