



DATE PRESENTING CLINICAL SIGNS

5/11/26

Patient History: Grade 3/6 heart murmur, previously diagnosed chronic degenerative valve disease, but no meds indicated at that time. P is still asymptomatic, O would like to recheck to check progression. ALP 1113 (prev 370 in April 2025)- unsure if any pu/pd noted

PATIENT

Squirt Yap

Current Medications: None.

Labwork Results: Labwork attached, reported as: 4/30/26: alp 1113. 4/23/2025: alp 370

Date of Previous IntraPet Ultrasound: No previous.

Sedation: Not required to complete full diagnostic ultrasound.

Stat Report: Not requested.

Imaging Performed by: Stephanie Warga RDCS, RVT.

SPECIES

Canine

BREED

Chihuahua mix

SEX

Female, spayed

AGE

1/1/2017

WEIGHT

8.32 lbs.

INTERPRETED BY

Andrea Nicastro, DVM,
Diplomate ACVIM
(Small Animal Internal
Medicine)

HOSPITAL NAME

Everhart VH

REFERRING VET

Dr. DelFavero

INVOICE

13708

ULTRASONOGRAPHIC EXAMINATION OF THE ABDOMEN

Urinary System

The urinary bladder wall is normal in thickness and the mucosal surface is smooth. The bladder is mildly to moderately distended. Luminal contents are anechoic. No cystic calculi are observed. The region of the trigone and the visible portion of the proximal urethra are normal.

The left kidney is normal in size (3.46 cm in length) with a normal shape, architecture and smooth peripheral margins. There is a normal 1:3 cortex to medulla ratio with minimal loss of corticomedullary distinction. There is no evidence of pyelectasia, nephroliths, infarcts or hydroureter. Renal vasculature is normal.

The right kidney is normal in size (3.55 cm in length) with a normal shape, architecture and smooth peripheral margins. There is a normal 1:3 cortex to medulla ratio with minimal loss of corticomedullary distinction. There is no evidence of pyelectasia, nephroliths, infarcts or hydroureter. Renal vasculature is normal.

Adrenal Glands

The left adrenal gland is normal in size (0.40 cm at cranial pole) (0.49 cm at caudal pole) with a normal shape and homogenous parenchyma. The glandular echogenicity and detail are unremarkable. Capsule, cortex, and medullary definition are normal. The phrenicoabdominal vein and surrounding vasculature are normal.

The right adrenal gland is normal in size (0.55 cm at cranial pole) (0.48 cm at caudal pole) with a normal shape and homogenous parenchyma. The glandular echogenicity and detail are unremarkable. Capsule, cortex, and medullary definition are normal. The phrenicoabdominal vein and surrounding vasculature are normal.

Spleen

The spleen is normal in size (0.64 cm in width at the level of the hilus) with a normal capsular contour. There is appropriate echogenicity and echotexture. No focal lesions are observed. Splenic vasculature is normal.

Liver

The liver is subjectively normal in size with normal peripheral contours. The parenchyma is isoechoic relative to the spleen and diffusely homogeneous in appearance. No distinct focal lesions are observed. Vascular and biliary tracts are of normal volume with no evidence of congestion.

The gall bladder lumen is moderately distended. The wall is thin and smooth. A small amount of mobile echogenic debris is observed within the lumen. The cystic and common bile ducts are normal/not seen.

Gastrointestinal

The gastric lumen is not distended. The gastric wall and pylorus are normal in thickness with a normal layering pattern. The pyloric outflow tract is patent. The small intestinal lumen is not dilated. The small

intestinal wall is normal in thickness with a normal layering pattern and appropriate mural detail. Discreet masses are not identified. The colonic wall is normal. The colonic lumen contains some granular appearing fecal material. There is no obvious evidence of an obstructive pattern.

Pancreas

The region of the pancreas is isoechoic relative to surrounding omental fat. No obvious parenchymal abnormalities are observed. There is no evidence of regional inflammation or effusion.

Lymph nodes

The abdominal lymph nodes are normal/not visible.

Free Abdomen

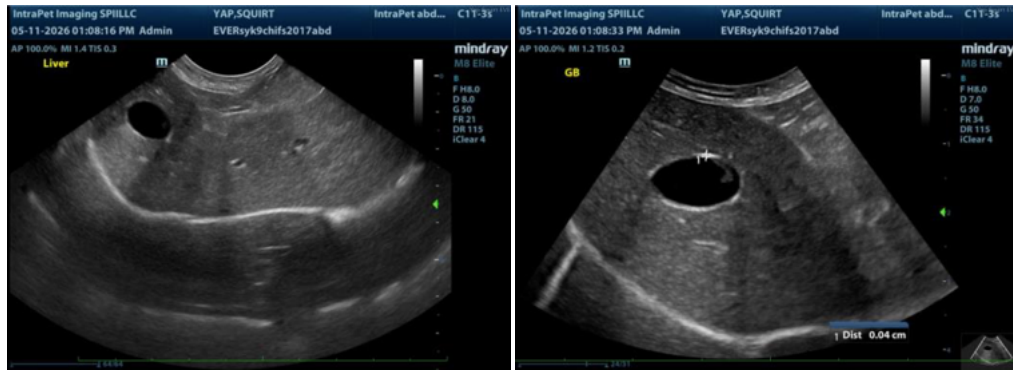
The peritoneal cavity is normal. There is no evidence of inflammation or effusion.

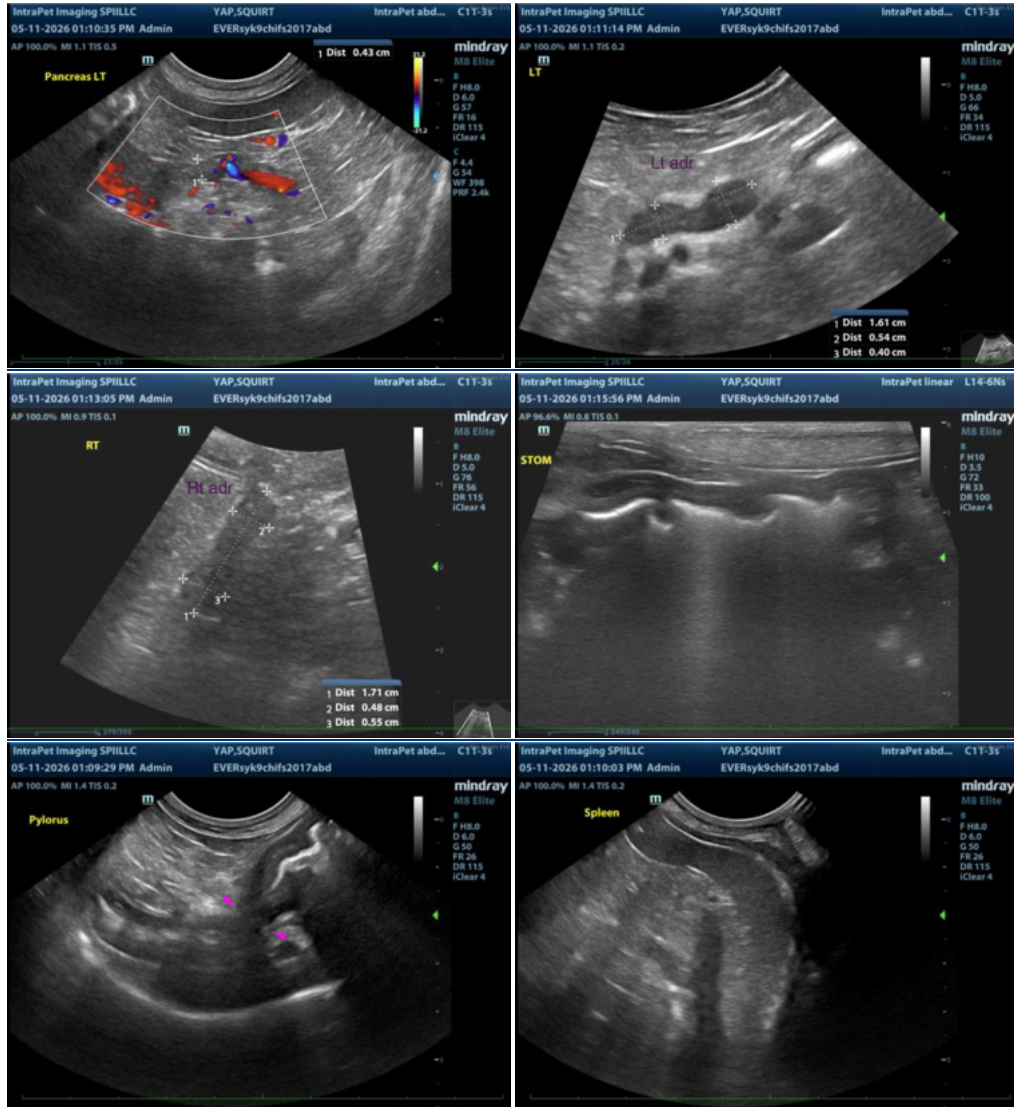
ULTRASONOGRAPHIC FINDINGS

- The diffuse hepatic changes are most consistent with vacuolar hepatopathy (i.e., endocrine, idiopathic) with a lower possibility of inflammatory disease, infiltrative neoplasia, or other hepatopathy.

INTERPRETATION OF THE FINDINGS & FURTHER RECOMMENDATIONS

Hepatic tissue sampling (i.e., aspirates or biopsies) can be considered. However, the results may be of low yield. If a more conservative approach is desired, serial monitoring (i.e., every 3-4 months) of the patient's liver values is recommended. If liver values continue to increase, a repeat abdominal ultrasound +/- hepatic tissue sampling may be warranted.





The information and recommendations provided are based on the images presented by the referring veterinarian/sonographer. No evaluation can be communicated regarding pathology that was not visible in the image/video clips provided.

Thank you for this referral. If the clinical or image interpretation does not parallel your findings or if I can be of any further assistance please contact me.

Andrea Nicastro, MPH, DVM, Diplomate DACVIM (Small Animal Internal Medicine) info@SonoPath.com