



PATIENT PRESENTING CLINICAL SIGNS

Loki Walters History: Employee pet. Brought in for diarrhea x2 weeks. P painful on abdomen on exam. No history of any abnormalities.

SPECIES Abnormal PE/Chem/CBC/UA Results: Full labs sent out, no results yet

Feline ULTRASONOGRAPHIC EXAMINATION OF THE ABDOMEN

BREED *Urinary System*

DLH The urinary bladder wall is normal in thickness. The mucosal surface is smooth. The bladder is moderately distended. A small amount of echogenic debris is observed within the lumen. No cystic calculi are observed. The region of the trigone and the proximal urethra, visible to a depth of 2 cm, are normal.

SEX

Neutered Male The left kidney is normal in size (4.33 cm in length) with a normal shape, architecture and smooth peripheral margins. There is a normal 1:3 cortex to medulla ratio with mild loss of corticomedullary distinction. Trace pyelectasia is present. There is no evidence of nephroliths, infarcts or hydronephrosis. Renal vasculature is normal.

AGE

9

The right kidney is normal in size (4.34 cm in length) with a normal shape, architecture and smooth peripheral margins. There is a normal 1:3 cortex to medulla ratio with mild loss of corticomedullary distinction. There is no evidence of pyelectasia, nephroliths, infarcts or hydronephrosis.

WEIGHT

5.4 kg

Adrenal Glands

The left adrenal gland is normal size (0.30 cm width). Normal shape and glandular echogenicity. The phrenicoabdominal vein and surrounding vasculature are normal.

INTERPRETED BY

Andrea Nicastro, DVM,
Diplomate ACVIM
(Small Animal Internal
Medicine)

The region of the right adrenal gland is evaluated. No obvious pathology is observed in this region.

Spleen

The spleen is normal in size (0.90 cm in width at the level of the hilus) with a normal capsular contour. There is appropriate echogenicity and echotexture. No focal lesions are observed. Splenic vasculature is normal.

IMAGING PERFORMED BY

Jordyn Walters

Liver

The liver is subjectively normal in size with normal curvilinear peripheral contours. The parenchyma is isoechoic relative to the spleen and diffusely homogeneous in appearance. No distinct focal lesions are observed. Vascular and biliary tracts are of normal volume with no evidence of congestion.

HOSPITAL NAME

Viking VH

The gallbladder lumen is moderately distended. The wall is thin and smooth. A scant amount of echogenic debris is observed within the lumen. The cystic and common bile ducts are normal/not seen.

REFERRING VET

Cassidy Smith

Gastrointestinal

The stomach and intestine are free of stasis and exhibit normal peristaltic activity. The gastric lumen is mildly to moderately-distended with ingesta, soft, shadowing material, and gas. The gastric wall and pylorus are normal in thickness with a normal layering pattern. The pyloric outflow tract is patent. The small intestinal lumen is not dilated. The small intestinal wall thickness is normal. There is disruption in the normal 1:3 muscularis: mucosal ratio in most segments. Discreet masses are not identified. The ileocecal colic junction and colonic wall are normal. No obstructive disease is noted.

INVOICE

22959

DATE

5-1-26

Pancreas

The region of the pancreas is isoechoic relative to surrounding omental fat. No obvious parenchymal abnormalities are observed. There is no evidence of regional inflammation or effusion.



PATIENT

Loki Walters **Lymph Nodes**
In the caudodorsal abdomen, just dorsal to the cystourethral junction, a 1.1 x 0.5 cm irregular, hypoechoic structure, thought to represent a sublumbar lymph node, is visualized. A few prominent mesenteric lymph nodes are also seen adjacent to the ileocecolic junction (one measuring 0.65 x 0.45 cm). The mesentery surrounding all nodes is hyperechoic.

SPECIES

Feline

Free Abdomen

There is no obvious evidence of free fluid.

BREED

DLH

ULTRASONOGRAPHIC FINDINGS

SEX

Primary Findings

Neutered Male

- The small intestinal wall changes could be consistent with inflammatory bowel disease, normal variation for an older feline patient, or emerging lymphoma. Correlation with the patient’s long-term clinical history is recommended.

AGE

9

- The gastric luminal contents may represent normal ingesta, foreign material and/or foreign material (i.e., hair). The material appears nonobstructive at the time of this study.

WEIGHT

5.4 kg

- The prominent abdominal lymph nodes are most consistent with reactive lymphadenitis or lymphoid hyperplasia. Neoplastic infiltration is considered less likely.

INTERPRETED BY

Secondary Findings

Andrea Nicastro, DVM,
Diplomate ACVIM
(Small Animal Internal
Medicine)

- Mild bilateral nonspecific age-related renal changes

INTERPRETATION OF THE FINDINGS & FURTHER RECOMMENDATIONS

IMAGING PERFORMED BY

Jordyn Walters

- A fecal evaluation for ova and Giardia is recommended, if not already performed.
- Also consider prophylactic deworming with fenbendazole.
- A GI panel including serum cobalamin and folate, TLI and PLI is also recommended, along with a 3-4-week limited antigen or hydrolyzed protein diet.
- Depending on the results of the above diagnostics, further work-up may be indicated.
- In the meantime, consider initiation of a probiotic as well as a fiber supplement (i.e., psyllium).

HOSPITAL NAME

Viking VH

REFERRING VET

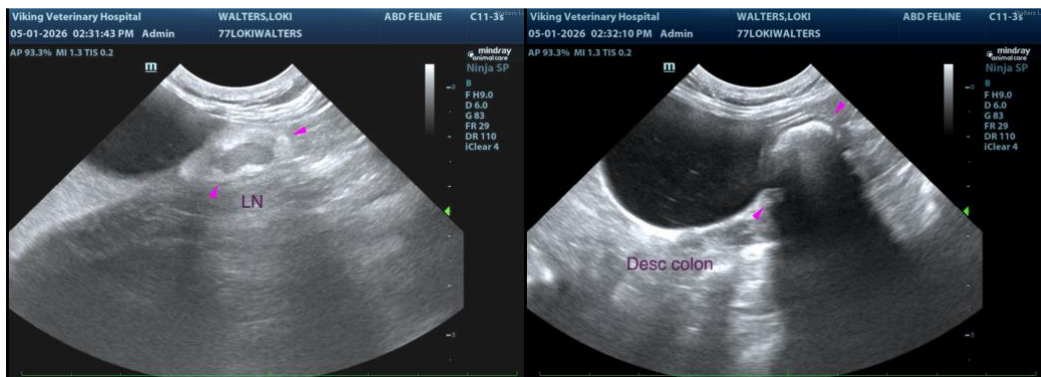
Cassidy Smith

INVOICE

22959

DATE

5-1-26





PATIENT

Loki Walters

SPECIES

Feline

BREED

DLH

SEX

Neutered Male

AGE

9

WEIGHT

5.4 kg

INTERPRETED BY

Andrea Nicastro, DVM,
Diplomate ACVIM
(Small Animal Internal
Medicine)

**IMAGING
PERFORMED BY**

Jordyn Walters

HOSPITAL NAME

Viking VH

REFERRING VET

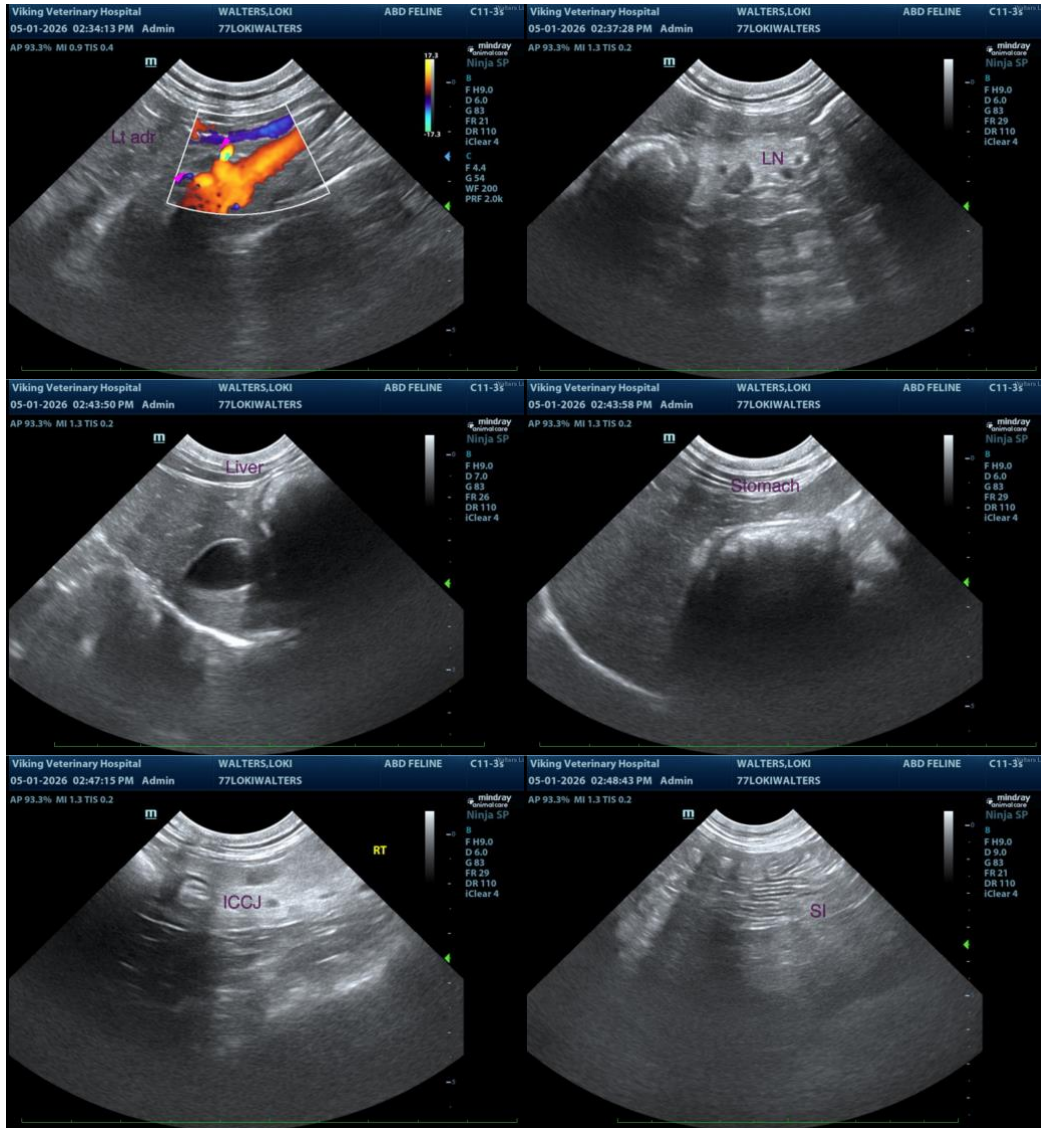
Cassidy Smith

INVOICE

22959

DATE

5-1-26



The information and recommendations provided are based on the images presented by the referring veterinarian/sonographer. No evaluation can be communicated regarding pathology that was not visible in the image/video clips provided.

Thank you for this referral. If the clinical or image interpretation does not parallel your findings or if I can be of any further assistance, please contact me.

Andrea Nicastro, MPH, DVM, Diplomate DACVIM (Small Animal Internal Medicine)
info@SonoPath.com