



PATIENT

Norman Livingston

SPECIES

Canine

BREED

Dachshund

SEX

Neutered Male

AGE

13 years

WEIGHT

13 lbs

INTERPRETED BY

Andrea Nicastro,
DVM, Diplomate ACVIM
(Small Animal Internal
Medicine)

IMAGING PERFORMED BY

Crystal Hill

HOSPITAL NAME

Nelson AH

REFERRING VET

Dr. Anderson

INVOICE

10707

DATE

4/7/22

PRESENTING CLINICAL SIGNS

History: Elevated ALT (123) and ALP (430). Has been on Clomipramine for anxiety.
Abnormal PE/Chem/CBC/UA Results: See above

ULTRASONOGRAPHIC EXAMINATION OF THE ABDOMEN

Urinary System

The urinary bladder is mildly distended. The wall is of appropriate thickness for the level of repletion. The luminal surface is slightly irregular. A scant amount of echogenic debris is suspended within the lumen. The region of the trigone and the visible portion proximal urethra are normal.

The prostate is normal in size (0.75 cm in width) and shape. Parenchyma is homogenous. The prostatic urethra appears normal without evidence of dilation or obstruction.

The left kidney presented normal size (4.80 cm in length); normal shape and architecture with smooth peripheral margins. There is a normal 1:3 cortex to medulla ratio with minimal loss of corticomedullary distinction. There is no evidence of pyelectasia, nephroliths, infarcts or hydronephrosis. Renal vasculature is normal.

The right kidney presented normal size (4.66 cm in length); normal shape and architecture with smooth peripheral margins. There is a normal 1:3 cortex to medulla ratio with minimal loss of corticomedullary distinction. There is no evidence of pyelectasia, nephroliths, infarcts or hydronephrosis. Renal vasculature is normal.

Adrenal Glands

The left adrenal gland is mildly enlarged (0.67 cm at cranial pole) (0.69 cm at caudal pole) (2.02 cm in length); normal shape; homogenous parenchyma. The glandular echogenicity and detail are unremarkable. Capsule, cortex, and medullary definition are normal. The phrenicoabdominal vein and surrounding vasculature are normal.

The right adrenal gland is upper limits of normal size (0.93 cm at cranial pole) (0.56 cm at caudal pole) (1.63 cm in length); normal shape; homogenous parenchyma. The glandular echogenicity and detail are unremarkable. Capsule, cortex, and medullary definition are normal. The phrenicoabdominal vein and surrounding vasculature are normal.

Spleen

The spleen is normal in size (1.00 cm in width at the level of the hilus) with a normal capsular contour. There is appropriate echogenicity and echotexture. No focal lesions are observed. Splenic vasculature is normal.

Liver

The liver is subjectively normal in size with normal curvilinear peripheral contours. The parenchyma is hypoechoic relative to the spleen. One-two small (0.82 cm), ill-defined hypoechoic nodules/areas are visualized. The parenchyma is otherwise homogenous. Hepatic vasculature and intrahepatic biliary tracts are of normal volume with no evidence of congestion.

The gall bladder lumen is moderately distended. The wall is thin and smooth. A small to moderate amount of echogenic to mineralized, gravity dependent debris/sludge is observed within the lumen. The cystic and common bile ducts are normal.



PATIENT

Norman Livingston

SPECIES

Canine

BREED

Dachshund

SEX

Neutered Male

AGE

13 years

WEIGHT

13 lbs

INTERPRETED BY

Andrea Nicastrò,
DVM, Diplomate ACVIM
(Small Animal Internal
Medicine)

IMAGING PERFORMED BY

Crystal Hill

HOSPITAL NAME

Nelson AH

REFERRING VET

Dr. Anderson

INVOICE

10707

DATE

4/7/22

Gastrointestinal

The gastric lumen is mildly distended. The gastric wall and pylorus are normal in thickness with a normal layering pattern. The pyloric outflow tract appears patent. The small intestinal lumen is not dilated. The small intestinal wall thickness is normal with a normal layering pattern and appropriate mural detail. Discreet masses are not identified. The colonic wall is normal. No obstructive or overt infiltrative disease is noted.

Pancreas

The region of the pancreas is isoechoic relative to surrounding omental fat. No obvious parenchymal abnormalities are observed. There is no evidence of regional inflammation or effusion.

Free Abdomen

The peritoneal cavity is normal. There is no evidence of inflammation or effusion. The abdominal lymph nodes are normal/not visible.

ULTRASONOGRAPHIC FINDINGS

Primary Findings

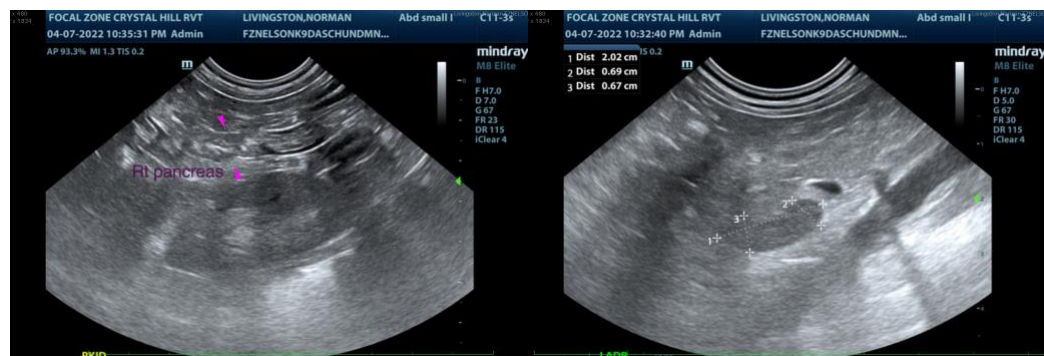
- An obvious cause for the patient's elevated liver values is not identified in this study. However, given the liver enzyme pattern, a benign hepatopathy (i.e., regenerative nodular hyperplasia and/or vacuolar hepatopathy) is suspected.
- Gall bladder debris/sludge, non-mucocele

Secondary Findings

- Borderline bilateral adrenomegaly

INTERPRETATION OF THE FINDINGS & FURTHER RECOMMENDATIONS

- If the patient develops clinical signs for Cushing's Disease, further testing (i.e., low-dose-dexamethasone suppression test or ACTH stimulation test) may be warranted. In the meantime, serial monitoring (i.e., every 3-4 months) of the patient's liver values is recommended. If values continue to increase, a repeat abdominal ultrasound +/- a more advanced hepatic work-up may be warranted.





PATIENT

Norman Livingston

SPECIES

Canine

BREED

Dachshund

SEX

Neutered Male

AGE

13 years

WEIGHT

13 lbs

INTERPRETED BY

Andrea Nicastro,
DVM, Diplomate ACVIM
(Small Animal Internal
Medicine)

**IMAGING
PERFORMED BY**

Crystal Hill

HOSPITAL NAME

Nelson AH

REFERRING VET

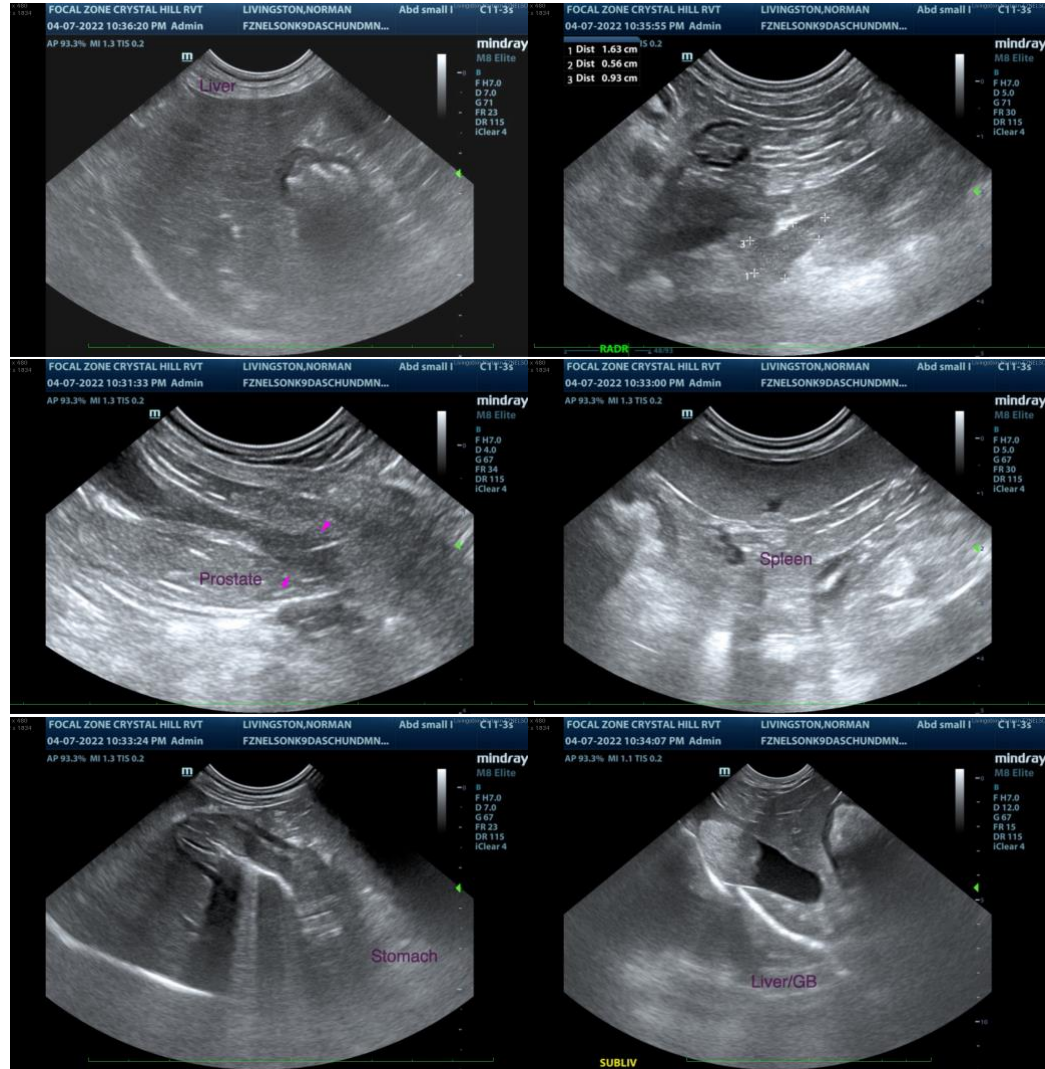
Dr. Anderson

INVOICE

10707

DATE

4/7/22



The information and recommendations provided are based on the images presented by the referring veterinarian/sonographer. No evaluation can be communicated regarding pathology that was not visible in the image/video clips provided.

Thank you for this referral. If the clinical or image interpretation does not parallel your findings or if I can be of any further assistance, please contact me.

Andrea Nicastro, DVM, Diplomate DACVIM (Small Animal Internal Medicine)
info@SonoPath.com