

## PATIENT

Mogli Kuntz

## SPECIES

Canine

## BREED

Boxer

## SEX

Intact Male

## AGE

1 year

## WEIGHT

22.7 kg

## INTERPRETED BY

Andrea Nicastro, DVM,  
Diplomate ACVIM  
(Small Animal Internal  
Medicine)

## IMAGING PERFORMED BY

Crystal Hill

## HOSPITAL NAME

Beatties E Hamilton  
PH

## REFERRING VET

Dr. MacDonald

## INVOICE

10708

## DATE

4/7/22

## PRESENTING CLINICAL SIGNS

History: chronic intermittent vomiting and diarrhea. NSF on P. Has been on Cerenia.  
Abnormal PE/Chem/CBC/UA Results: N/A

## ULTRASONOGRAPHIC EXAMINATION OF THE ABDOMEN

### Urinary System

The urinary bladder, trigone, and pelvic urethra are normal in thickness and the mucosal surface is smooth. The bladder lumen is moderately distended with mostly anechoic urine. No masses, inflammatory changes or calculi are observed. Ureteral papillae and visualized portion of the proximal urethra, visible to a depth of 1 cm, are normal.

The prostate is not definitively visualized due to its pelvic location.

The left kidney presented normal size (6.09 cm in length); normal shape and architecture with smooth peripheral margins. There is a normal 1:3 cortex to medulla ratio with normal corticomedullary distinction. There is no evidence of pyelectasia, nephroliths, infarcts or hydronephrosis. Renal vasculature is normal.

The right kidney presented normal size (5.55 cm in length); normal shape and architecture with smooth peripheral margins. There is a normal 1:3 cortex to medulla ratio with normal corticomedullary distinction. There is no evidence of pyelectasia, nephroliths, infarcts or hydronephrosis. Renal vasculature is normal.

### Adrenal Glands

The left adrenal gland is normal size (0.47 cm at cranial pole) (0.46 cm at caudal pole) (2.14 cm in length); normal shape; homogenous parenchyma. The glandular echogenicity and detail are unremarkable. Capsule, cortex, and medullary definition are normal. The phrenicoabdominal vein and surrounding vasculature are normal.

The right adrenal gland is normal size (1.07 cm at cranial pole) (0.70 cm at caudal pole) (1.76 cm in length); normal shape; homogenous parenchyma. The glandular echogenicity and detail are unremarkable. Capsule, cortex, and medullary definition are normal. The phrenicoabdominal vein and surrounding vasculature are normal.

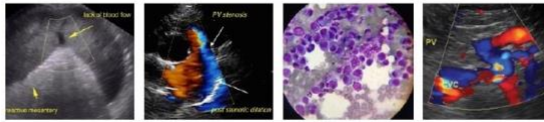
### Spleen

The spleen is normal in size (0.84 cm in width at the level of the hilus) with a normal capsular contour. There is appropriate echogenicity and echotexture. No focal lesions are observed. Splenic vasculature is normal.

### Liver

The liver is subjectively normal in size with normal contours and structure. There is appropriate echogenicity and echotexture. No overt structural evidence of inflammatory, infiltrative or regenerative pathology is evident. Vascular and biliary tracts are of normal volume with no evidence of congestion. No pathological hepatic lymphadenopathy observed.

The gall bladder lumen is moderately distended. The wall is thin and smooth. Luminal contents are anechoic. The cystic and common bile ducts are normal.



**PATIENT**

Mogli Kuntz

**SPECIES**

Canine

**BREED**

Boxer

**SEX**

Intact Male

**AGE**

1 year

**WEIGHT**

22.7 kg

**INTERPRETED BY**

Andrea Nicastro, DVM,  
Diplomate ACVIM  
(Small Animal Internal  
Medicine)

**IMAGING  
PERFORMED BY**

Crystal Hill

**HOSPITAL NAME**

Beatties E Hamilton  
PH

**REFERRING VET**

Dr. MacDonald

**INVOICE**

10708

**DATE**

4/7/22

**Gastrointestinal**

The stomach and intestine are free of stasis and exhibit normal peristaltic activity. The gastric lumen is not distended. The gastric wall and pylorus are normal in thickness with a normal layering pattern. The small intestinal lumen is not dilated. The small intestinal wall thickness is normal with a normal layering pattern and appropriate mural detail. Discreet masses are not identified. The colonic wall is normal. No obstructive or overt infiltrative disease is noted.

**Pancreas**

The region of the pancreas is isoechoic relative to surrounding omental fat. No obvious parenchymal abnormalities are observed. There is no evidence of regional inflammation or effusion.

**Free Abdomen**

The peritoneal cavity is normal. There is no evidence of inflammation or effusion. The abdominal lymph nodes are normal/not visible.

**Other**

The left testicle measures 3.50 x 2.36 cm.

The right testicle measures 3.31 x 2.25 cm.

The testicles are subjectively normal in size, symmetrical, with homogenous parenchyma. No obvious pathology is observed

**ULTRASONOGRAPHIC FINDINGS**

**Primary Findings**

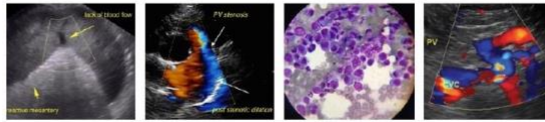
- Unremarkable abdomen.

\*\*An obvious cause for the patient's chronic GI signs is not identified in this study. Considerations include microscopic gastrointestinal disease, underlying metabolic issue (i.e., hypoadrenocorticism), low-grade pancreatitis, other.

**INTERPRETATION OF THE FINDINGS & FURTHER RECOMMENDATIONS**

The following diagnostics/treatment recommendations can be considered:

1. Serum cobalamin, folate, PLI and TLI
2. A fecal evaluation for ova/Giardia
3. Prophylactic deworming with Fenbendazole at 50 mg/kg once a day for 5 days is recommended. Repeat above protocol in 3 weeks.
4. A 6-week limited antigen diet trial to assess for food allergies.
5. Consider a 4-week course of Tylosin as empirical treatment for small intestinal bacterial overgrowth.
6. A resting cortisol level to screen for hypoadrenocorticism. If resting cortisol level is < 2.0 mcg/dL, an ACTH stimulation test is recommended.



**PATIENT**

Mogli Kuntz

**SPECIES**

Canine

**BREED**

Boxer

**SEX**

Intact Male

**AGE**

1 year

**WEIGHT**

22.7 kg

**INTERPRETED BY**

Andrea Nicastro, DVM,  
Diplomate ACVIM  
(Small Animal Internal  
Medicine)

**IMAGING  
PERFORMED BY**

Crystal Hill

**HOSPITAL NAME**

Beatties E Hamilton  
PH

**REFERRING VET**

Dr. MacDonald

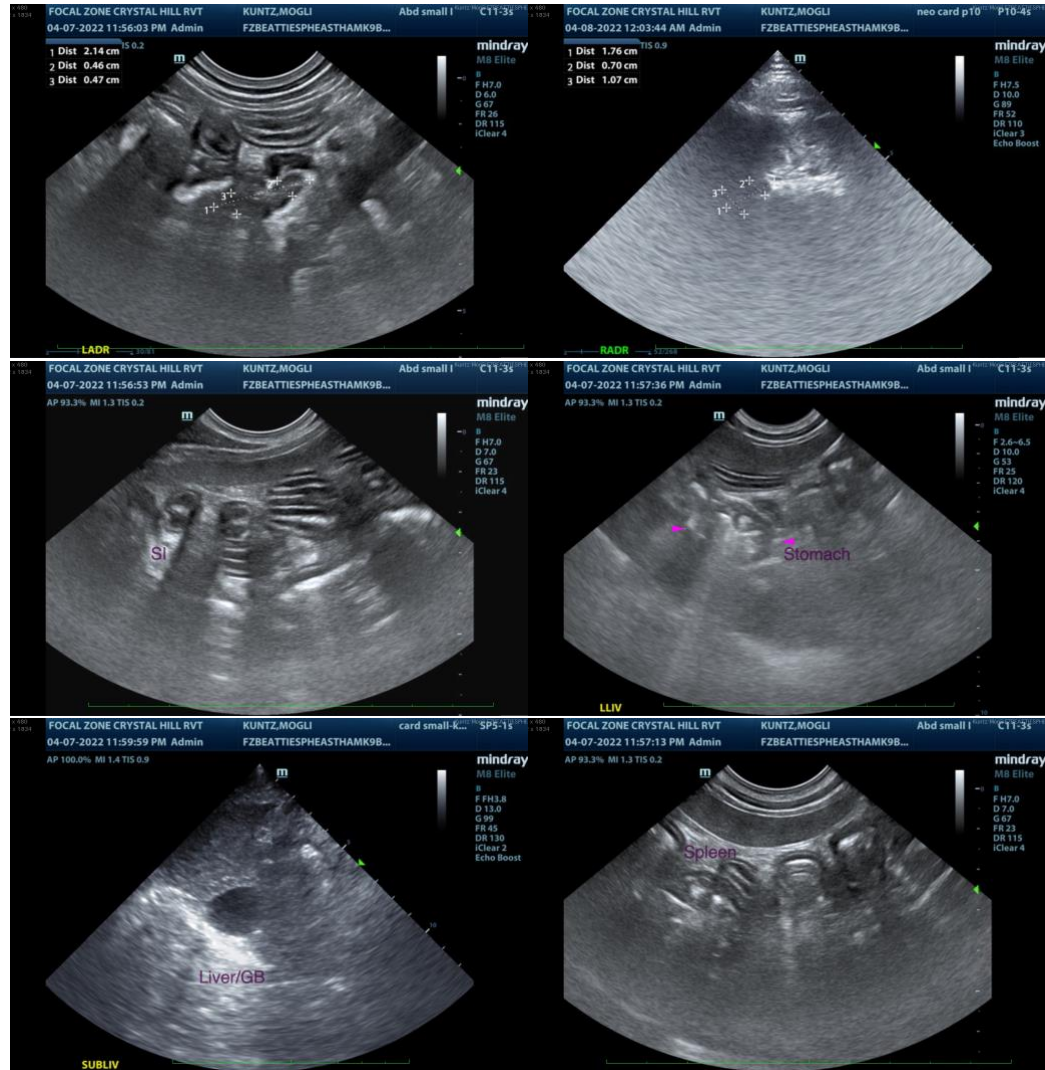
**INVOICE**

10708

**DATE**

4/7/22

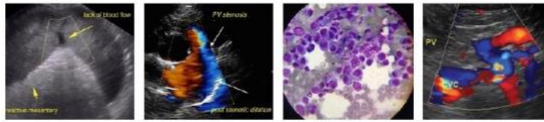
7. Consider pre-and postprandial serum bile acids to assess for occult hepatic dysfunction.
8. Depending on the results of the above diagnostics/therapeutics, endoscopic or surgical gastrointestinal biopsies may be warranted.



The information and recommendations provided are based on the images presented by the referring veterinarian/sonographer. No evaluation can be communicated regarding pathology that was not visible in the image/video clips provided.

Thank you for this referral. If the clinical or image interpretation does not parallel your findings or if I can be of any further assistance, please contact me.

**Andrea Nicastro, DVM, Diplomate DACVIM (Small Animal Internal Medicine)**  
info@SonoPath.com



## PATIENT

Mogli Kuntz

## SPECIES

Canine

## BREED

Boxer

## SEX

Intact Male

## AGE

1 year

## WEIGHT

22.7 kg

## INTERPRETED BY

Andrea Nicastro, DVM,  
Diplomate ACVIM  
(*Small Animal Internal  
Medicine*)

## IMAGING PERFORMED BY

Crystal Hill

## HOSPITAL NAME

Beatties E Hamilton  
PH

## REFERRING VET

Dr. MacDonald

## INVOICE

10708

## DATE

4/7/22