

**PATIENT**

Missy Crotty

**SPECIES**

Canine

**BREED**

Mixed K9FS

**SEX**

Spayed Female

**AGE**

10 years

**WEIGHT**

11.2 lbs

**INTERPRETED BY**

Andrea Nicastro,  
DVM, Diplomate  
ACVIM (Small Animal  
Internal Medicine)

**IMAGING  
PERFORMED BY**

Kelly Vazquez

**HOSPITAL NAME**

Ringwood AH

**REFERRING VET**

Dr. Wilkes

**INVOICE**

10705

**DATE**

4/7/22

**PRESENTING CLINICAL SIGNS**

History: Pet is being treated for proteinuria, new liver enzyme elevation on blood work. Current meds: Benazapril.

Abnormal PE/Chem/CBC/UA Results: K 5.5, N:K 26, ALT 835, ALP 466, GGT 23, cholesterol 442, platelets 653. U/A: UPC 2.1, 3+ protein, USG 1.023.

**ULTRASONOGRAPHIC EXAMINATION OF THE ABDOMEN**

**Urinary System**

The urinary bladder, trigone, and pelvic urethra are normal in thickness and the mucosal surface is smooth. The bladder lumen is moderately distended with mostly anechoic urine. No masses, inflammatory changes or calculi are observed. Ureteral papillae and visualized portion of the proximal urethra, visible to a depth of 1 cm, are normal.

The left kidney presented normal size (3.56 cm in length); normal shape and architecture with smooth peripheral margins. There is a normal 1:3 cortex to medulla ratio with minimal to mild loss of corticomedullary distinction. There is no evidence of pyelectasia, nephroliths, infarcts or hydroureter. Renal vasculature is normal.

The right kidney presented normal size (3.98 cm in length); normal shape and architecture with smooth peripheral margins. There is a normal 1:3 cortex to medulla ratio with minimal to mild loss of corticomedullary distinction. A small cortical cyst is observed at the lateral aspect. There is no evidence of pyelectasia, nephroliths, infarcts or hydroureter. Renal vasculature is normal.

**Adrenal Glands**

The left adrenal gland is normal size (0.42 cm at cranial pole) (0.45 cm at caudal pole) (1.74 cm in length); normal shape; homogenous parenchyma. The glandular echogenicity and detail are unremarkable. Capsule, cortex, and medullary definition are normal. The phrenicoabdominal vein and surrounding vasculature are normal.

The right adrenal gland is normal size (0.97 cm at cranial pole) (0.58 cm at caudal pole) (1.90 cm in length); normal shape; homogenous parenchyma. The glandular echogenicity and detail are unremarkable. Capsule, cortex, and medullary definition are normal. The phrenicoabdominal vein and surrounding vasculature are normal.

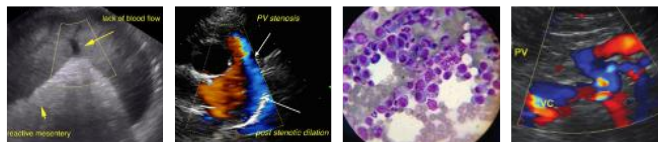
**Spleen**

The spleen is normal in size (1.34 cm in width at the level of the hilus) with a normal capsular contour. There is appropriate echogenicity and echotexture. No focal lesions are observed. Splenic vasculature is normal.

**Liver**

The liver is normal to slightly prominent in size with normal curvilinear peripheral contours. The parenchyma is hypoechoic relative to the spleen and subtly mottled in appearance. No focal lesions are observed. Hepatic vasculature and intrahepatic biliary tracts are of normal volume with no evidence of congestion. The portal vein to caudal vena cava ratio is approximately 1: 1.

The gall bladder lumen is moderately distended. The wall is thin and smooth. Luminal contents are anechoic. The cystic and common bile ducts are normal.



## PATIENT

Missy Crotty

## SPECIES

Canine

## BREED

Mixed K9FS

## SEX

Spayed Female

## AGE

10 years

## WEIGHT

11.2 lbs

## INTERPRETED BY

Andrea Nicastro,  
DVM, Diplomate  
ACVIM (Small Animal  
Internal Medicine)

## IMAGING PERFORMED BY

Kelly Vazquez

## HOSPITAL NAME

Ringwood AH

## REFERRING VET

Dr. Wilkes

## INVOICE

10705

## DATE

4/7/22

### Gastrointestinal

The stomach and intestine are free of stasis and exhibit normal peristaltic activity. The gastric lumen is not distended. The gastric wall and pylorus are normal in thickness with a normal layering pattern. The small intestinal lumen is not dilated. The small intestinal wall thickness is normal with a normal layering pattern and appropriate mural detail. Discreet masses are not identified. The colonic wall is normal. No obstructive or overt infiltrative disease is noted.

### Pancreas

The region of the pancreas is isoechoic relative to surrounding omental fat. No obvious parenchymal abnormalities are observed. There is no evidence of regional inflammation or effusion.

### Free Abdomen

The peritoneal cavity is normal. There is no evidence of inflammation or effusion. The abdominal lymph nodes are normal/not visible.

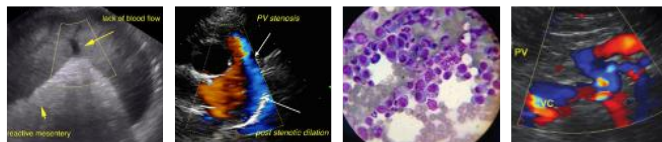
## ULTRASONOGRAPHIC FINDINGS

### Primary Findings

- Nonspecific diffuse hepatopathy. Differentials include inflammatory disease (i.e., bacterial cholangiohepatitis, chronic active hepatitis), Leptospirosis, hepatotoxicosis, infiltrative neoplasia (less likely), other hepatopathy.
- Bilateral nonspecific renal changes. Given the history of proteinuria, a protein-losing nephropathy is likely.

## INTERPRETATION OF THE FINDINGS & FURTHER RECOMMENDATIONS

- Regarding the elevated liver enzymes, pre- and postprandial serum bile acids, Leptospirosis testing (i.e., blood and urine PCR), and hepatic tissue sampling (i.e., fine-needle aspirate or surgical biopsy) are recommended. Surgical biopsies are more likely to yield a definitive diagnosis. If surgery is pursued, acquisition of additional hepatic tissue samples for potential copper quantitation, along with aerobic and anaerobic bile cultures are recommended.
- If a more conservative approach is pursued, consider empirical treatment for bacterial cholangiohepatitis/Leptospirosis with amoxicillin-clavulanic acid +/- metronidazole, Denamarin) along with supportive care, as needed. If the liver enzymes do not improve within 5-7 days of initiation of therapy antibiotics should be discontinued and a more advanced liver work-up reconsidered. If the patient is to undergo anesthesia at any point, three-view thoracic radiographs are recommended to evaluate cardiopulmonary status.
- Regarding the protein-losing nephropathy, consider the following diagnostic/therapeutic options
  1. Omega 3 fatty acids
  2. Anti-thrombotic agent (i.e., clopidogrel)
  3. Baseline blood pressure measurement
  4. Prescription renal diet
  5. Also consider advanced infectious disease testing (i.e., tick-borne, heartworm)
  6. Serial monitoring of the patient's renal values, blood pressure and UPC to assess for progression of disease



**PATIENT**

Missy Crotty

**SPECIES**

Canine

**BREED**

Mixed K9FS

**SEX**

Spayed Female

**AGE**

10 years

**WEIGHT**

11.2 lbs

**INTERPRETED BY**

Andrea Nicastro,  
DVM, Diplomate  
ACVIM (Small Animal  
Internal Medicine)

**IMAGING  
PERFORMED BY**

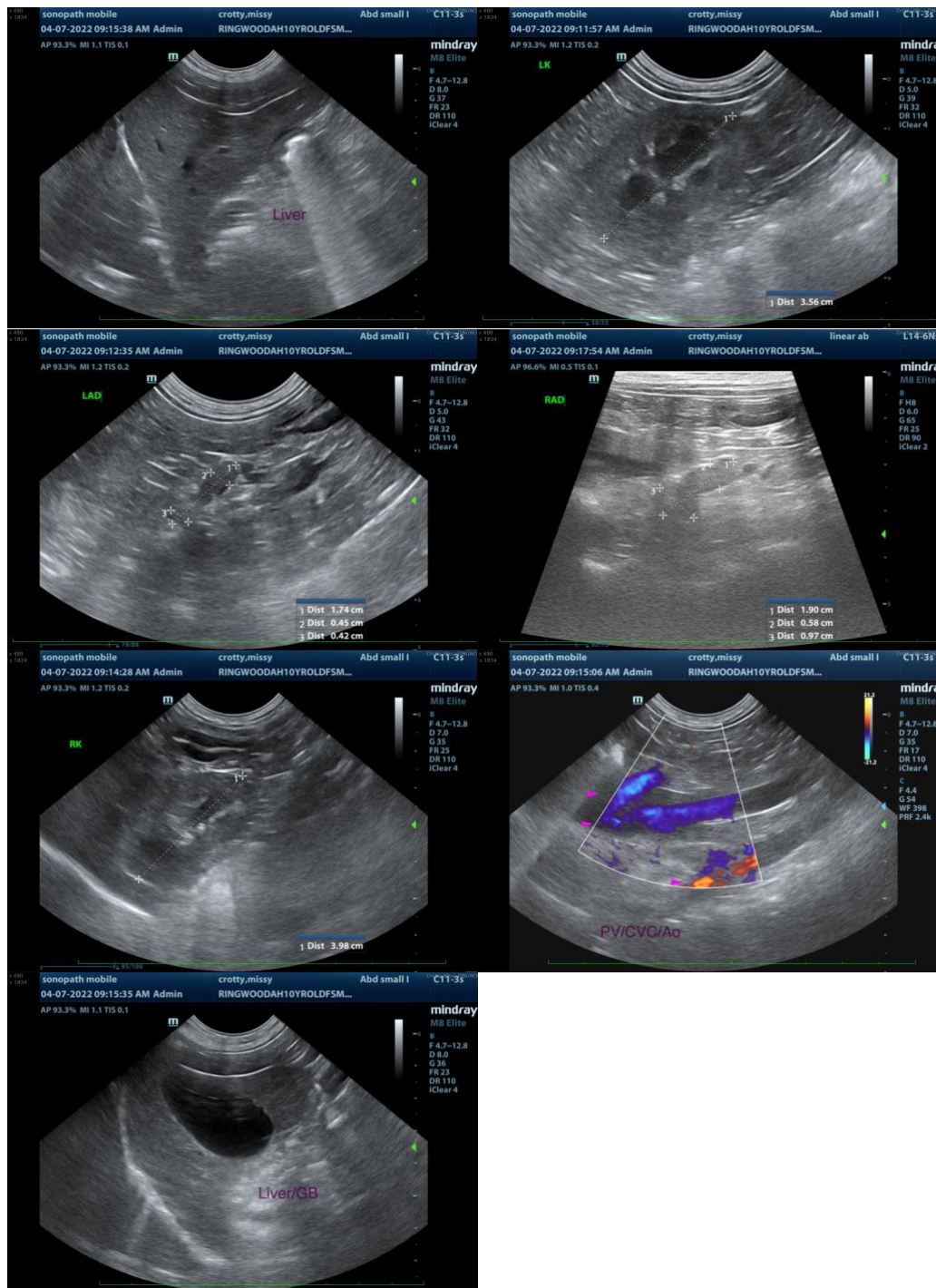
Kelly Vazquez

**HOSPITAL NAME**

Ringwood AH

**REFERRING VET**

Dr. Wilkes



**INVOICE**

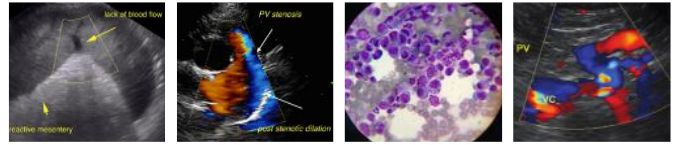
10705

**DATE**

4/7/22

The information and recommendations provided are based on the images presented by the referring veterinarian/sonographer. No evaluation can be communicated regarding pathology that was not visible in the image/video clips provided.

Thank you for this referral. If the clinical or image interpretation does not parallel your findings or if I



**PATIENT**

can be of any further assistance, please contact me.

Missy Crotty

**Andrea Nicastro**, DVM, Diplomate DACVIM (Small Animal Internal Medicine)  
info@SonoPath.com

**SPECIES**

Canine

**BREED**

Mixed K9FS

**SEX**

Spayed Female

**AGE**

10 years

**WEIGHT**

11.2 lbs

**INTERPRETED BY**

Andrea Nicastro,  
DVM, Diplomate  
ACVIM (*Small Animal  
Internal Medicine*)

**IMAGING  
PERFORMED BY**

Kelly Vazquez

**HOSPITAL NAME**

Ringwood AH

**REFERRING VET**

Dr. Wilkes

**INVOICE**

10705

**DATE**

4/7/22