



## PATIENT

Tiggy Gordon

## SPECIES

Feline

## BREED

DSH

## SEX

Spayed Female

## AGE

12 years, 1 mo

## WEIGHT

12.90 lbs

## INTERPRETED BY

Andrea Nicastro, DVM,  
Diplomate ACVIM (*Small  
Animal Internal Medicine*)

## IMAGING PERFORMED BY

Andrea Nicastro, DVM,  
Diplomate ACVIM (*Small  
Animal Internal Medicine*)

## HOSPITAL NAME

Salt Marsh AH

## REFERRING VET

Christi Wiles

## INVOICE

12672

## DATE

4.6.23

## PRESENTING CLINICAL SIGNS

History of barbering, with hair loss in the ventral abdomen. Bloodwork has been unremarkable. Has been on corticosteroids, but no improvement.

## ULTRASONOGRAPHIC EXAMINATION OF THE ABDOMEN

### Urinary System

The urinary bladder wall is normal in thickness and the mucosal surface is smooth. The bladder is moderately distended. Luminal contents are anechoic. No cystic calculi are observed. The region of the trigone and the proximal urethra, visible to a depth of 2 cm, are normal.

The left kidney is normal in size (3.96 cm in length) with a normal shape, architecture and smooth peripheral margins. There is a normal 1:3 cortex to medulla ratio with mild loss of corticomedullary distinction. There is no evidence of pyelectasia, nephroliths, infarcts or hydronephrosis. Renal vasculature is normal. Surrounding mesentery is mildly hyperechoic.

The right kidney is normal in size (4.25 cm in length) with a normal shape, architecture and smooth peripheral margins. There is a normal 1:3 cortex to medulla ratio with mild loss of corticomedullary distinction. There is no evidence of pyelectasia, nephroliths, infarcts or hydronephrosis. Renal vasculature is normal. Surrounding mesentery is mildly hyperechoic.

### Adrenal Glands

The left adrenal gland is normal size (0.26 cm width). Normal shape and glandular echogenicity. The phrenicoabdominal vein and surrounding vasculature are normal.

The right adrenal gland is normal size (0.33 cm width). Normal shape and glandular echogenicity. The phrenicoabdominal vein and surrounding vasculature are normal.

### Spleen

The spleen is normal in size (0.95 cm in width at the level of the hilus) with a normal capsular contour. There is appropriate echogenicity and echotexture. No focal lesions are observed. Splenic vasculature is normal.

### Liver

The liver is subjectively normal in size with normal contours and structure. There is appropriate echogenicity and echotexture. No overt structural evidence of inflammatory, infiltrative, or regenerative pathology is evident. Vascular and biliary tracts are of normal volume with no evidence of congestion. No pathological hepatic lymphadenopathy observed.

The gall bladder lumen is moderately distended. The wall is thin and smooth. Luminal contents are anechoic. The cystic and common bile ducts are normal/not seen.

### Gastrointestinal

The gastric lumen is mildly distended with ingesta. The gastric wall and pylorus are normal in thickness with a normal layering pattern. The pyloric outflow tract is patent. The small intestinal lumen is not dilated. The small intestinal wall thickness is normal with a normal layering pattern and appropriate mural detail. There is slight disruption in the normal 1:3 muscularis: mucosal ratio in several segments. Discreet masses are not identified. The ileocecal colic junction and colonic wall are normal. No obstructive disease is noted.

### Pancreas

The pancreas is normal in size with normal peripheral contours. The pancreatic duct is normal. The base and limbs of the pancreas are isoechoic to surrounding omental fat. No focal lesions are observed. There is

no evidence of peripancreatic inflammation or effusion.

### **Free Abdomen**

There is no obvious evidence of free fluid. The abdominal lymph nodes are normal/not visible.

### **Other**

A brief echocardiogram reveals no evidence of pericardial effusion or obvious right atrial/auricular mass.

## **ULTRASONOGRAPHIC FINDINGS**

### **Primary Findings**

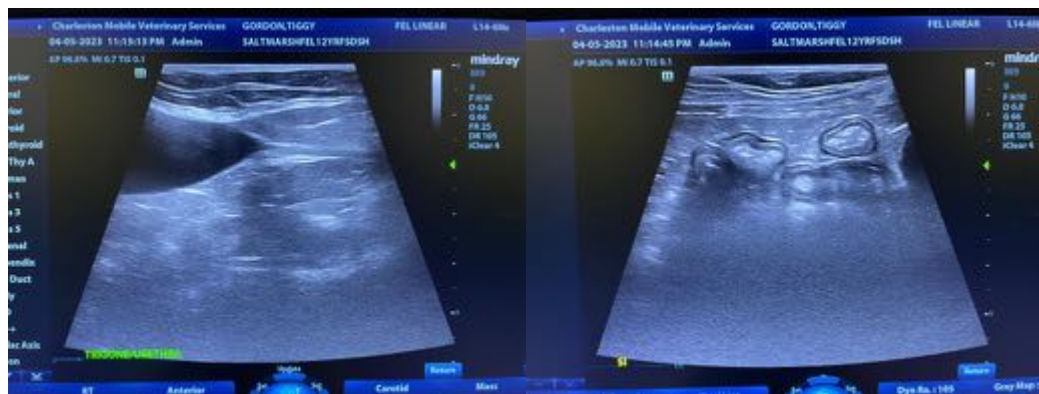
- Bilateral chronic nonspecific age-related renal changes. There is evidence of retroperitonitis cranially surrounding both kidneys. This may be secondary to renal inflammation/infection, or less likely, emerging neoplasia.

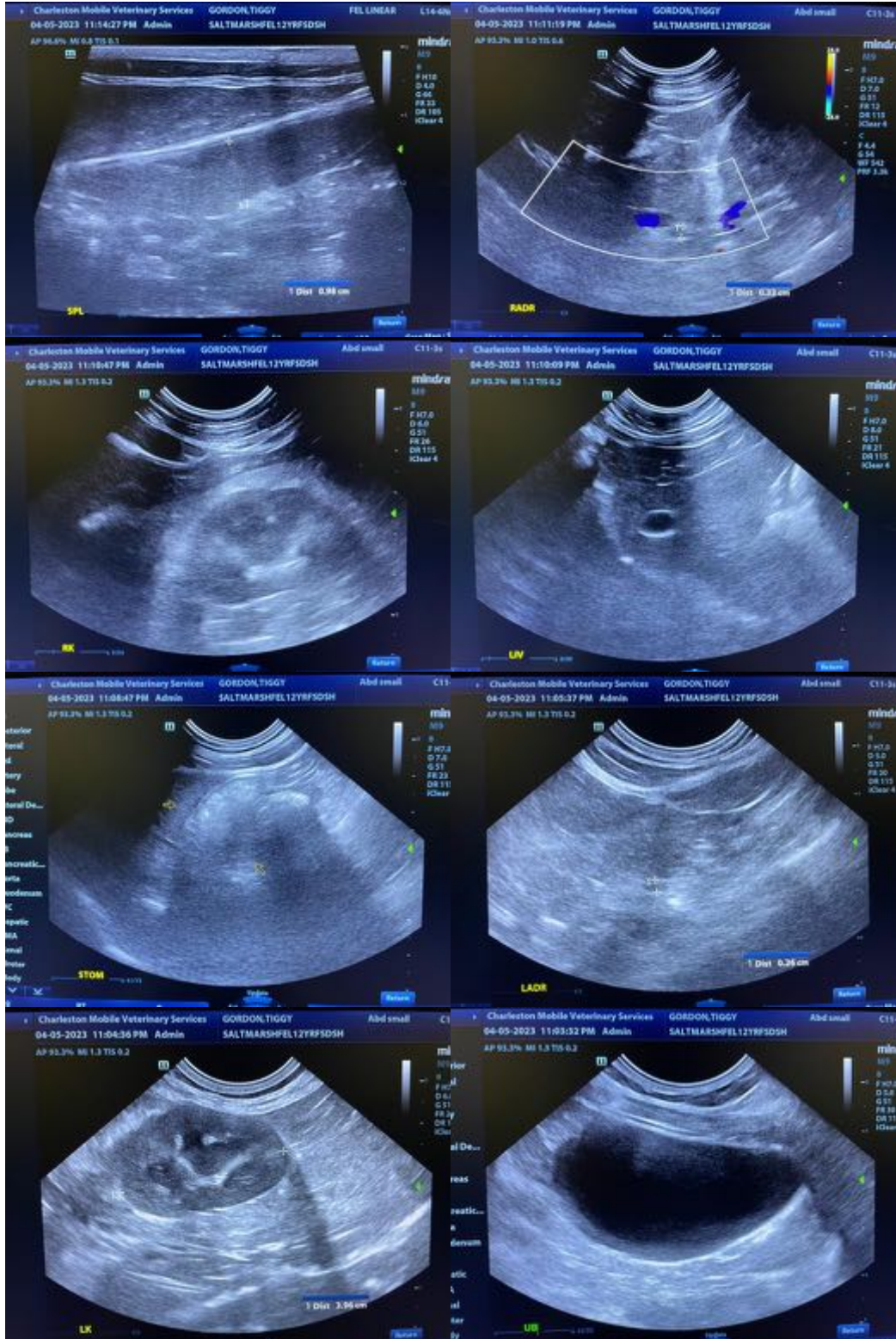
### **Secondary Findings**

- The small intestinal wall changes could be consistent with inflammatory bowel disease. However, correlation with the patient's clinical history is recommended.

## **INTERPRETATION OF THE FINDINGS & FURTHER RECOMMENDATIONS**

- Given the bilateral renal changes and the history of barbering, a urinalysis with a culture and sensitivity is recommended to assess for infection.
- Orthopedic and neurologic examinations are also recommended to assess for sources of pain.
- If the above results are negative, consider consultation with a board-certified dermatologist.





**The information and recommendations provided are based on the images presented by the referring veterinarian/sonographer. No evaluation can be communicated regarding pathology that was not visible in the image/video clips provided.**

Thank you for this referral. If the clinical or image interpretation does not parallel your findings or if I can be of any further assistance, please contact me.

**Andrea Nicastro, MPH, DVM, Diplomate DACVIM (Small Animal Internal Medicine)**  
[info@SonoPath.com](mailto:info@SonoPath.com)