



PATIENT PRESENTING CLINICAL SIGNS

Yoshi Abrams History: SQ masses: MCT and STS based on cytology. Staging in anticipation of surgical resection.

SPECIES

Abnormal PE/Chem/CBC/UA Results: SQ masses as noted. No significant abnormalities on CBC, chemistry, T4. Review of thoracic radiographs pending, no overt abnormalities appreciated.

Canine

ULTRASONOGRAPHIC EXAMINATION OF THE ABDOMEN

BREED

Urinary System

Pitbull Terrier Mix

The urinary bladder is moderately distended. The wall is normal in thickness with a smooth mucosal surface. Luminal contents are anechoic. No cystic calculi are observed. A ureterocele is suspected in the region of the trigone, with mild dilation of the distal urether. The visualized portion of the proximal urethra is normal.

SEX

The prostate is enlarged (4.65 cm in width) with a slightly irregular shape. Parenchyma is homogenous with ill-defined hypoechoic fluid-filled pockets. The prostatic urethra is not overtly dilated.

Neutered Male

AGE

The left kidney is subjectively normal in size with a normal shape, smooth peripheral margins, and normal internal architecture. There is mild loss of corticomedullary distinction. Several hyperechoic shadowing diverticular foci are observed. There is no evidence of pyelectasia, infarcts or hydronephrosis. Renal vasculature is normal.

10 years, 11 mos

WEIGHT

The right kidney is normal in size (8.43 cm in length) with a normal shape, smooth peripheral margins, and normal internal architecture. There is mild loss of corticomedullary distinction. Several hyperechoic shadowing diverticular foci are observed. There is no evidence of pyelectasia, infarcts or hydronephrosis. Renal vasculature is normal.

70.8 lbs

Adrenal Glands

INTERPRETED BY

The left adrenal gland is normal in size (0.74 cm at cranial pole) (0.71 cm at caudal pole) with a normal shape and homogenous parenchyma. The glandular echogenicity and detail are unremarkable. Capsule, cortex, and medullary definition are normal. The phrenicoabdominal vein and surrounding vasculature appear normal.

Andrea Nicastro, DVM,
Diplomate ACVIM
(Small Animal Internal
Medicine)

The caudal pole of the right adrenal gland is visualized and is normal in size (0.48 cm in width) with a normal shape, glandular echogenicity and detail. Surrounding vasculature appear normal.

IMAGING PERFORMED BY

Spleen

Sarah Green

The spleen is overall normal in size (1.90 cm in width at the level of the hilus) with a slightly irregular shape. A >4.00 cm hypoechoic-to-heterogenous slightly cavitated mass is observed at the lateral aspect. The lesion causes capsular expansion. There is appropriate echogenicity and echotexture. No focal lesions are observed. Splenic vasculature appears normal.

HOSPITAL NAME

Healing Spirit Animal
Wellness

Liver

REFERRING VET

Sarah Green

The liver is subjectively prominent in size with normal curvilinear peripheral contours. The parenchyma is hypoechoic relative to the spleen. A 0.74 cm hypoechoic nodule is observed deep on the left side. The remaining parenchyma is homogenous. Hepatic vasculature and intrahepatic biliary tracts are of normal volume with no evidence of congestion.

INVOICE

The gall bladder lumen is moderately distended. The wall is thin and smooth. Luminal contents are anechoic. The cystic and common bile ducts are normal/not seen.

12676

DATE

4.5.23

Gastrointestinal

The stomach and intestine are free of stasis and exhibit normal peristaltic activity. The gastric lumen is not distended. The gastric wall and pylorus are normal in thickness with a normal layering pattern. The pyloric outflow tract is patent. The small intestinal lumen is not dilated. The small intestinal wall is normal in thickness with a normal layering pattern and appropriate mural detail. Discreet masses are not identified. The colonic wall is normal. There is no evidence of an obstructive pattern.

Pancreas

The region of the pancreas is isoechoic relative to surrounding omental fat. No obvious parenchymal abnormalities are observed. There is no evidence of regional inflammation or effusion.

Free Abdomen

The peritoneal cavity is normal. There is no evidence of inflammation or effusion. The abdominal lymph nodes are normal/not visible.

ULTRASONOGRAPHIC FINDINGS

Primary Findings

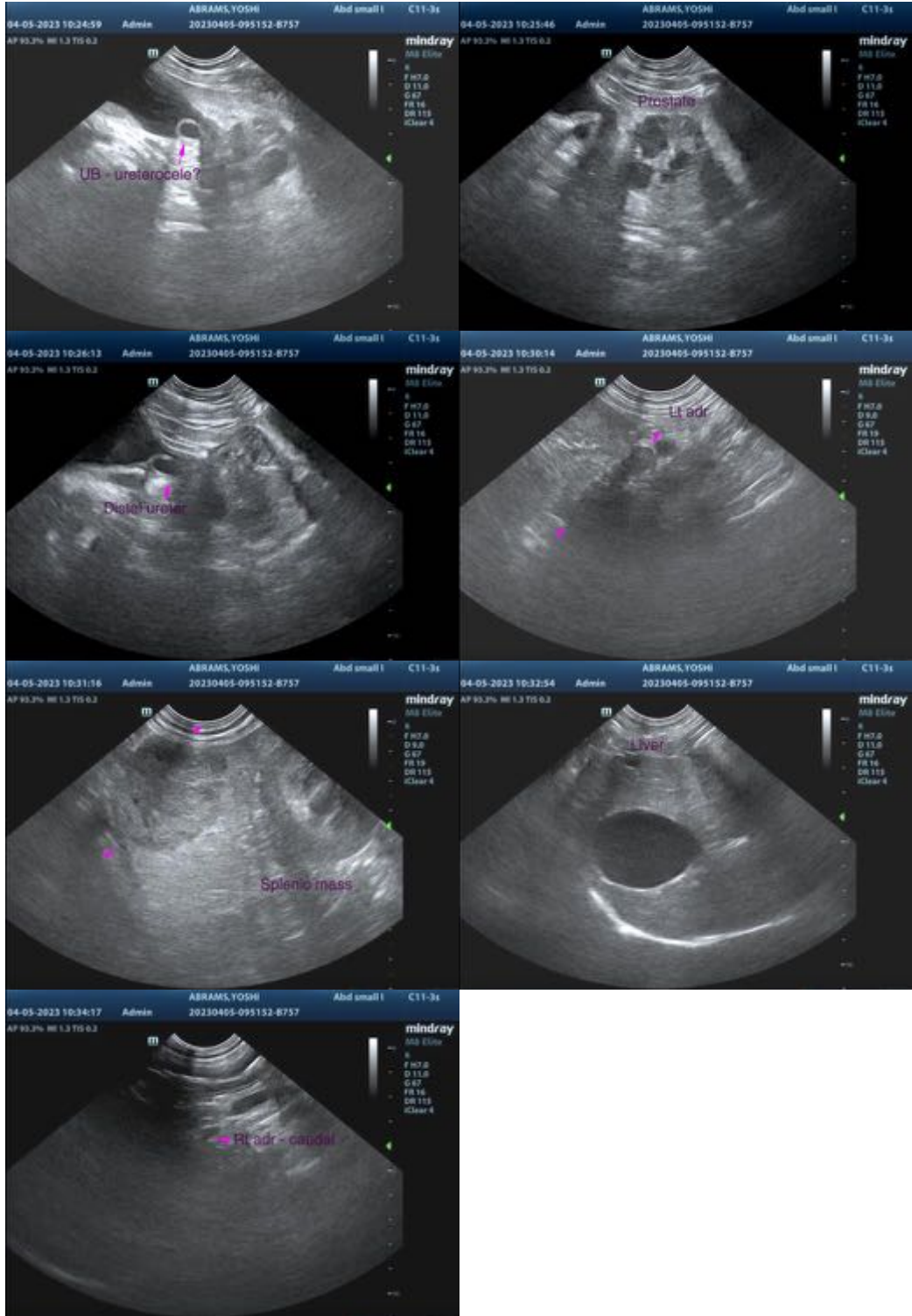
- Splenic mass. Neoplasia (i.e., round cell tumor, sarcoma, other) is suspected with a lower possibility of a benign process (i.e., focus of lymphoid hyperplasia, inflammation, other).
- The prostate changes are concerning for infiltrative neoplasia (i.e., adenocarcinoma, transitional cell carcinoma). A benign process (i.e., prostatitis, hyperplasia) is considered less likely.

Secondary Findings

- Suspected ureterocele, likely an incidental finding
- Minor bilateral age-related renal changes with subtle dystrophic mineralization
- The hypoechoic hepatic nodule trends toward the benign (i.e., focus of lymphoid hyperplasia, regenerative nodular hyperplasia, or similar) with a lower possibility of a metastatic lesion or emerging tumor.

INTERPRETATION OF THE FINDINGS & FURTHER RECOMMENDATIONS

- Regarding the splenic mass, consider a fine-needle aspirate (if clotting status is appropriate). A 25-gauge needle should be used, and the patient should be pretreated with diphenhydramine prior to the procedure to reduce the risk of mast cell degranulation.
- Regarding the prostate changes, consider a urine BRAF test to further evaluate for lower urinary tract neoplasia.



The information and recommendations provided are based on the images presented by the referring veterinarian/sonographer. No evaluation can be communicated regarding pathology that was not visible in the image/video clips provided.

Thank you for this referral. If the clinical or image interpretation does not parallel your findings or if I can be of any further assistance, please contact me.

Andrea Nicastro, MPH, DVM, Diplomate DACVIM (Small Animal Internal Medicine)
info@SonoPath.com