



PATIENT PRESENTING CLINICAL SIGNS

Scout Sanchez History: Patient presents for anorexia. Current meds: Keppra and omeprazole. Abnormal PE/Chem/CBC/UA Results: CBC/Chem: WNL.

SPECIES ULTRASONOGRAPHIC EXAMINATION OF THE ABDOMEN

Canine **Urinary System**

The urinary bladder is minimally to mildly distended with mostly anechoic urine. The wall is diffusely thickened (up to 0.57 cm) with a slightly irregular mucosal surface. No cystic calculi are observed. The region of the trigone and the visualized portion of the proximal urethra are normal.

BREED

Beagle

The prostate is enlarged (2.40 cm in width) with a slightly irregular shape. Parenchyma is hyperechoic relative to surrounding omental fat and mildly heterogenous in appearance, with a few, small ill-defined cystic areas throughout the gland. The prostatic urethra is not overtly dilated.

SEX

Intact Male

The left kidney is normal in size (5.43 cm in length) with a normal shape, architecture and smooth peripheral margins. There is a normal 1:3 cortex to medulla ratio with normal corticomedullary distinction. There is no evidence of pyelectasia, nephroliths, infarcts or hydroureter. Renal vasculature is normal.

AGE

5 years

Right kidney
(No images provided).

WEIGHT

36 lbs

Adrenal Glands

The left adrenal gland is normal in size (0.49 cm at cranial pole) (0.41 cm at caudal pole) with a normal shape and homogenous parenchyma. The glandular echogenicity and detail are unremarkable. Capsule, cortex, and medullary definition are normal. The phrenicoabdominal vein and surrounding vasculature appear normal.

INTERPRETED BY

Andrea Nicastro, DVM,
Diplomate ACVIM
(Small Animal Internal
Medicine)

The right adrenal gland is in normal size (0.45 cm at cranial pole) (0.39 cm at caudal pole) (1.89 cm in length) with a normal shape and homogenous parenchyma. The glandular echogenicity and detail are unremarkable. Capsule, cortex, and medullary definition are normal. The phrenicoabdominal vein and surrounding vasculature appear normal.

IMAGING PERFORMED BY

Kelly Vazquez

Spleen

The spleen is normal in size (1.42 cm in width at the level of the hilus) with a normal capsular contour. The parenchyma is subtly mottled in appearance. No focal lesions are observed. Splenic vasculature appears normal.

HOSPITAL NAME

New Bridge VP

Liver

The liver is subjectively normal in size with normal contours and structure. There is appropriate echogenicity and echotexture. No overt structural evidence of inflammatory, infiltrative, or regenerative pathology is evident. Vascular and biliary tracts are of normal volume with no evidence of congestion. No pathological hepatic lymphadenopathy observed. The portal vein to caudal vena cava ratio is approximately 1: 1.

REFERRING VET

Dr. Abina Glennon

The gall bladder lumen is moderately distended. The wall is thin and smooth. Luminal contents are mostly anechoic. The cystic and common bile ducts are normal/not seen.

INVOICE

12655

Gastrointestinal

The lumen is mildly gas-distended. The gastric wall is normal in thickness with a normal layering pattern. The small intestinal lumen is not dilated. The small intestinal wall thickness is normal with a normal layering

DATE

4.4.23

pattern and appropriate mural detail. Discreet masses are not identified. The colonic wall is normal. There is no evidence of an obstructive pattern.

Pancreas

The region of the pancreas is isoechoic relative to surrounding omental fat. No obvious parenchymal abnormalities are observed. There is no evidence of regional inflammation or effusion.

Free Abdomen

The peritoneal cavity is normal. There is no evidence of inflammation or effusion. The abdominal lymph nodes are normal/not visible.

Other

The testicles are subjectively normal in size (left: 3.46 x 1.63 cm) (right: 3.20 x 1.68 cm) with normal shapes and smooth peripheral contours. The parenchyma is homogenous. No obvious pathology is observed.

Other

A 0.85 cm cystic lesion is observed in the cranial abdomen.

ULTRASONOGRAPHIC FINDINGS

Primary Findings

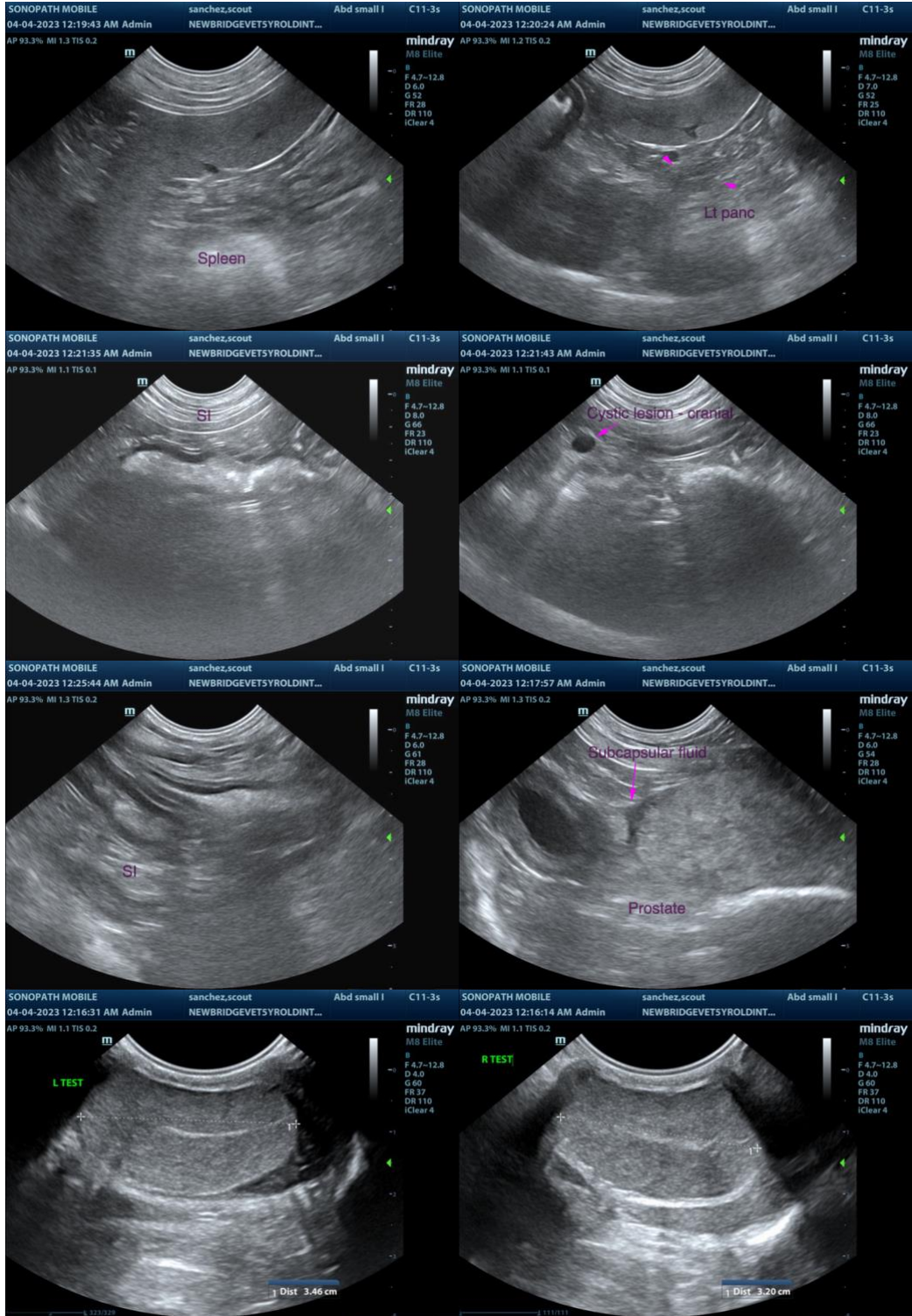
- The prostate changes are most consistent with cystic benign prostatic hyperplasia. The presence of subcapsular fluid is concerning for possible concurrent prostatitis.

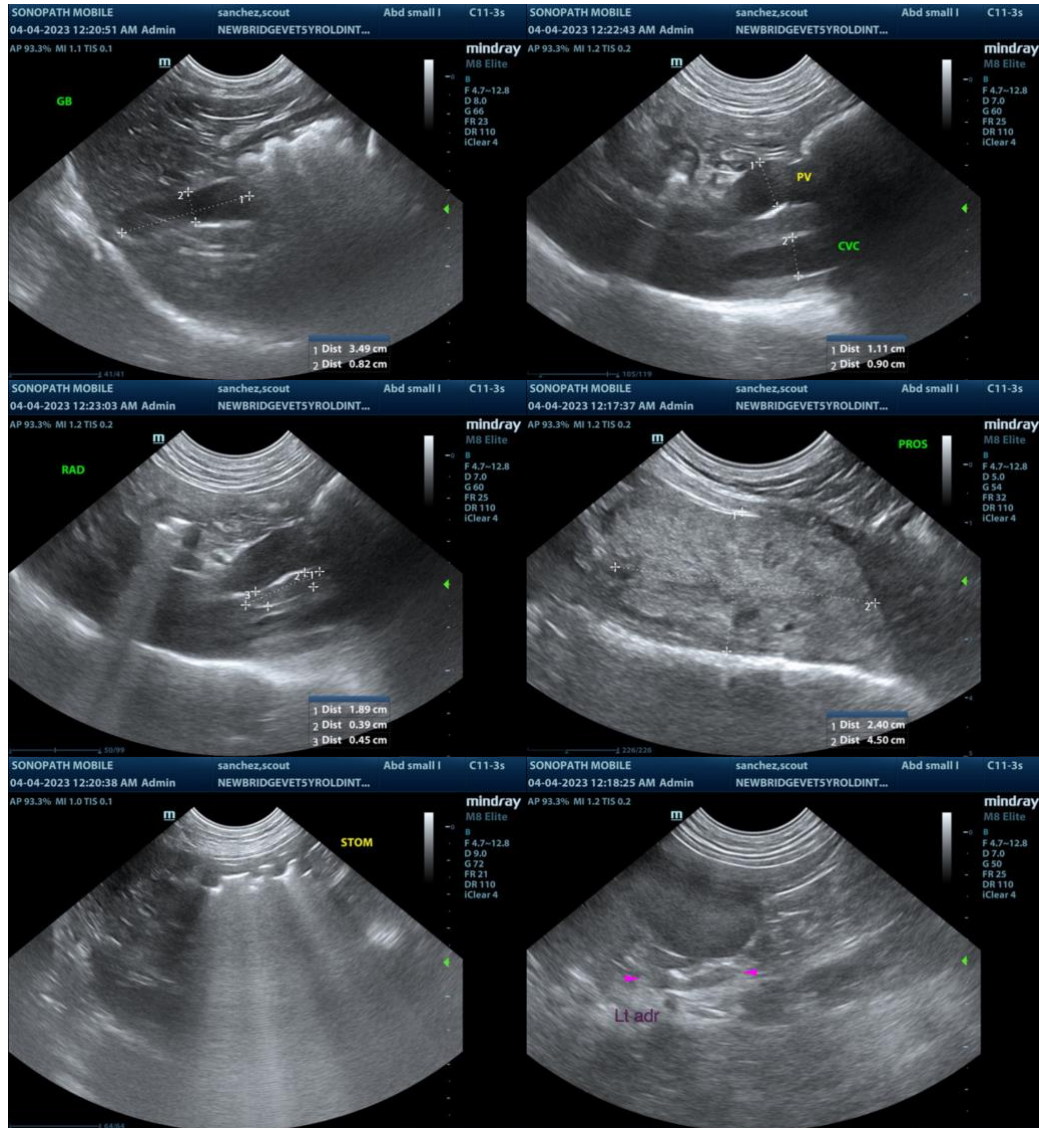
Secondary Findings

- The splenic parenchymal changes are most consistent with a benign process such as lymphoid hyperplasia, extramedullary hematopoiesis, splenitis or antigenic stimulation with a low possibility of infiltrative neoplasia (i.e., lymphoma, mast cell neoplasia).
- The urinary bladder wall changes likely are artifactual due to lack of full repletion. However, cystitis cannot be excluded.
- The origin of the cystic lesion in the cranial abdomen is unclear. It may be arising from the mesentery, lymph node, pancreas, other. A benign process is favored.

INTERPRETATION OF THE FINDINGS & FURTHER RECOMMENDATIONS

- A urinalysis with culture and sensitivity is recommended to further assess for bacterial prostatitis. Also consider a fine-needle aspirate of the prostate, particularly if urine culture and sensitivity results are inconclusive. If the results are inconclusive, a more comprehensive work-up may be warranted and could include the following:
 1. Three-view thoracic radiographs to assess for occult disease in the chest
 2. GI panel including serum cobalamin and folate, TLI, PLI and resting cortisol level
 3. Orthopedic and neurologic examinations to assess for nonmetabolic causes of anorexia
 4. Testing for infectious disease (i.e., tick-borne).





The information and recommendations provided are based on the images presented by the referring veterinarian/sonographer. No evaluation can be communicated regarding pathology that was not visible in the image/video clips provided.

Thank you for this referral. If the clinical or image interpretation does not parallel your findings or if I can be of any further assistance, please contact me.

Andrea Nicastro, MPH, DVM, Diplomate DACVIM (Small Animal Internal Medicine)
info@SonoPath.com