

PATIENT

Medley Hienekamp

PRESENTING CLINICAL SIGNS

History: Recent hx lethargy and decreased appetite Working diagnosis Concern for splenic neoplasia
MEDS Vetprofen 75mg BID

SPECIES

Canine

Abnormal PE/Chem/CBC/UA Results: HCT 35%. Mild elevation ALP. Otherwise, unremarkable. RAD report- Conclusion Normal cardiopulmonary structures. Abdominal visceral abnormalities are not defined. There is no overt abdominal organomegaly or mass lesions. Active G.I. tract

BREED

Labrador Retr

ULTRASONOGRAPHIC EXAMINATION OF THE ABDOMEN

SEX

Female Spayed

Urinary System

The urinary bladder bladder is mildly distended. The wall is mildly thickened (up to 0.70 cm) in the region of the apex, with a slightly irregular mucosal surface in this region. The wall tapers to a normal thickness as it extends towards the cystourethral junction. No cystic calculi are observed. The region of the trigone and the proximal urethra are normal.

AGE

13 years

The left kidney is normal in size (6.35 cm in length) with a normal shape, architecture and smooth peripheral margins. There is a normal 1:3 cortex to medulla ratio with minimal loss of corticomedullary distinction. There is no evidence of pyelectasia, nephroliths, infarcts or hydroureter.

WEIGHT

27 kg

The right kidney is normal in size (6.40 cm in length) with a normal shape, architecture and smooth peripheral margins. There is a normal 1:3 cortex to medulla ratio with minimal loss of corticomedullary distinction. There is no evidence of pyelectasia, nephroliths, infarcts or hydroureter.

INTERPRETED BY

Andrea Nicastro, DVM,
Diplomate ACVIM (*Small
Animal Internal Medicine*)

**IMAGING
PERFORMED BY**

Loetitia Saint-Jacques,
LVT

HOSPITAL NAME

Alpine AH

REFERRING VET

Dr Rachel Zsumel

Adrenal Glands

The left adrenal gland enlarged (2.58 cm at cranial pole) (1.21 cm at caudal pole) (4.64 cm in length) with an irregular shape. A 3.25 x 2.28 cm hyperechoic-to-heterogenous mass is observed at the cranial to mid-aspect, with extension into the caudal pole. The parenchyma in the remainder of the caudal pole is heterogenous. There is loss of glandular detail. Surrounding vasculature appears normal with no obvious evidence of invasion.

The right adrenal gland is in normal size (0.92 cm at cranial pole) (0.53 cm at caudal pole) with an irregular shape. A 1.08 x 0.78 cm hypoechoic nodule is observed approximately mid-gland. The remaining glandular echogenic and detail are normal. Surrounding vasculature appears normal.

Spleen

The spleen is prominent in size (1.92 cm in width at the level of the hilus) with slightly irregular peripheral contours. Numerous, varying-sized, target-like nodules/masses are observed throughout the organ (the largest measuring 3.25 cm in length). The remaining parenchyma is homogenous in appearance. Splenic vasculature appears normal with no evidence of thrombosis.

Liver

The liver is subjectively normal in size with normal contours and structure. There is appropriate echogenicity and echotexture. No overt structural evidence of inflammatory, infiltrative, or regenerative pathology is evident. Vascular and biliary tracts are of normal volume with no evidence of congestion. No pathological hepatic lymphadenopathy observed.

INVOICE

12652

The gall bladder lumen is moderately distended. The wall is thin and smooth. A small amount of aggregated echogenic, gravity-dependent debris is observed within the lumen. The cystic and common bile ducts are normal/not seen.

DATE

4.4.23

Gastrointestinal

The stomach and intestine are free of stasis and exhibit normal peristaltic activity. The gastric lumen is mildly distended with ingesta. The gastric wall and pylorus are normal in thickness with a normal layering pattern. The pyloric outflow tract is patent. The small intestinal lumen is not dilated. The small intestinal wall is normal in thickness with a normal layering pattern and appropriate mural detail. Discreet masses are not identified. The colonic wall is normal. There is no evidence of an obstructive pattern.

Pancreas

The region of the pancreas is isoechoic relative to surrounding omental fat. No obvious parenchymal abnormalities are observed. There is no evidence of regional inflammation or effusion.

Free Abdomen

There is no obvious evidence of free fluid. One to two prominent lymph nodes are observed at the aortic trifurcation (the largest measuring 1.80 cm in length).

Other

A brief echocardiogram reveals no evidence of pericardial effusion or obvious right atrial/auricular mass.

ULTRASONOGRAPHIC FINDINGS

Primary Findings

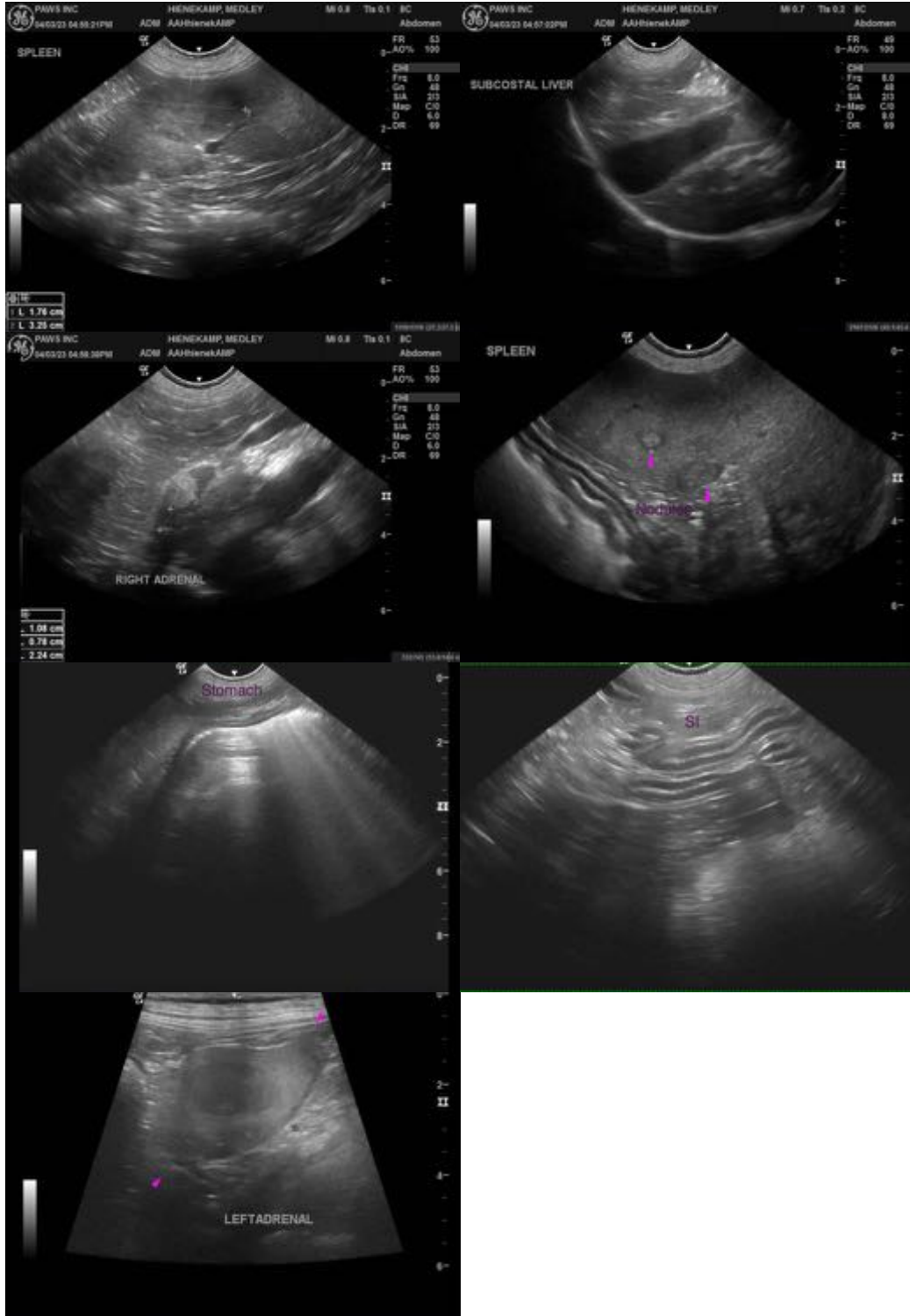
- Multiple splenic nodules/masses. Neoplasia (i.e., round cell tumor, other) is suspected with a lower possibility of a benign process (i.e., multifocal inflammatory disease, foci of lymphoid hyperplasia, other).
- Left adrenal mass. Neoplasia (i.e., adenoma, adenocarcinoma, pheochromocytoma) is favored. However, benign macronodular hyperplasia cannot be excluded. The right adrenal nodule trends toward the benign (i.e., nodular hyperplasia) with a lower possibility of an emerging tumor.

Secondary Findings

- The prominent caudal abdominal lymph nodes are likely reactive.

INTERPRETATION OF THE FINDINGS & FURTHER RECOMMENDATIONS

- Three-view thoracic radiographs are recommended to assess for pulmonary metastases.
- Fine-needle aspirates of the splenic lesions are recommended (if clotting status is appropriate). Twenty-five gauge-needles should be used. If the cytology results are inconclusive, further testing (i.e., PARR, splenectomy with submission of the spleen for histopathology) may be necessary to get a definitive diagnosis.
- Regarding the adrenal lesions, consider the following:
 1. Baseline blood pressure measurement to assess for systemic hypertension
 2. Urinalysis to assess for isosthenuria and proteinuria.
 3. Further testing for a functional tumor (i.e., low-dose dexamethasone suppression test, urine/blood catecholamine levels).



The information and recommendations provided are based on the images presented by the referring veterinarian/sonographer. No evaluation can be communicated regarding pathology that was not visible in the image/video clips provided.

Thank you for this referral. If the clinical or image interpretation does not parallel your findings or if I can be of any further assistance, please contact me.

Andrea Nicastro, MPH, DVM, Diplomate DACVIM (Small Animal Internal Medicine)
info@SonoPath.com