



PATIENT PRESENTING CLINICAL SIGNS

Adele Quinonez History: Presented as a referral for an abdominal ultrasound to evaluate vomiting. PT presented with a history of vomiting for 1 week. Patient responded to pantoprazole and Cerenia tabs and relapsed 3-4 days ago. Started hospitalization.

SPECIES

Canine

Abnormal PE/Chem/CBC/UA Results: Radiographs: Possible cranial abdominal mass. FNA of the liver nodules were taken: Pending

BREED

Swiss Shepherd

Urinary System

The urinary bladder wall is normal in thickness and the mucosal surface is smooth. The bladder is moderately distended. Luminal contents are anechoic. No cystic calculi are observed. The region of the trigone is normal.

SEX

Female Spayed

The left kidney is normal in size (6.80 cm in length) with a normal shape, architecture and smooth peripheral margins. There is a normal 1:3 cortex to medulla ratio with minimal to mild loss of corticomedullary distinction. There is no evidence of pyelectasia, nephroliths, infarcts or hydroureter.

AGE

10 years

The right kidney is normal in size (6.31 cm in length) with a normal shape, architecture and smooth peripheral margins. There is a normal 1:3 cortex to medulla ratio with minimal to mild loss of corticomedullary distinction. There is no evidence of pyelectasia, nephroliths, infarcts or hydroureter.

WEIGHT

65 lbs

Adrenal Glands

The left adrenal gland is normal in size (0.48 cm at cranial pole) (0.59 cm at caudal pole) with a normal shape and homogenous parenchyma. The glandular echogenicity and detail are unremarkable. Capsule, cortex, and medullary definition are normal. The phrenicoabdominal vein and surrounding vasculature appear normal.

INTERPRETED BY

Andrea Nicastro, DVM,
Diplomate ACVIM
(Small Animal Internal
Medicine)

The right adrenal gland is in normal size (0.70 cm at cranial pole) (0.50 cm at caudal pole) with a normal shape and homogenous parenchyma. The glandular echogenicity and detail are unremarkable. Capsule, cortex, and medullary definition are normal. The phrenicoabdominal vein and surrounding vasculature appear normal.

IMAGING PERFORMED BY

Dr. Ferrer DVM

Spleen

The spleen is normal in size (2.09 cm in width at the level of the hilus) with a normal capsular contour. There is appropriate echogenicity and echotexture. No focal lesions are observed. Splenic vasculature appears normal.

HOSPITAL NAME

Paseos VC

Liver

The liver is subjectively prominent in size with irregular peripheral contours. Throughout the organ, numerous, varying-sized, coalescing heterogenous masses (some of which are cavitated) are observed. The largest mass effect is >6.00 cm. The lesions cause capsular expansion. The mesentery effacing the serosal surface of the liver is mildly hyperechoic. Hepatic vasculature and intrahepatic biliary tracts are of normal volume with no evidence of congestion.

REFERRING VET

Dr. Marylin Davila

The gall bladder lumen is moderately distended. The wall is thin and smooth. Luminal contents are anechoic. The cystic and common bile ducts are normal/not seen.

INVOICE

12654

Gastrointestinal

The gastric lumen is severely fluid-distended and hypomotile. The gastric wall is normal in thickness with a normal layering pattern. The pyloric outflow tract appears patent. The small intestinal lumen is not

DATE

4.4.23

dilated. The small intestinal wall is normal in thickness with a normal layering pattern and appropriate mural detail. Discreet masses are not identified. The ileocecolic junction and colonic wall are normal.

Pancreas

The region of the pancreas is isoechoic relative to surrounding omental fat. No obvious parenchymal abnormalities are observed. There is no evidence of regional inflammation or effusion.

Free Abdomen

There is no obvious evidence of free fluid. A 0.93 lymph node is observed at the aortic trifurcation.

ULTRASONOGRAPHIC FINDINGS

Primary Findings

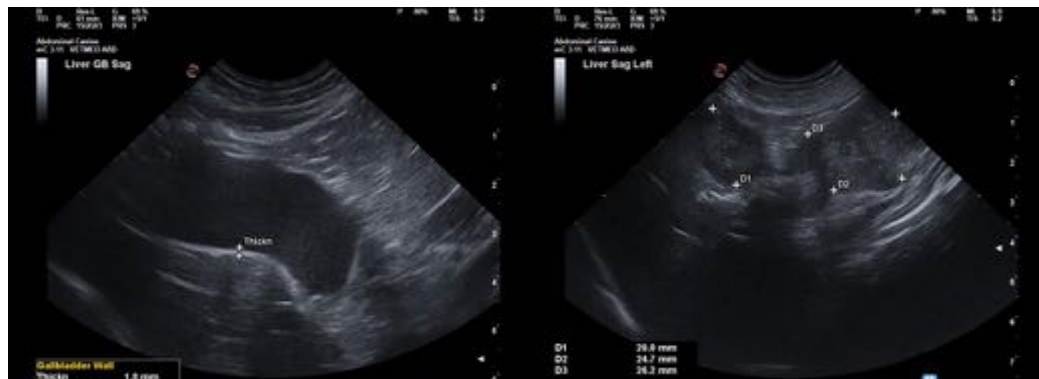
- Numerous hepatic masses. Neoplasia (i.e., round cell tumor, adenocarcinoma) is suspected. However, a multi-focal inflammatory process cannot be excluded. Mild cranial peritonitis is present.
- The gastric ileus may be secondary to a structural obstruction caused by the masses around the proximal duodenum. Alternatively, a fictional obstruction is possible.

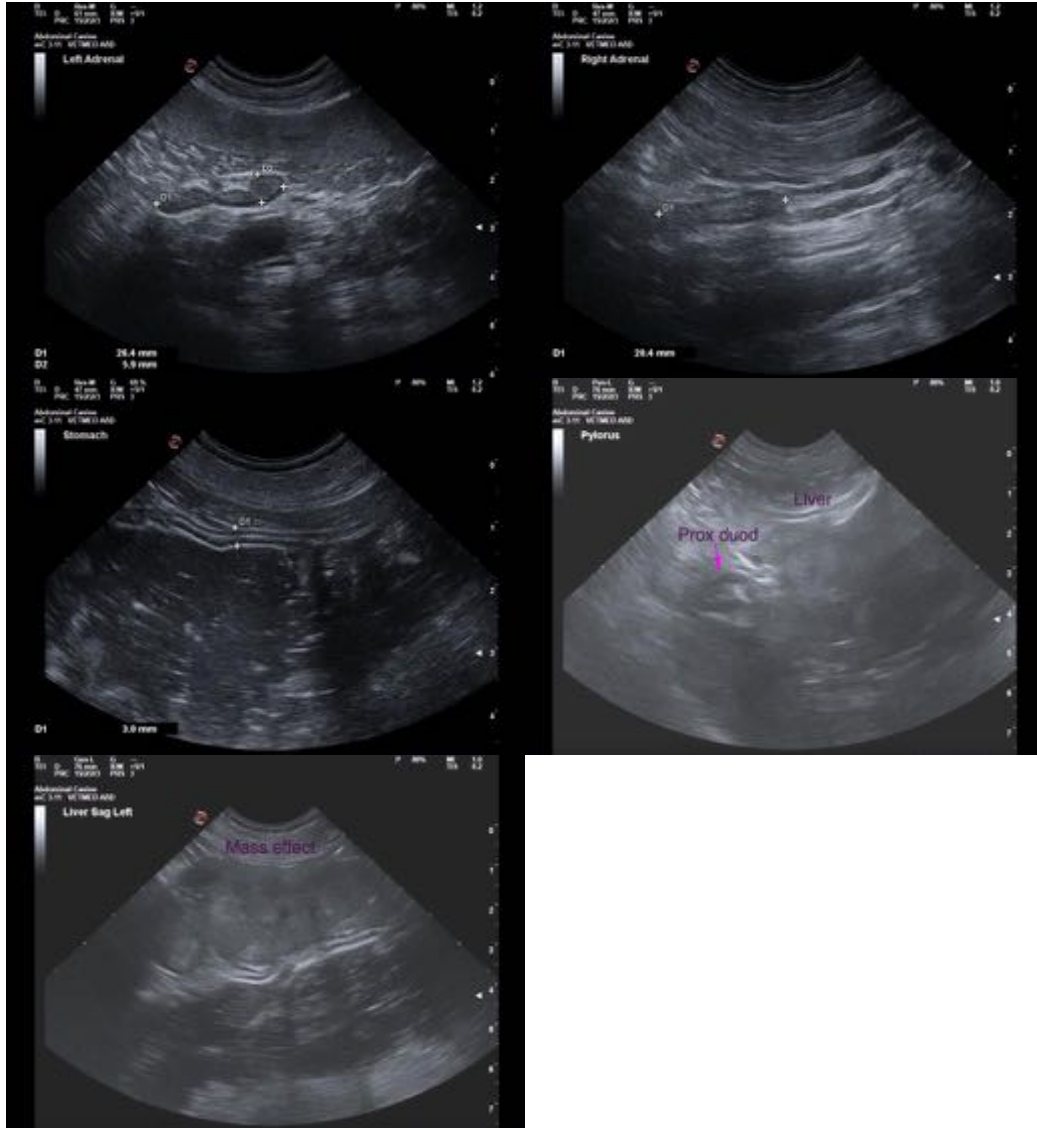
Secondary Findings

- Mild bilateral chronic age-related renal changes
- The prominent lymph node in the caudal abdomen is likely reactive.

INTERPRETATION OF THE FINDINGS & FURTHER RECOMMENDATIONS

- Three-view thoracic radiographs are recommended to assess for pulmonary metastases.
- If the hepatic cytology results are inconclusive, an abdominal exploratory with surgical liver biopsies may be necessary to get a definitive diagnosis. If pursued, the upper GI tract should be evaluated to assess for structural obstruction by the liver masses. Given the diffuse nature of the hepatic pathology, the prognosis is consider guarded.





The information and recommendations provided are based on the images presented by the referring veterinarian/sonographer. No evaluation can be communicated regarding pathology that was not visible in the image/video clips provided.

Thank you for this referral. If the clinical or image interpretation does not parallel your findings or if I can be of any further assistance, please contact me.

Andrea Nicastro, MPH, DVM, Diplomate DACVIM (Small Animal Internal Medicine)
info@SonoPath.com