IMAGING PERFORMED BY

IntraPet.com

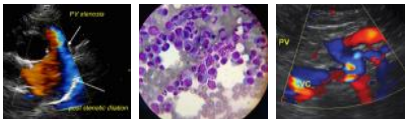

SonoPath
Clinical Sonography & Telecytology
EDUCATIONAL TELECONSULTATION SERVICES™
1-800-838-4268 info@sonopath.com SonoPath.com

DATE
4/4/2022

PATIENT
Stoma Jaeger

SPECIES
Canine

BREED
DSH

SEX
Neutered Male

AGE
11/6/2016

WEIGHT
12.5 lbs

INTERPRETED BY
Andrea Nicastro, DMV, Diplomate DACVIM (Small Animal Internal Medicine)

HOSPITAL NAME
Eastern AH

REFERRING VET
Dr. Sole

INVOICE
10667

PRESENTING CLINICAL SIGNS

History: Asymptomatic, elevated ALT on routine annual bloodwork- persistent after 1 month Amoxicillin, Denamarin tx.

Current Medications: None listed.
Lab Results: ALT persistently over 400.
Date of Previous IntraPet Ultrasound: No previous.
Sedation: Not required to complete full diagnostic ultrasound.
Stat Report: Not requested.

Imaging Performed By: Rachel Brilhart, RDMS.

ULTRASONOGRAPHIC EXAMINATION OF THE ABDOMEN

Urinary System
The urinary bladder, trigone, and pelvic urethra are normal in thickness and the mucosal surface is smooth. The bladder lumen is moderately distended with mostly anechoic urine. No masses, inflammatory changes or calculi are observed. Ureteral papillae and visualized portion of the proximal urethra, visible to a depth of 2 cm, are normal.

The left kidney is normal size (4.21 cm in length); normal shape and architecture with smooth peripheral margins. There is a normal 1:3 cortex to medulla ratio with normal corticomedullary distinction. There is no evidence of pyelectasia, nephroliths, infarcts or hydroureter. Renal vasculature is normal.

The right kidney is normal size (4.41 cm in length); normal shape and architecture with smooth peripheral margins. There is a normal 1:3 cortex to medulla ratio with normal corticomedullary distinction. There is no evidence of pyelectasia, nephroliths, infarcts or hydroureter. Renal vasculature is normal.

Adrenal Glands
The left adrenal gland is normal size (0.47 cm width). Normal shape and glandular echogenicity. The phrenicoabdominal vein and surrounding vasculature are normal.

The right adrenal gland is normal size (0.46 cm width). Normal shape and glandular echogenicity. The phrenicoabdominal vein and surrounding vasculature are normal.

Spleen
The spleen is normal in size (0.68 cm in width at the level of the hilus) with a normal capsular contour. There is appropriate echogenicity and echotexture. No focal lesions are observed. Splenic vasculature is normal.

Liver
The liver is subjectively normal in size with normal curvilinear peripheral contours. The parenchyma is hypoechoic relative to the spleen and homogenous in appearance. No distinct focal lesions are observed. There is a subtle increase in portal markings. Hepatic vasculature and intrahepatic biliary tracts are of normal volume with no evidence of congestion.

The gall bladder lumen is moderately distended. The wall is thin and smooth. Luminal contents are anechoic. The cystic and common bile ducts are normal.

Gastrointestinal

The stomach and intestine are free of stasis and exhibit normal peristaltic activity. The gastric lumen is not distended. The gastric wall and pylorus are normal in thickness with a normal layering pattern. The pyloric outflow tract is patent. The small intestinal lumen is not dilated. The small intestinal wall thickness is normal with a normal layering pattern and appropriate mural detail. Discreet masses are not identified. The ileocecocolic junction and colonic wall are normal. There is no evidence of an obstructive pattern.

Pancreas

The left and right limbs are visible/prominent, with minimal deviation from the normal peripheral contours. The parenchyma is isoechoic, to slightly hypoechoic relative to surrounding omental fat. No distinct focal lesions are observed. The pancreatic duct is not overtly dilated. Surrounding mesentery is mildly hyperechoic.

Free Abdomen

There is no evidence of free fluid. A few prominent mesenteric lymph nodes are visualized, the largest measuring 1.79 cm in length.

ULTRASONOGRAPHIC FINDINGS

Primary Findings

- The increase in hepatic portal markings is suggestive of an inflammatory hepatopathy. However, normal variation cannot be excluded.
- The pancreatic changes are suggestive of chronic active pancreatitis.
- The lymph node changes are most consistent with reactive lymphadenitis or lymphoid hyperplasia.

INTERPRETATION OF THE FINDINGS & FURTHER RECOMMENDATIONS

- Pre-and postprandial serum bile acids are recommended to assess hepatic function. Consider hepatic tissue sampling (fine-needle aspiration or surgical biopsy). Surgical biopsies are preferred in that they are more likely to be reflective of global organ pathology. If surgery is pursued, aerobic and anaerobic bile cultures are also recommended. Three-view thoracic radiographs should be considered prior to anesthesia to assess cardiopulmonary status.

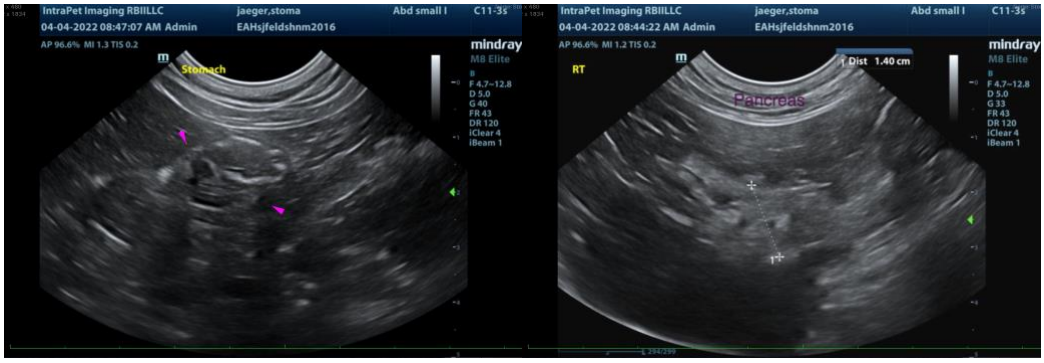

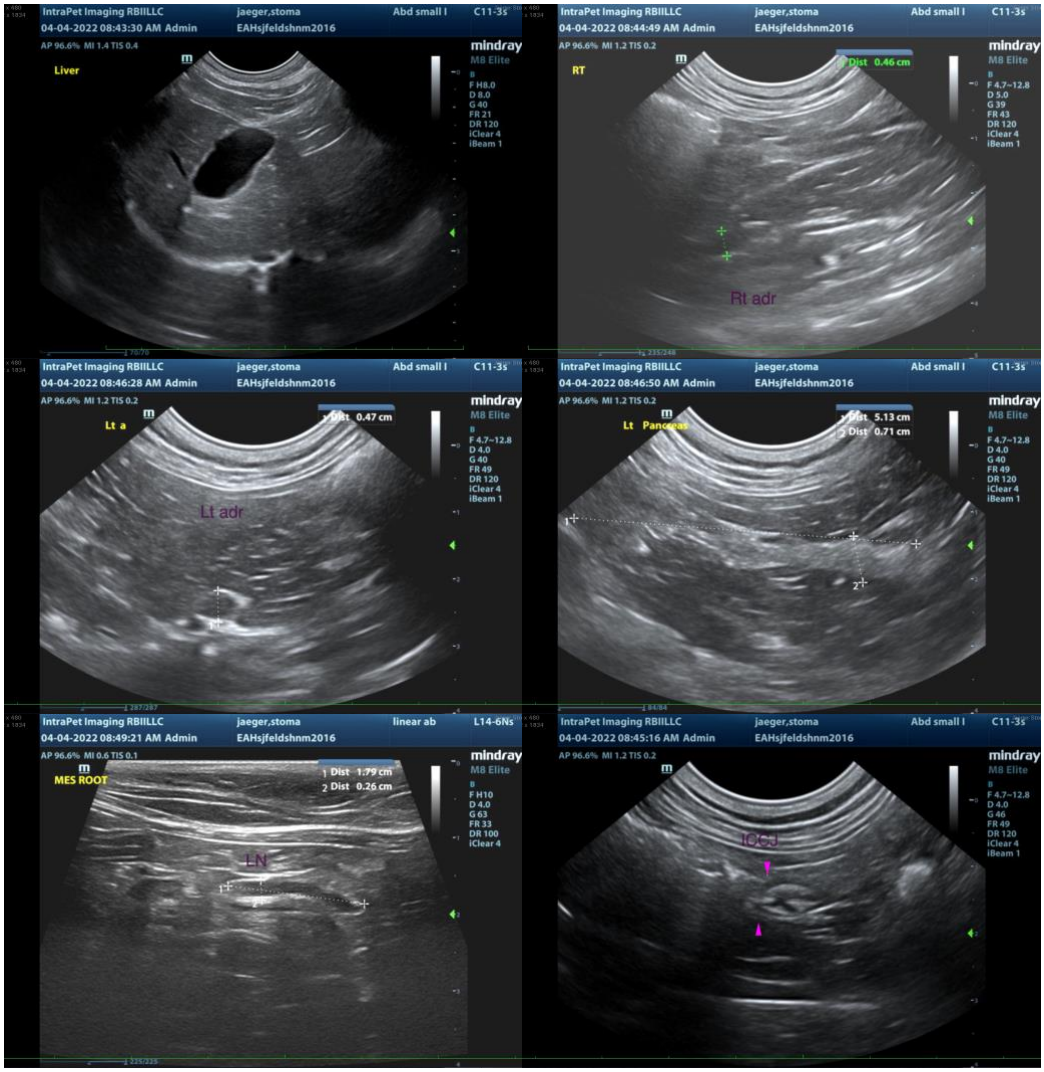

The information and recommendations provided are based on the images presented by the referring veterinarian/sonographer. No evaluation can be communicated regarding pathology that was not visible in the image/video clips provided.

Thank you for this referral. If the clinical or image interpretation does not parallel your findings or if I can be of any further assistance, please contact me.

Andrea Nicastro, DVM, Diplomate DACVIM (Small Animal Internal Medicine)
info@SonoPath.com