IMAGING PERFORMED BY

IntraPet.com

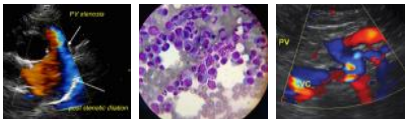

SonoPath
Clinical Sonography & Telecytology
EDUCATIONAL TELECONSULTATION SERVICES™
1-800-838-4268 info@sonopath.com SonoPath.com

DATE

4/4/2022

PATIENT

Slim Hauter

SPECIES

Canine

BREED

Brussels Griffon Mix

SEX

Neutered Male

AGE

8/28/2010

WEIGHT

15.4 lbs

INTERPRETED BY

Andrea Nicastro, DMV, Diplomate DACVIM (Small Animal Internal Medicine)

HOSPITAL NAME

Eastern Animal Hospital

REFERRING VET

Dr. Warner-Jones

INVOICE

10669

PRESENTING CLINICAL SIGNS

Poorly regulated diabetic. Seeking comorbidities complicating his regulation.

Current Medications: Vetsulin 4.5 units SQ BID. Gabapentin 150mg PO 2 hours prior to scan.
Lab Results: ALT 143, ALKP 250, TB 0.4, BG >600, Na and K sl low, Chol and TG high, PSL 403, Platelets 1182.
Date of Previous IntraPet Ultrasound: No previous.
Sedation: Not required to complete full diagnostic ultrasound.
Stat Report: Not requested.

Imaging Performed By: Rachel Brilhart, RDMS.

ULTRASONOGRAPHIC EXAMINATION OF THE ABDOMEN

Urinary System

The urinary bladder is moderately distended with anechoic. The wall is slightly thickened (up to 0.72 cm), with a subtly irregular mucosal surface along the ventral aspect. No cystic calculi are observed. The region of the trigone and the visible of the proximal urethra are normal.

The prostate is normal in size (0.86 cm in width) and shape. Parenchyma is homogenous. The prostatic urethra appears normal without evidence of dilation or obstruction.

The left kidney is normal size (4.76 cm in length); normal shape and architecture with smooth peripheral margins. There is a normal 1:3 cortex to medulla ratio with mild to moderate loss of corticomedullary distinction. A few, small, nonobstructive nephroliths are visualized. There is no evidence of pyelectasia, infarcts or hydroureter. Renal vasculature is normal.

The right kidney is normal size (4.50 cm in length); normal shape and architecture with smooth peripheral margins. There is a normal 1:3 cortex to medulla ratio with mild to moderate loss of corticomedullary distinction. A few, small, nonobstructive nephroliths are visualized. There is no evidence of pyelectasia, infarcts or hydroureter. Renal vasculature is normal.

Adrenal Glands

The left adrenal gland is mildly enlarged (0.64 cm at cranial pole) (0.76 cm at caudal pole) (1.89 cm in length); with a normal shape. A 0.40 cm ill-defined, hyperechoic focus is observed at the caudal aspect. The remaining glandular echogenicity and detail are normal. The phrenicoabdominal vein and surrounding vasculature are normal.

The right adrenal gland is borderline enlarged (0.64 cm at cranial pole) (0.56 cm at caudal pole) (1.60 cm in length); normal shape; homogenous parenchyma. The glandular echogenicity and detail are unremarkable. Capsule, cortex, and medullary definition are normal. The phrenicoabdominal vein and surrounding vasculature are normal.

Spleen

The spleen is normal in size (0.94 cm in width at the level of the hilus) with a normal capsular contour. There is appropriate echogenicity and echotexture. No focal lesions are observed. Splenic vasculature is normal.

Liver
The liver is subjectively prominent in size with swollen curvilinear peripheral contours. The parenchyma is hypoechoic relative to the spleen and exhibits mild heterogeneity. No distinct focal lesions are observed. Hepatic vasculature and biliary tracts are of normal volume with no evidence of congestion.

The gall bladder lumen is mildly to moderately distended. The wall is normal in thickness. A few polypoid-like lesions are arising from the luminal surface. A scant amount of echogenic debris is also present within the lumen. The cystic and common bile ducts are normal/not seen.

Gastrointestinal
The stomach and intestine are free of stasis and exhibit normal peristaltic activity. The gastric lumen is not distended. The gastric wall and pylorus are normal in thickness with a normal layering pattern. The small intestinal lumen is not dilated. The small intestinal wall thickness is normal with a normal layering pattern and appropriate mural detail. Discreet masses are not identified. The colonic wall is normal. No obstructive or overt infiltrative disease is noted.

Pancreas
The right limb of the pancreas is visible with normal curvilinear peripheral contours. The parenchyma is largely isoechoic-to-hyperechoic relative to surrounding omental fat and slightly mottled in appearance. The pancreatic duct is visible but not overtly dilated. There is no evidence of peripancreatic inflammation or effusion.

Free Abdomen
There is no evidence of free fluid. The abdominal lymph nodes are normal/not visible.

ULTRASONOGRAPHIC FINDINGS

Primary Findings

- The urinary bladder wall changes could be consistent with mild cystitis or may be a normal variant for this patient.
- The bilateral adrenal changes are most consistent with hyperplastic change.

Secondary Findings

- Bilateral age-related renal changes with right nonobstructive nephrolithiasis
- The hepatic parenchyma changes are most consistent with a benign hepatopathy (i.e., vacuolar hepatopathy, regenerative nodular hyperplasia, with a lower possibility of an inflammatory process or hepatotoxicosis (i.e., copper). Infiltrative neoplasia is possible but considered less likely.
- The pancreatic changes are suggestive of age-related remodeling/fibrosis. The current low-grade pancreatitis is possible, particularly if the patient exhibits pain on cranial abdominal palpation.

INTERPRETATION OF THE FINDINGS & FURTHER RECOMMENDATIONS

To further assess for causes of poor diabetic regulation, consider the following:

1. Three-view thoracic radiographs to assess for occult disease in the chest
2. Urine culture and sensitivity
3. Cushing's testing (i.e., low-dose dexamethasone suppression test or ACTH stimulation test)
4. T4/free T4 by equilibrium dialysis, if not already performed.

If the above diagnostics are inconclusive, adjustment in the insulin dose or switching of insulin types may be warranted.

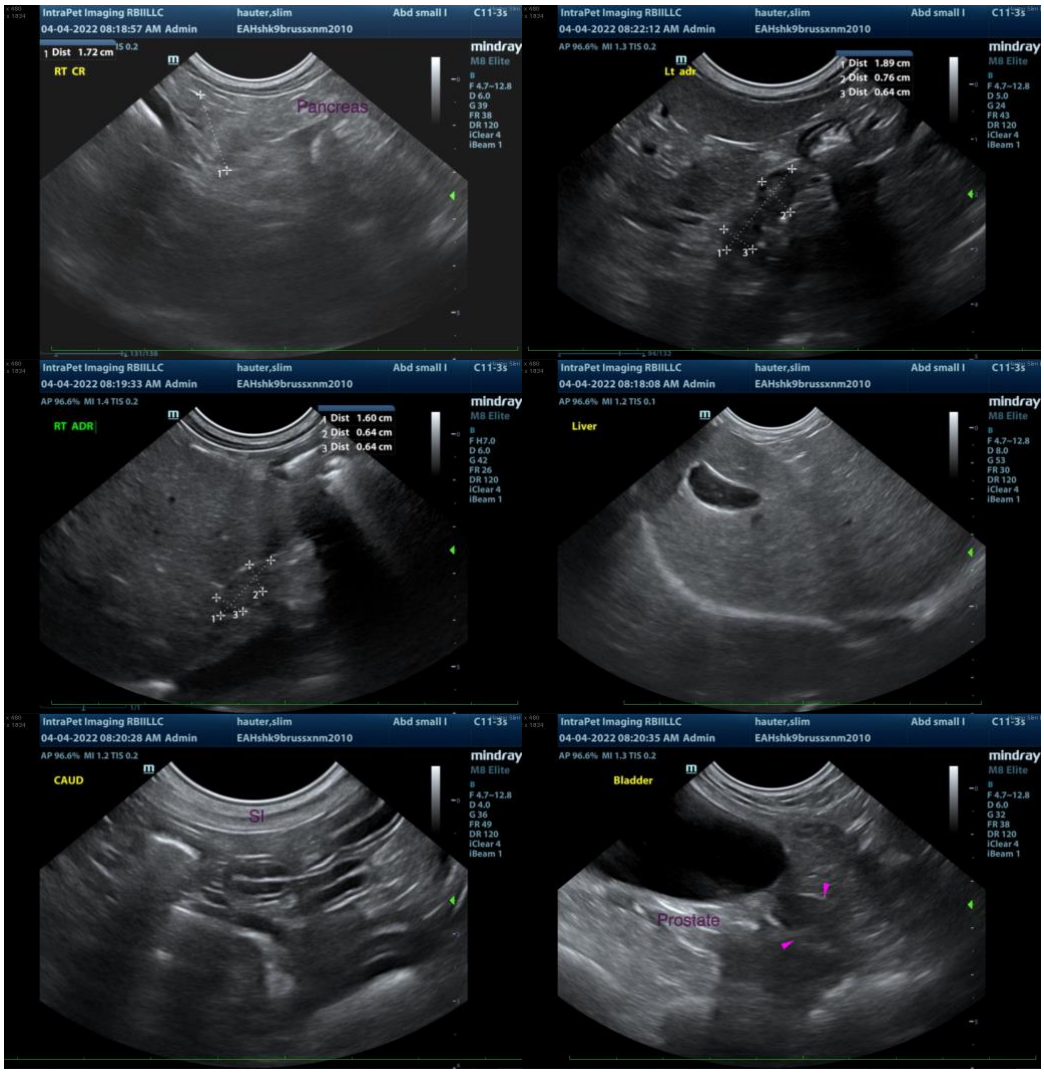

The information and recommendations provided are based on the images presented by the referring veterinarian/sonographer. No evaluation can be communicated regarding pathology that was not visible in the image/video clips provided.

Thank you for this referral. If the clinical or image interpretation does not parallel your findings or if I can be of any further assistance, please contact me.

Andrea Nicastro, DVM, Diplomate DACVIM (Small Animal Internal Medicine)
info@SonoPath.com