



**PATIENT**

Samford Lenox

**SPECIES**

Canine

**BREED**

GSD

**SEX**

Male Neutered

**AGE**

5/24/2019

**WEIGHT**

34.4kg

**INTERPRETED BY**

Andrea Nicastrò DVM  
Diplomate ACVIM  
(Sm Animal Internal Med)

**IMAGING  
PERFORMED BY**

Andrea Nicastrò DVM  
Diplomate ACVIM  
(Sm Animal Internal Med)

**HOSPITAL NAME**

VCA Palmetto

**REFERRING VET**

Amber Leavis

**INVOICE**

22814

**DATE**

4-3-26

**PRESENTING CLINICAL SIGNS**

Clinical Exam Findings: Presented 3/25 for acute onset of SQ masses throughout body. Cytology showed concern for histiocytic neoplasia. Planned to take biopsy of mass so sent out labwork, which showed anemia. Currently adding on saline agglutination/Coombs/reticulocyte count to assess anemia but bringing P in for AUS +/- CXR to look for neoplastic causes of anemia. P is fear aggressive so will plan sedation to perform diagnostics.

Current Medications: Carprofen 75 mg: 1 tab PO q12h, Gabapentin 300 mg: 1 cap PO q12h  
Radiographic Findings: None being sent  
Sedated with Dexdomitor for this study.

**ULTRASONOGRAPHIC EXAMINATION OF THE ABDOMEN**

**Urinary System**

The urinary bladder wall is normal in thickness. The mucosal surface in the region of the apex is slightly irregular. bladder is moderately distended. Luminal contents are anechoic. No cystic calculi are observed. The region of the trigone and the proximal urethra, visible to a depth of 2 cm, are normal.

The prostate is normal in size (0.67 cm in width) and shape. Parenchyma is homogenous. The prostatic urethra appears normal without evidence of dilation or obstruction.

The left kidney is enlarged (>10.7 cm) with an irregular shape. A >6.0 cm irregular, heterogenous, cavitated mass is arising from the cranial pole. Surrounding mesentery is hyperechoic. In the remainder of the kidney, there is a normal 1:3 cortex to medulla ratio with minimal loss of corticomedullary distinction. A few ill-defined hypoechoic nodules are observed within the cortex. There is no evidence of pyelectasia, nephroliths, infarcts or hydroureter. Renal vasculature is normal.

The right kidney is normal in size (8.20 cm in length) with a normal shape, architecture and smooth peripheral margins. There is a normal 1:3 cortex to medulla ratio with minimal loss of corticomedullary distinction. A 0.69 cm hypoechoic nodule is observed at the caudolateral aspect. There is no evidence of pyelectasia, nephroliths, infarcts or hydroureter. Renal vasculature is normal.

**Adrenal Glands**

The left adrenal gland is normal in size (0.56 cm at cranial pole) (0.67 cm at caudal pole) with a normal shape and homogenous parenchyma. The glandular echogenicity and detail are unremarkable. Capsule, cortex, and medullary definition are normal. The phrenicoabdominal vein and surrounding vasculature are normal.

The right adrenal gland is normal in size (1.06 cm at cranial pole) (0.75 cm at caudal pole) with a normal shape and homogenous parenchyma. The glandular echogenicity and detail are unremarkable. Capsule, cortex, and medullary definition are normal. The phrenicoabdominal vein and surrounding vasculature are normal.

**Spleen**

The spleen is overall normal in size (1.67 cm in width at the level of the hilus). The parenchyma is mottled in appearance. There is appropriate echogenicity and echotexture. A 2.3 x 2.0 cm irregular, hypoechoic expansile mass is arising from the parenchyma, approximately mid-body. Splenic vasculature is normal.

**Liver**

The liver is subjectively normal in size with normal contours and structure. There is appropriate echogenicity and echotexture. No overt structural evidence of inflammatory, infiltrative, or regenerative pathology is evident. Vascular and biliary tracts are of normal volume with no evidence of congestion. The portal vein to caudal vena cava ratio is approximately 1: 1.



**PATIENT**

Samford Lenox

The gallbladder lumen is moderately distended. The wall is thin and smooth. Luminal contents are mostly anechoic. The cystic and common bile ducts are normal/not seen.

**SPECIES**

Canine

**Gastrointestinal**

The gastric lumen is not distended. The gastric wall and pylorus are normal in thickness with a normal layering pattern. The pyloric outflow tract is patent. The small intestinal lumen is not dilated. The small intestinal wall is normal in thickness with a normal layering pattern and appropriate mural detail. Discreet masses are not identified. The colonic wall is normal. There is no evidence of an obstructive pattern.

**BREED**

GSD

**Pancreas**

The right limb of the pancreas is visible with normal curvilinear peripheral contours. The parenchyma is slightly hypoechoic relative to surrounding omental fat and slightly mottled in appearance. The pancreatic duct is visible but not overtly dilated. There is no evidence of peripancreatic inflammation or effusion.

**SEX**

Male Neutered

**Lymph Nodes**

**AGE**

5/24/2019

A 2.62 x 0.68 cm medial iliac lymph node is visualized. A few prominent, rounded- to irregular hypoechoic lymph nodes are also observed in the left- mid-caudal abdomen (one measuring 1.71 x 0.99 cm). In addition, a 1.03 x 0.75 cm hypoechoic lymph node is observed in the cranial abdomen.

**WEIGHT**

34.4kg

**Free Abdomen**

In the midabdominal region, a 3.4 x 1.8 cm hypoechoic- to heterogenous mass is visualized in the omentum. In addition, a 1.59 x 0.55 cm hypoechoic- to heterogenous nodule appears to be arising from the ventral body wall. A large amount of echogenic free fluid is present.

**INTERPRETED BY**

Andrea Nicastrò DVM  
Diplomate ACVIM  
(Sm Animal Internal Med)

**Other**

In the visualized portion of the thorax, numerous B-lines are visible.

**ULTRASONOGRAPHIC FINDINGS**

**Primary Findings**

- Left renal mass effect. Neoplasia (i.e., sarcoma, carcinoma, round cell tumor) is strongly suspected with a low possibility of an inflammatory process. Adjacent retroperitonitis is present. The bilateral hypoechoic renal cortical nodules are concerning for metastatic disease with a lower possibility of a benign process (i.e., inflammatory, other).
- Splenic mass. Again, neoplasia is suspected with a lower possibility of a non-neoplastic process (i.e., focal lymphoid hyperplasia or similar).
- Mass in the omentum. Neoplasia is suspected.
- Body wall nodule. Neoplasia is suspected.
- The B-lines within the thorax are concerning for pulmonary parenchymal disease.

**IMAGING PERFORMED BY**

Andrea Nicastrò DVM  
Diplomate ACVIM  
(Sm Animal Internal Med)

**HOSPITAL NAME**

VCA Palmetto

**REFERRING VET**

Amber Leavis

**INVOICE**

22814

**DATE**

4-3-26

- The abdominal lymphadenopathy is concerning for metastatic disease with a lower possibility of lymphadenitis or lymphoid hyperplasia.
- Ascites. Considerations include neoplastic effusion, hemorrhage, other.



**PATIENT**

Samford Lenox

**SPECIES**

Canine

**BREED**

GSD

**SEX**

Male Neutered

**AGE**

5/24/2019

**WEIGHT**

34.4kg

**INTERPRETED BY**

Andrea Nicastro DVM  
 Diplomate ACVIM  
 (Sm Animal Internal Med)

**IMAGING PERFORMED BY**

Andrea Nicastro DVM  
 Diplomate ACVIM  
 (Sm Animal Internal Med)

**HOSPITAL NAME**

VCA Palmetto

**REFERRING VET**

Amber Leavis

**INVOICE**

22814

**DATE**

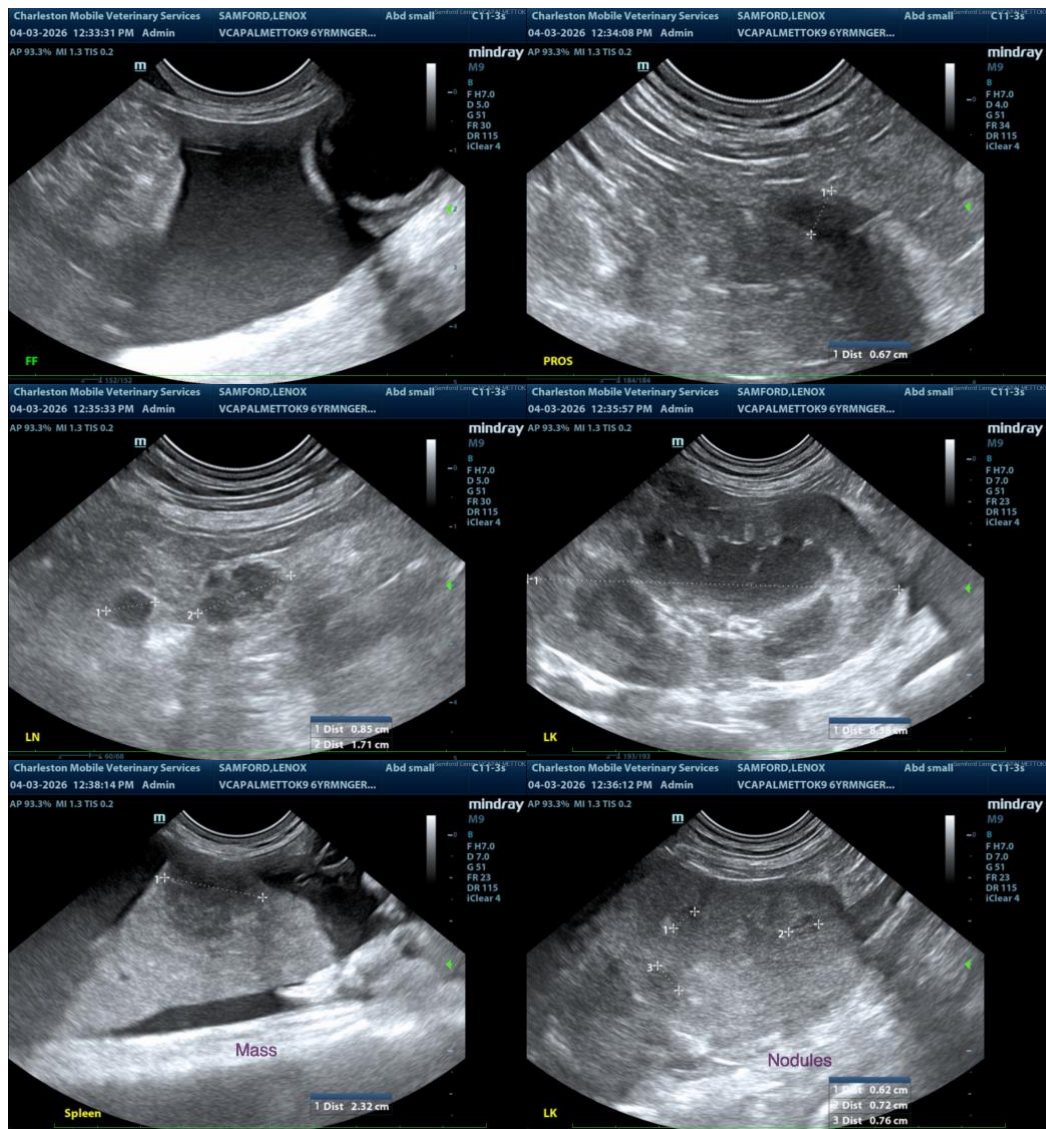
4-3-26

**Secondary Findings**

- The pancreatic changes are most consistent with age-related parenchymal remodeling, potentially secondary to a prior inflammatory episode, early fibrosis or chronic pancreatitis.

**INTERPRETATION OF THE FINDINGS & FURTHER RECOMMENDATIONS**

- Three-view thoracic radiographs are recommended to assess for pulmonary metastases.
- Consider cytologic evaluation of the abdominal fluid +/- the splenic, renal, and/or mesenteric masses for further evaluation.
- Depending on the results, consultation with a board-certified oncologist may be indicated.
- If further testing is not pursued, palliative care is recommended.





**PATIENT**

Samford Lenox

**SPECIES**

Canine

**BREED**

GSD

**SEX**

Male Neutered

**AGE**

5/24/2019

**WEIGHT**

34.4kg

**INTERPRETED BY**

Andrea Nicastrò DVM  
 Diplomate ACVIM  
 (Sm Animal Internal Med)

**IMAGING PERFORMED BY**

Andrea Nicastrò DVM  
 Diplomate ACVIM  
 (Sm Animal Internal Med)

**HOSPITAL NAME**

VCA Palmetto

**REFERRING VET**

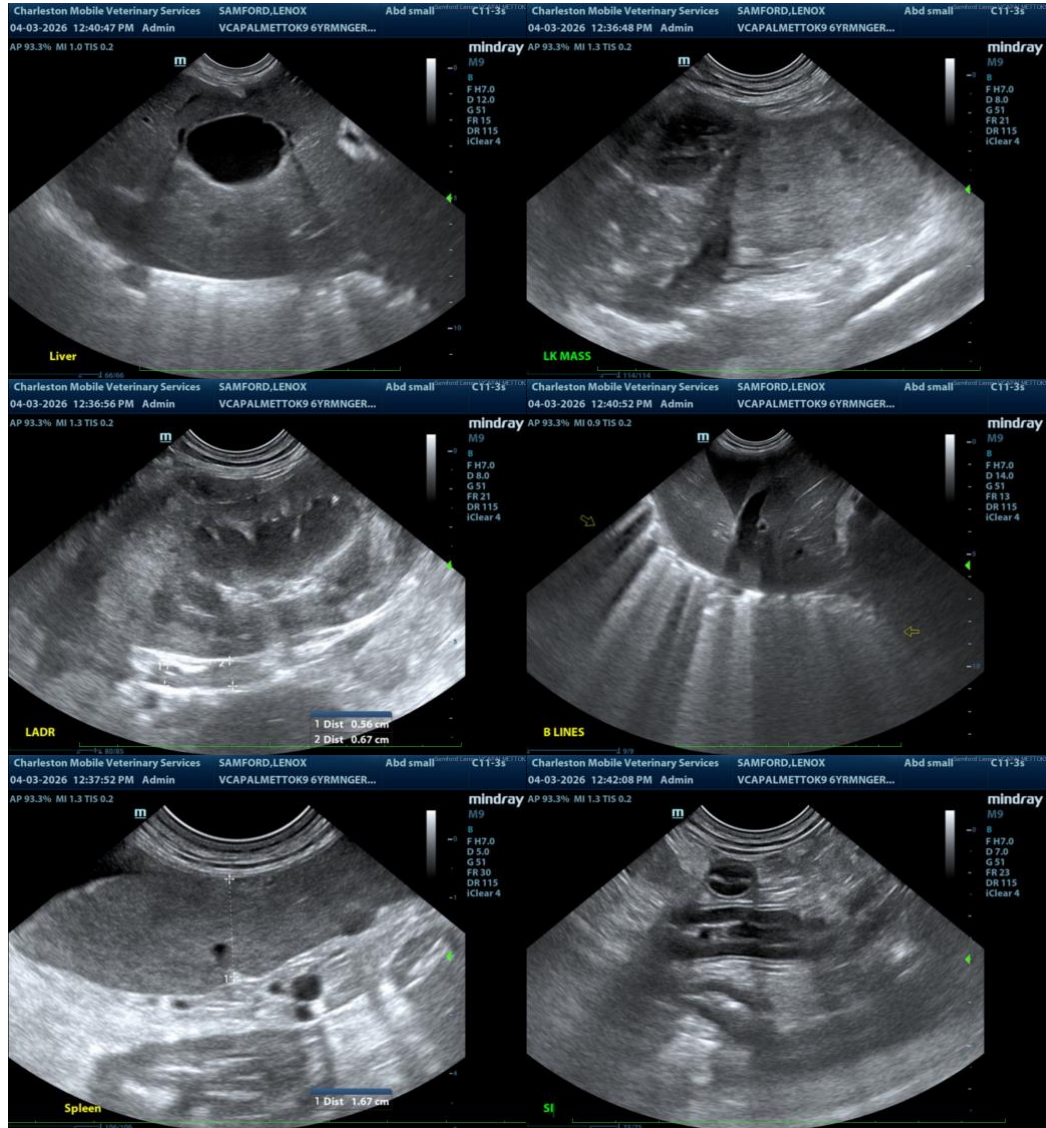
Amber Leavis

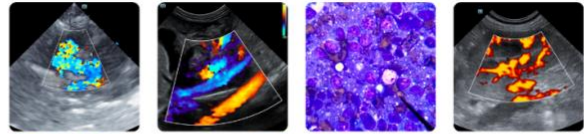
**INVOICE**

22814

**DATE**

4-3-26





**PATIENT**

Samford Lenox

**SPECIES**

Canine

**BREED**

GSD

**SEX**

Male Neutered

**AGE**

5/24/2019

**WEIGHT**

34.4kg

**INTERPRETED BY**

Andrea Nicastrò DVM  
 Diplomate ACVIM  
 (Sm Animal Internal Med)

**IMAGING PERFORMED BY**

Andrea Nicastrò DVM  
 Diplomate ACVIM  
 (Sm Animal Internal Med)

**HOSPITAL NAME**

VCA Palmetto

**REFERRING VET**

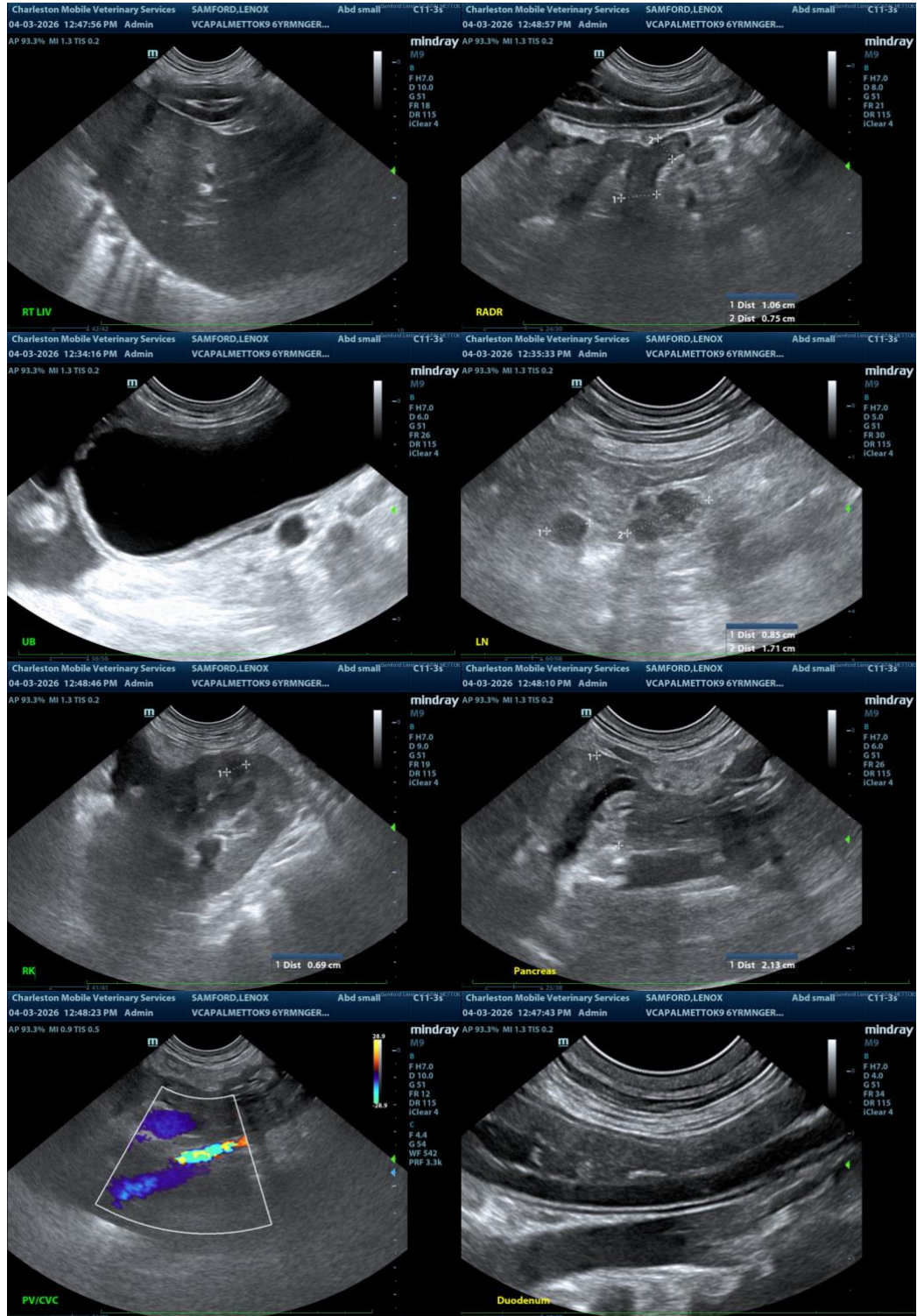
Amber Leavis

**INVOICE**

22814

**DATE**

4-3-26





**PATIENT**

Samford Lenox

**SPECIES**

Canine

**BREED**

GSD

**SEX**

Male Neutered

**AGE**

5/24/2019

**WEIGHT**

34.4kg

**INTERPRETED BY**

Andrea Nicastro DVM  
 Diplomate ACVIM  
 (Sm Animal Internal Med)

**IMAGING PERFORMED BY**

Andrea Nicastro DVM  
 Diplomate ACVIM  
 (Sm Animal Internal Med)

**HOSPITAL NAME**

VCA Palmetto

**REFERRING VET**

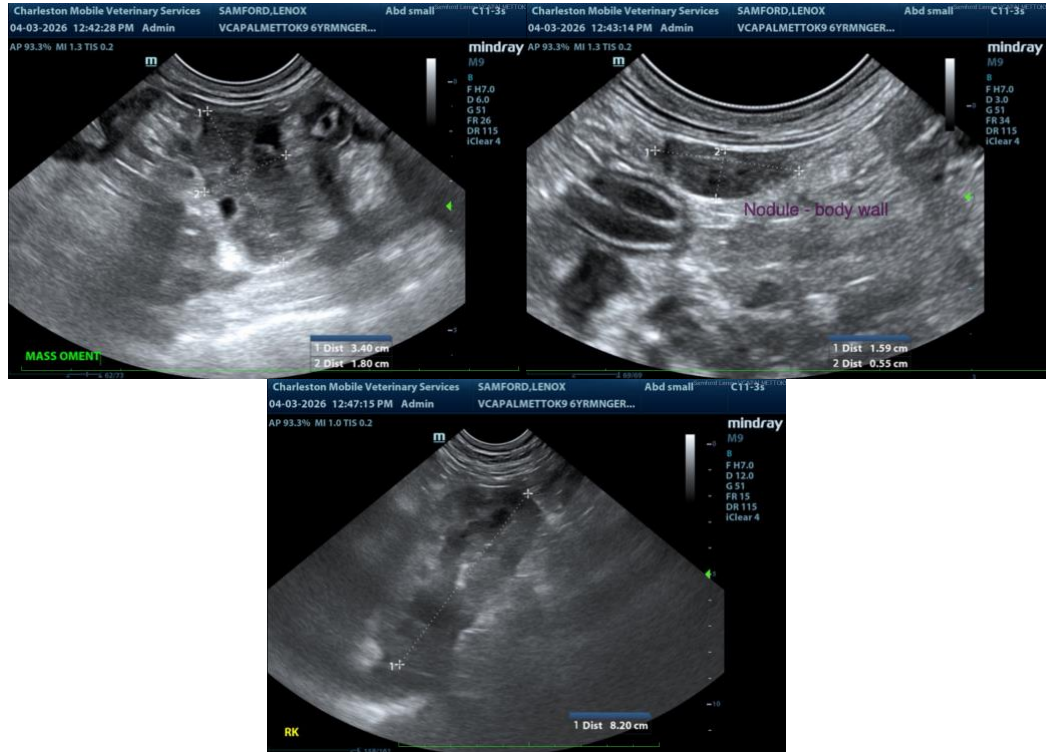
Amber Leavis

**INVOICE**

22814

**DATE**

4-3-26



The information and recommendations provided are based on the images presented by the referring veterinarian/sonographer. No evaluation can be communicated regarding pathology that was not visible in the image/video clips provided.

Thank you for this referral. If the clinical or image interpretation does not parallel your findings or if I can be of any further assistance, please contact me.

**Andrea Nicastro, MPH, DVM, Diplomate DACVIM (Small Animal Internal Medicine)**  
[info@SonoPath.com](mailto:info@SonoPath.com)