



**PATIENT PRESENTING CLINICAL SIGNS**

**Maiky Esteras** History: Patient presented as a referral for an abdominal ultrasound to further evaluate a possible abdominal mass noticed on radiographs after recent visit. Pt presented originally to evaluate bilateral preputial swelling that appears to be possibly inguinal hernias. The owner noted inflammation around the inguinal region 2 months ago, testicular scrotum has increased in size as well.

**SPECIES**

**Canine** Abnormal PE/Chem/CBC/UA Results: Radiographs: inguinal region, no evidence of GI looks or other internal organ structures noted. Large soft tissue swelling pushing stomach cranially.

**BREED**

**ULTRASONOGRAPHIC EXAMINATION OF THE ABDOMEN**

**Pibull Mix**

**Urinary System**

The urinary bladder wall is normal in thickness and the mucosal surface is smooth. The bladder is moderately distended. Luminal contents are anechoic. No cystic calculi are observed. The region of the trigone and the proximal urethra, visible to a depth of 2 cm, are normal.

**SEX**

**Intact Male**

The prostate is enlarged (3.86 cm in width) with a slightly irregular shape. Parenchyma is isoechoic to hyperechoic relative to surrounding omental fat and slightly heterogenous in appearance. Numerous small, ill-defined cystic areas are observed throughout the gland. A small amount of subcapsular fluid is observed near the cystourethral junction. The prostatic urethra is not overtly dilated.

**AGE**

**8 years**

The left kidney is normal in size (7.96 cm in length) with a normal shape, architecture and smooth peripheral margins. The cortex is isoechoic relative to the spleen. There is a normal 1:3 cortex to medulla ratio with moderate loss of corticomedullary distinction. A small cortical cyst is also seen. Moderate pyelectasia is present (0.49 cm in the longitudinal plane). There is no evidence of nephroliths, infarcts or hydroureter.

**WEIGHT**

**68 lbs**

The right kidney is normal in size (6.90 cm in length) with a normal shape, architecture and smooth peripheral margins. The cortex is isoechoic relative to the spleen. There is a normal 1:3 cortex to medulla ratio with moderate loss of corticomedullary distinction. One to two small cortical cysts is also seen. Moderate pyelectasia is present (0.50 cm in the transverse plane). There is no evidence of nephroliths, infarcts or hydroureter.

**INTERPRETED BY**

Andrea Nicastro, DVM,  
Diplomate ACVIM  
(Small Animal Internal  
Medicine)

**IMAGING PERFORMED BY**

Dr. Ferrer, DVM

**HOSPITAL NAME**

Paseos VC

**Adrenal Glands**

The left adrenal gland is normal in size (0.50 cm at cranial pole) (0.78 cm at caudal pole) (3.35 cm in length) with a normal shape and homogenous parenchyma. The glandular echogenicity and detail are unremarkable. Capsule, cortex, and medullary definition are normal. The phrenicoabdominal vein and surrounding vasculature appear normal.

The right adrenal gland is in normal size (0.60 cm at cranial pole) (0.67 cm at caudal pole) (2.70 cm in length) with a normal shape and homogenous parenchyma. The glandular echogenicity and detail are unremarkable. Capsule, cortex, and medullary definition are normal. The phrenicoabdominal vein and surrounding vasculature appear normal.

**REFERRING VET**

Dra. Michelle Biello

**Spleen**

The spleen is enlarged with irregular peripheral contours. A >10.00 cm isoechoic solid mass is arising from the medial aspect. The lesion causes severe capsular expansion. In the remainder of the spleen, the parenchyma is homogenous. Splenic vasculature appears normal no evidence of thrombosis.

**INVOICE**

12649

**DATE**

4.3.23

**Liver**

The liver is subjectively normal in size with normal contours and structure. There is appropriate echogenicity and echotexture. No overt structural evidence of inflammatory, infiltrative, or regenerative

pathology is evident. Vascular and biliary tracts are of normal volume with no evidence of congestion. No pathological hepatic lymphadenopathy observed.

The gall bladder lumen is moderately distended. The wall is thin and smooth. Luminal contents are anechoic. The cystic and common bile ducts are normal/not seen.

### ***Gastrointestinal***

The stomach and intestine are free of stasis and exhibit normal peristaltic activity. The gastric lumen is not distended. The gastric wall and pylorus are normal in thickness with a normal layering pattern. The pyloric outflow tract is patent. The small intestinal lumen is not dilated. The small intestinal wall is normal in thickness with a normal layering pattern and appropriate mural detail. Discreet masses are not identified. The colonic wall is normal. There is no evidence of an obstructive pattern.

### ***Pancreas***

The region of the pancreas is isoechoic relative to surrounding omental fat. No obvious parenchymal abnormalities are observed. There is no evidence of regional inflammation or effusion.

### ***Free Abdomen***

Trace free fluid is observed. There is no evidence of inflammation or effusion. The abdominal lymph nodes are normal/not visible.

### ***Other***

The testicles are subjectively normal in size (left: 3.45 x 2.16 cm) (right: 3.64 x 2.45 cm) with normal shapes and homogenous parenchyma. No obvious pathology is observed.

Ill-defined fluid pockets are observed in the inguinal regions.

## **ULTRASONOGRAPHIC FINDINGS**

### **Primary Findings**

- Large splenic mass. Neoplasia, sarcoma, round cell tumor is suspected with a lower possibility of benign pathology (i.e., excessive lymphoid hyperplasia).
- The cause for the ill-defined fluid pockets in the inguinal region is unclear. Inguinal hernias are possible. However, other considerations include impaired venous return, lymphatic obstruction, focal peritonitis secondary to prostatitis, other.

### **Secondary Findings**

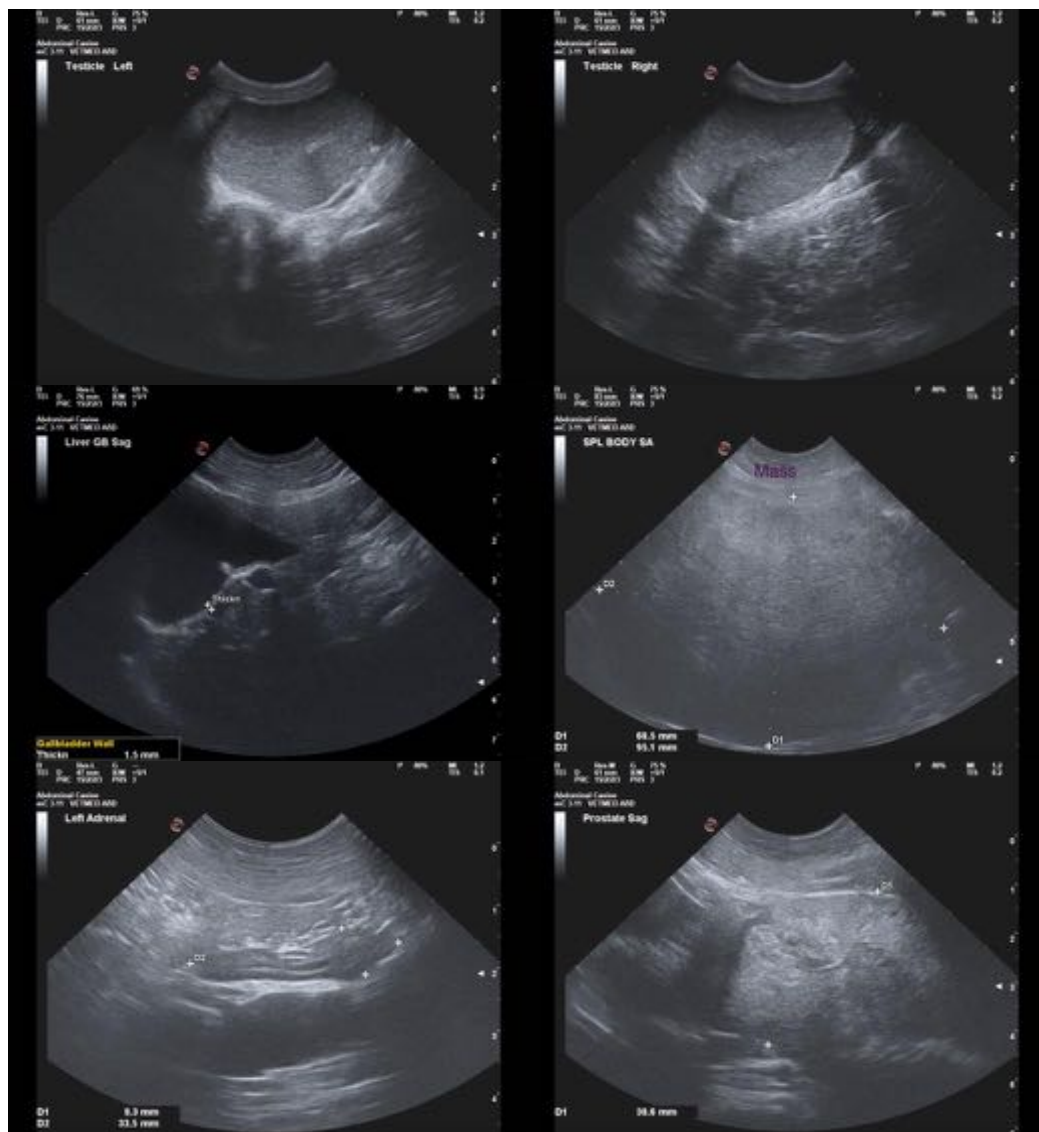
- Bilateral chronic age-related renal changes. The bilateral pyelectasia could be secondary to pyelonephritis, age-related remodeling, or some combination thereof.
- The prostate changes are consistent with benign cystic prostatic hyperplasia. There is potential for bacterial prostatitis, particularly if the patient's clinical history supports this diagnosis.

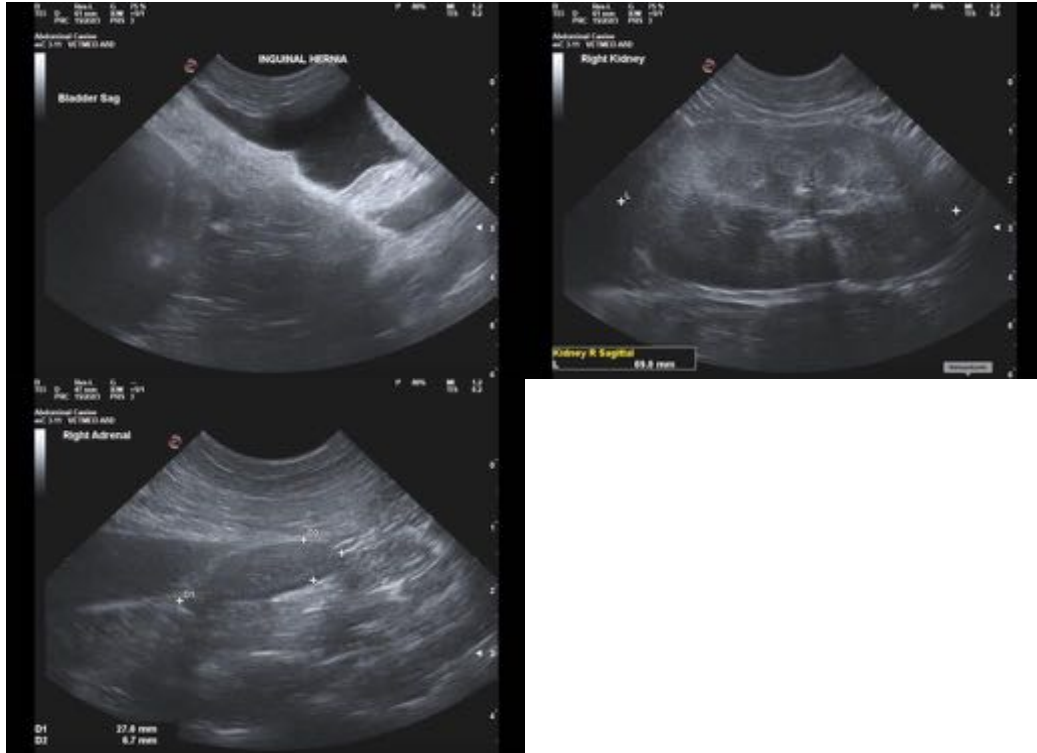
## **INTERPRETATION OF THE FINDINGS & FURTHER RECOMMENDATIONS**

- Three-view thoracic radiographs are recommended to assess for pulmonary metastases.
- A fine-needle aspirate of the splenic mass can be considered if clotting status is appropriate. A 25-gauge needle should be used. If the cytology results are inconclusive, a splenectomy with

submission of the spleen for histopathology is recommended. Castration should also be considered at the time of surgery.

- Regarding the prostate changes, consider a urine culture and sensitivity and/or a prostatic aspirate to further assess for prostatitis.
- Regarding the fluid in the inguinal region, consider aspiration with cytologic evaluation. An abdominal CT scan may also be useful in further characterizing pathology in this region.





The information and recommendations provided are based on the images presented by the referring veterinarian/sonographer. No evaluation can be communicated regarding pathology that was not visible in the image/video clips provided.

Thank you for this referral. If the clinical or image interpretation does not parallel your findings or if I can be of any further assistance, please contact me.

**Andrea Nicastro, MPH, DVM, Diplomate DACVIM (Small Animal Internal Medicine)**  
[info@SonoPath.com](mailto:info@SonoPath.com)