

PATIENT	PRESENTING CLINICAL SIGNS
MamaKitty Forester	History: Mama Kitty presented for poor BCS, unkempt hair coat and signs of intermittent appetite and vomiting. PE showed poor coat quality and BCS. No overt discomfort on palpation of the bowel or abdominal organs. Grade II/VI left parasternal heart murmur appreciated. Her examination was consistent with hyperthyroid cat. Working diagnosis Chief Concern / Provisional Diagnosis: hyperthyroid and pancreatitis
<b>SPECIES</b>	
Feline	
<b>BREED</b>	Abnormal PE/Chem/CBC/UA Results: CBC: wnl CHem: SDMA 17, ALT 191 UA: usg 1.015, 1+ prot, UPC 0.4 T4: 9.2 Spec Fpl: 21.9 Pro BNP: 77 fecal negative FeLv/FIV/HWT: negative
DSH	
<b>SEX</b>	
Female Spayed	
<b>AGE</b>	
11 years	
<b>WEIGHT</b>	
2.7 kg	
<b>INTERPRETED BY</b>	
Andrea Nicastro, DVM, Diplomate ACVIM (Small Animal Internal Medicine)	
<b>IMAGING PERFORMED BY</b>	
Loetitia Saint-Jacques, LVT	
<b>HOSPITAL NAME</b>	
MountainView AH	
<b>REFERRING VET</b>	
Dr Sarah Kalivoda	
<b>INVOICE</b>	
12887	
<b>DATE</b>	
4.27.23	

### ULTRASONOGRAPHIC EXAMINATION OF THE ABDOMEN

#### *Urinary System*

The urinary bladder wall is normal in thickness and the mucosal surface is smooth. The bladder is distended. A scant amount of suspended echogenic debris is observed within the lumen. No cystic calculi are observed. The region of the trigone and the proximal urethra, visible to a depth of 2 cm, are normal.

The left kidney is normal in size (3.10 cm in length) with a normal shape, architecture and smooth peripheral margins. The cortex is isoechoic relative to the spleen. There is a normal 1:3 cortex to medulla ratio with moderate loss of corticomedullary distinction. There is no evidence of pyelectasia, nephroliths, infarcts or hydroureter.

The right kidney is normal in size (3.10 cm in length) with a normal shape, architecture and smooth peripheral margins. The cortex is isoechoic relative to the spleen. There is a normal 1:3 cortex to medulla ratio with moderate loss of corticomedullary distinction. There is no evidence of pyelectasia, nephroliths, infarcts or hydroureter.

#### *Adrenal Glands*

The left adrenal gland is normal size (0.38 cm width). Normal shape and glandular echogenicity. The phrenicoabdominal vein and surrounding vasculature are normal.

The region of the right adrenal gland is evaluated. No obvious pathology is observed in this region.

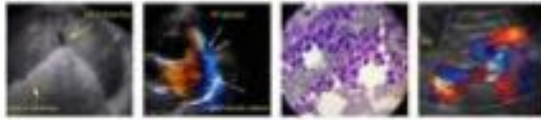
#### *Spleen*

The spleen is enlarged with irregular peripheral contours. An approximately 2.50 – 3.00 cm ill-defined, heterogenous vascular mass effect is observed at the mid- to caudal aspect. In the remainder of the spleen, the margins are curvilinear and the parenchyma is homogenous. Splenic vasculature appears normal with no evidence of thrombosis.

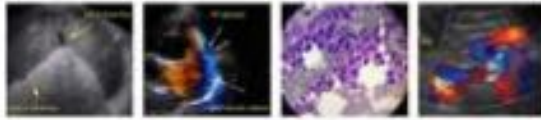
#### *Liver*

The liver is subjectively normal in size. A 1.16 cm multi-septated cystic nodule is observed deep on the left side. The lesion causes capsular expansion. In the remainder of the liver, the margins are curvilinear, the parenchyma is hypoechoic relative to the spleen, and is homogenous in appearance. Hepatic vasculature and intrahepatic biliary tracts are of normal volume with no evidence of congestion.

The gall bladder lumen is moderately distended. The wall is thin and smooth. A small amount of echogenic debris is observed within the lumen. The cystic and common bile ducts are normal/not seen.



<b>PATIENT</b>	<b>Gastrointestinal</b>
MamaKitty Forester	The stomach and intestine are free of stasis and exhibit normal peristaltic activity. The gastric lumen is not distended. The gastric wall and pylorus are normal in thickness with a normal layering pattern. The pyloric outflow tract is patent. The small intestinal lumen is not dilated. The small intestinal wall thickness is normal with a normal layering pattern and appropriate mural detail. There is disruption in the normal 1:3 muscularis: mucosal ratio in some segments. Discreet masses are not identified. The ileocecal colic junction and colonic wall are normal. No obstructive disease is noted.
<b>SPECIES</b>	
Feline	
<b>BREED</b>	<b>Pancreas</b>
DSH	The pancreas is diffusely enlarged with slightly irregular peripheral contours. The parenchyma is mildly hypoechoic relative to surrounding omental fat and diffusely mottled, bordering on nodular in appearance. No distinct focal lesions are observed. The pancreatic duct is not overtly dilated. The mesentery effacing the serosal surface is mildly hyperechoic.
<b>SEX</b>	
Female Spayed	<b>Free Abdomen</b>
<b>AGE</b>	Trace free fluid is observed. A 0.82 cm lymph node is observed in the cranial abdomen, between the liver and the stomach. A few prominent lymph nodes are also observed adjacent to the ileocecolic junction (the largest measuring 0.58 cm in length). Surrounding mesentery is hyperechoic.
11 years	
<b>WEIGHT</b>	<b>Other</b>
2.7 kg	A brief echocardiogram reveals no evidence of pericardial effusion.
<b>INTERPRETED BY</b>	<b>ULTRASONOGRAPHIC FINDINGS</b>
Andrea Nicastro, DVM, Diplomate ACVIM (Small Animal Internal Medicine)	<b>Primary Findings</b>
<b>IMAGING PERFORMED BY</b>	<ul style="list-style-type: none"> <li>Splenic mass effect. Neoplasia (i.e., round cell tumor, sarcoma) is considered likely with a lower possibility of a benign neoplastic process (i.e., inflammation, lymphoid hyperplasia, other).</li> </ul>
Loetitia Saint-Jacques, LVT	<b>Secondary Findings</b>
<b>HOSPITAL NAME</b>	<ul style="list-style-type: none"> <li>The cystic hepatic nodule is most consistent with a biliary cystadenoma with a lower possibility cystadenocarcinoma.</li> <li>Bowel pattern consistent with inflammatory bowel disease with some potential for emerging lymphoma.</li> <li>The prominent abdominal lymph nodes are most consistent with reactive lymphadenitis or lymphoid hyperplasia. Neoplastic infiltration is considered less likely.</li> <li>The pancreatic changes are most consistent with chronic active pancreatitis with suspected age-related remodeling +/- fibrosis. The nodular appearance may represent remodeling or benign nodular hyperplasia with a lower possibility of emerging neoplasia.</li> <li>Bilateral chronic age-related renal changes</li> </ul>
MountainView AH	<b>INTERPRETATION OF THE FINDINGS &amp; FURTHER RECOMMENDATIONS</b>
<b>REFERRING VET</b>	<ul style="list-style-type: none"> <li>Three-view thoracic radiographs are recommended to assess for pulmonary metastases.</li> </ul>
Dr Sarah Kalivoda	
<b>INVOICE</b>	
12887	
<b>DATE</b>	
4.27.23	



**PATIENT**

MamaKitty Forester

**SPECIES**

Feline

**BREED**

DSH

**SEX**

Female Spayed

**AGE**

11 years

**WEIGHT**

2.7 kg

**INTERPRETED BY**

Andrea Nicastro,  
DVM, Diplomate ACVIM  
(Small Animal Internal  
Medicine)

**IMAGING  
PERFORMED BY**

Loetitia Saint-Jacques,  
LVT

**HOSPITAL NAME**

MountainView AH

**REFERRING VET**

Dr Sarah Kalivoda

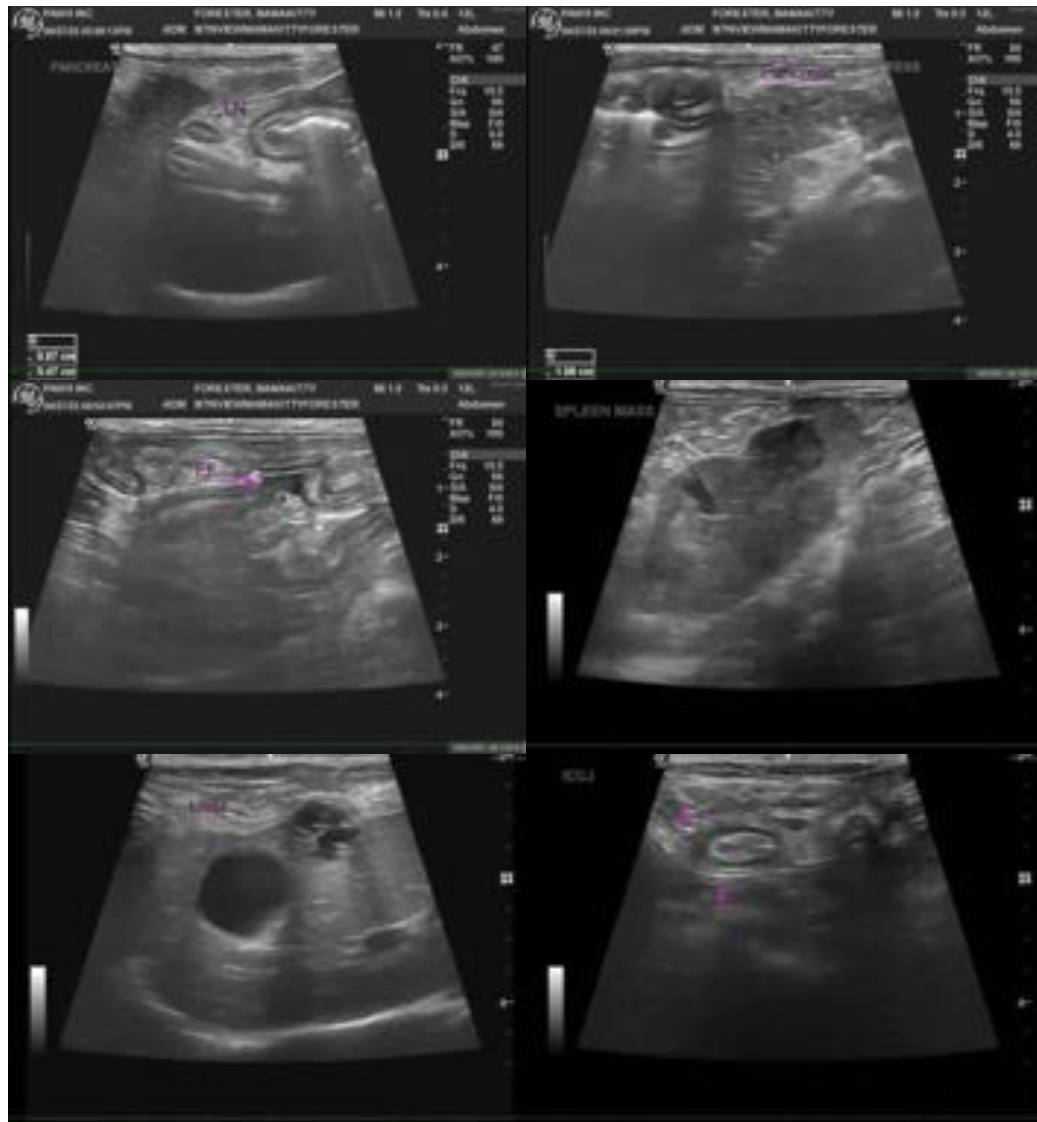
**INVOICE**

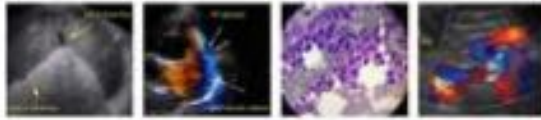
12887

**DATE**

4.27.23

- Consider a fine needle aspirate the splenic mass (if clotting status is appropriate). A 25-gauge needle should be used. If the cytology results are inconclusive, a splenectomy with submission of the spleen for histopathology may be necessary to get a definitive diagnosis. If surgery is pursued, consider obtaining GI biopsies at the time of surgery.
- A malabsorption panel, including serum cobalamin and folate, TLI and PLI should also be considered, particularly in light of the bowel and pancreatic changes seen sonographically.





**PATIENT**

MamaKitty Forester

**SPECIES**

Feline

**BREED**

DSH

**SEX**

Female Spayed

**AGE**

11 years

**WEIGHT**

2.7 kg

**INTERPRETED BY**

Andrea Nicastro,  
DVM, Diplomate ACVIM  
(Small Animal Internal  
Medicine)

**IMAGING  
PERFORMED BY**

Loetitia Saint-Jacques,  
LVT

**HOSPITAL NAME**

MountainView AH

**REFERRING VET**

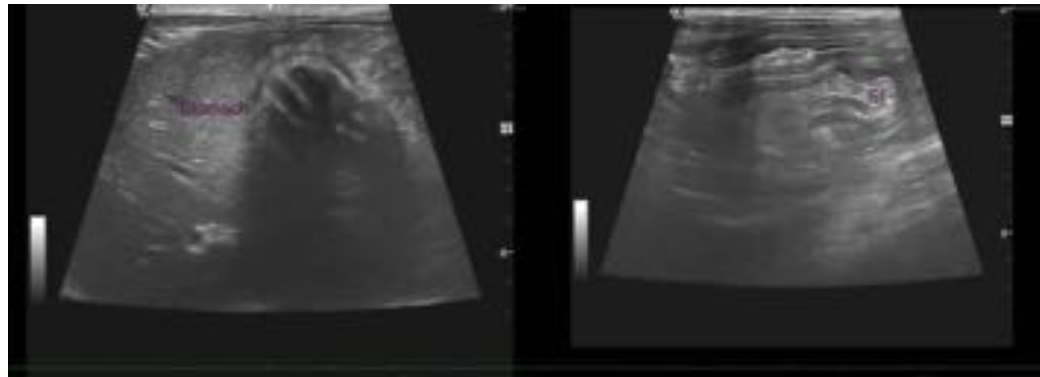
Dr Sarah Kalivoda

**INVOICE**

12887

**DATE**

4.27.23



The information and recommendations provided are based on the images presented by the referring veterinarian/sonographer. No evaluation can be communicated regarding pathology that was not visible in the image/video clips provided.

Thank you for this referral. If the clinical or image interpretation does not parallel your findings or if I can be of any further assistance, please contact me.

**Andrea Nicastro, MPH, DVM, Diplomate DACVIM (Small Animal Internal Medicine)**  
[info@SonoPath.com](mailto:info@SonoPath.com)