



PATIENT PRESENTING CLINICAL SIGNS

Simba Ackerson History: Enlarged abdomen, stomach and right kidney.

SPECIES ULTRASONOGRAPHIC EXAMINATION OF THE ABDOMEN

Feline

Urinary System

The urinary bladder, trigone, and pelvic urethra are normal in thickness and the mucosal surface is smooth. The bladder lumen is moderately distended with anechoic urine. No masses, inflammatory changes or calculi are observed. Ureteral papillae and visualized portion of the proximal urethra, visible to a depth of 2 cm, are normal.

BREED

DSH

SEX

Intact Male

The left kidney is normal size (3.44 cm in length); normal shape and architecture with smooth peripheral margins. There is a normal 1:3 cortex to medulla ratio with normal corticomedullary distinction. There is no evidence of pyelectasia, nephroliths, infarcts or hydronephrosis. Renal vasculature is normal.

AGE

9 weeks

The right kidney is normal size (3.35 cm in length); normal shape and architecture with smooth peripheral margins. There is a normal 1:3 cortex to medulla ratio with normal corticomedullary distinction. There is no evidence of pyelectasia, nephroliths, infarcts or hydronephrosis. Renal vasculature is normal.

WEIGHT

-

Adrenal Glands

The region of the adrenal glands is evaluated. No obvious pathology is observed.

Spleen

The spleen is normal in size (0.65 cm in width at the level of the hilus) with a normal capsular contour. There is appropriate echogenicity and echotexture. No focal lesions are observed. Splenic vasculature is normal.

INTERPRETED BY

Andrea Nicastro, DVM,
Diplomate ACVIM (*Small Animal Internal Medicine*)

IMAGING PERFORMED BY

Kelly Vazquez

Liver

The liver is subjectively normal in size with normal contours and structure. There is appropriate echogenicity and echotexture. No overt structural evidence of inflammatory, infiltrative, or regenerative pathology is evident. Vascular and biliary tracts are of normal volume with no evidence of congestion. No pathological hepatic lymphadenopathy observed. The portal vein to caudal vena cava ratio is approximately 1: 1, making a congenital extrahepatic portosystemic shunt unlikely.

HOSPITAL NAME

Westwood Regional VH

The gall bladder lumen is moderately distended. The wall is thin and smooth. Luminal contents are anechoic. The cystic and common bile ducts are normal.

Gastrointestinal

The gastric lumen is minimally distended with fluid. The gastric wall is normal in thickness with a normal layering pattern. The small intestinal lumen is not dilated. The small intestinal wall thickness is normal with a normal layering pattern and appropriate mural detail. Discreet masses are not identified. The colonic wall is normal. No obstructive disease is noted.

REFERRING VET

Dr. Silver

INVOICE

10815

Pancreas

The left limb/base is visible/prominent with minimal deviation from the normal peripheral contours. The parenchyma is slightly hypoechoic relative to surrounding omental fat. No distinct focal lesions are observed. The pancreatic duct is not overtly dilated.

DATE

4/27/22

Free Abdomen

Trace free fluid is observed. a few prominent lymph nodes are observed in the cranial abdomen, the largest measuring 0.83 cm in length.



PATIENT

Simba Ackerson

SPECIES

Feline

BREED

DSH

SEX

Intact Male

AGE

9 weeks

WEIGHT

-

INTERPRETED BY

Andrea Nicastro, DVM,
Diplomate ACVIM (*Small Animal Internal Medicine*)

IMAGING PERFORMED BY

Kelly Vazquez

HOSPITAL NAME

Westwood Regional VH

REFERRING VET

Dr. Silver

INVOICE

10815

DATE

4/27/22

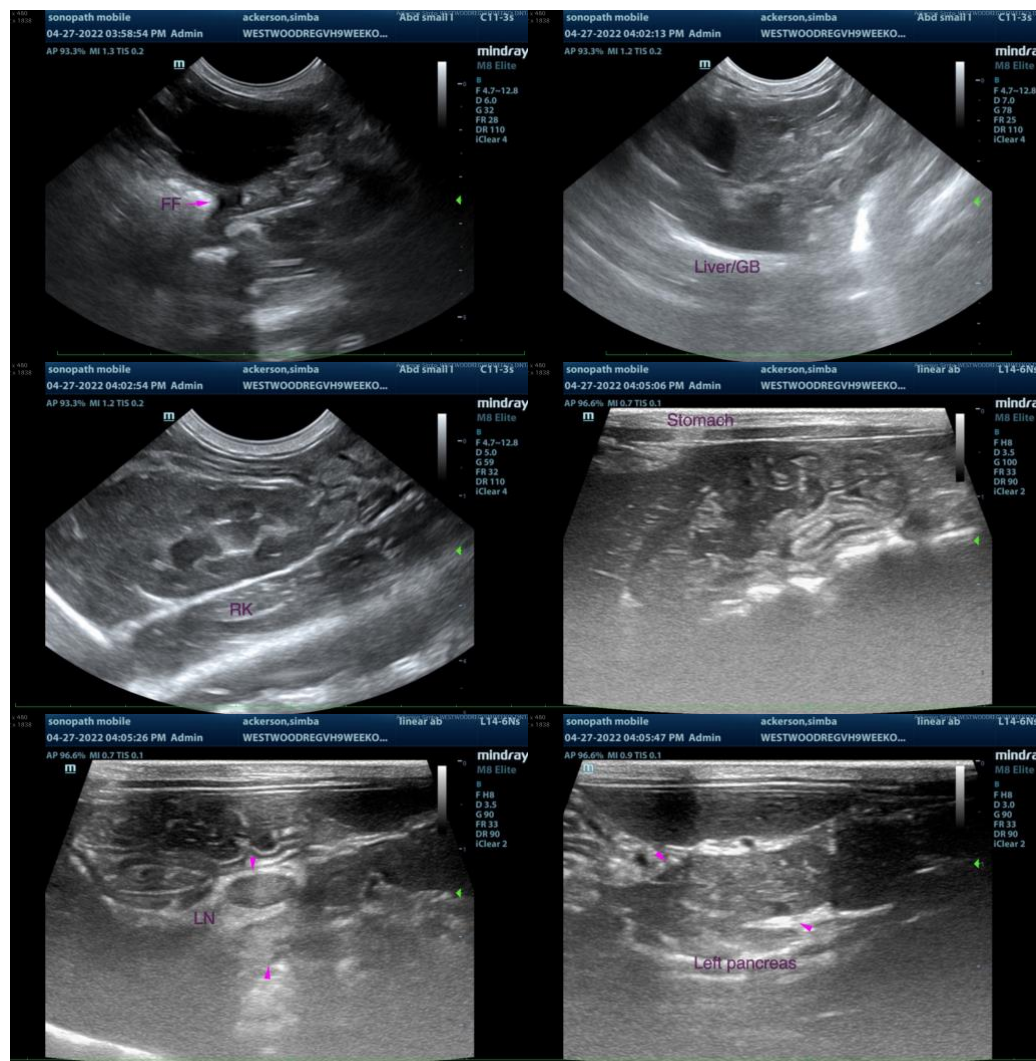
ULTRASONOGRAPHIC FINDINGS

Primary Findings

- The abdominal lymphadenopathy could be consistent with immunologic immaturity, reactive lymphadenitis or lymphoid hyperplasia. Infiltrative neoplasia is possible but considered unlikely.
- The pancreatic changes are likely a normal variant for this patient. They could be secondary to low-grade pancreatitis, but this would be unusual in a patient of this age.
- Trace ascites, likely incidental.

INTERPRETATION OF THE FINDINGS & FURTHER RECOMMENDATIONS

- Further recommendations should be based on the patient's clinical signs.





PATIENT

Simba Ackerson

SPECIES

Feline

BREED

DSH

SEX

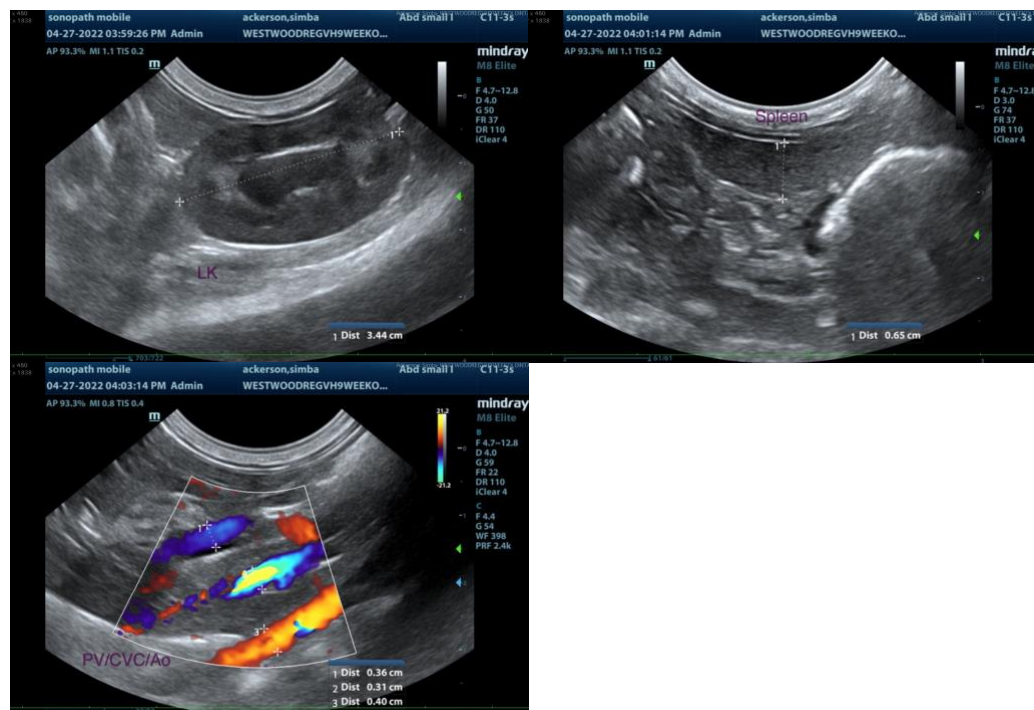
Intact Male

AGE

9 weeks

WEIGHT

-



INTERPRETED BY

Andrea Nicastro, DVM,
Diplomate ACVIM (*Small Animal Internal Medicine*)

IMAGING PERFORMED BY

Kelly Vazquez

HOSPITAL NAME

Westwood Regional VH

REFERRING VET

Dr. Silver

INVOICE

10815

DATE

4/27/22

The information and recommendations provided are based on the images presented by the referring veterinarian/sonographer. No evaluation can be communicated regarding pathology that was not visible in the image/video clips provided.

Thank you for this referral. If the clinical or image interpretation does not parallel your findings or if I can be of any further assistance, please contact me.

Andrea Nicastro, DVM, Diplomate DACVIM (Small Animal Internal Medicine)
info@SonoPath.com