



**PATIENT**

Courage Shivdasani

**SPECIES**

Canine

**BREED**

Mixed breed

**SEX**

Female, spayed

**AGE**

12 Yrs.

**WEIGHT**

41.8 lbs.

**INTERPRETED BY**

Andrea Nicastro, DVM,  
Diplomate ACVIM  
(Small Animal Internal  
Medicine)

**IMAGING  
PERFORMED BY**

Jessica Miller

**HOSPITAL NAME**

Summit Dog and Cat

**REFERRING VET**

Dr. Vogler

**INVOICE**

13284

**DATE**

4/27/22

**PRESENTING CLINICAL SIGNS**

History: Elevation in ALT and ALP values and decreased PLTs.  
Abnormal PE/Chem/CBC/UA Results: NEUT 81%, Platelets  $7 \times 10^3$ , Abs Neuts 11745, ALKP 351, ALT 416, CK 52, PSL LIPA 22

**ULTRASONOGRAPHIC EXAMINATION OF THE ABDOMEN**

*Urinary System*

The urinary bladder and visible portion of the pelvic urethra are normal for the degree of luminal distension. The urine is anechoic with no evidence of debris. Cystic calculi and discrete masses are not observed. The region of the trigone and the proximal urethra, visible to a depth of 2 cm, are normal. The mucosal surface is slightly irregular.

The left kidney is normal size (5.39 cm in length); normal shape and architecture with smooth peripheral margins. There is a normal 1:3 cortex to medulla ratio with mild to moderate loss of corticomedullary distinction. There is no evidence of pyelectasia, nephroliths, infarcts or hydronephrosis. Renal vasculature is normal.

The right kidney is normal size (4.57 cm in length); normal shape and architecture with smooth peripheral margins. There is a normal 1:3 cortex to medulla ratio with mild to moderate loss of corticomedullary distinction. There is no evidence of pyelectasia, nephroliths, infarcts or hydronephrosis. Renal vasculature is normal.

*Adrenal Glands*

The left adrenal gland is enlarged at the cranial pole and normal in size at the caudal pole (1.53 cm at cranial pole) (0.68 cm at caudal pole) (2.95 cm in length). A 1.78 x 1.38 cm hyperechoic to slightly heterogeneous nodule is observed at the cranial aspect. The glandular echogenicity and detail at the caudal aspect are unremarkable. The phrenicoabdominal vein and surrounding vasculature are normal.

The right adrenal gland is normal size (1.25 cm at cranial pole) (0.47 cm at caudal pole) (2.02 cm in length); normal shape; homogenous parenchyma. A 0.44 x 0.34 cm hyperechoic nodule is observed at the cranial pole. The remaining glandular echogenicity and detail are unremarkable. The phrenicoabdominal vein and surrounding vasculature are normal.

*Spleen*

The spleen is normal in size (1.77 cm in width at the level of the hilus) with a normal capsular contour. The parenchyma is mildly heterogeneous in appearance. No focal lesions are observed. Splenic vasculature is normal.

*Liver*

The liver is subjectively normal in size with normal contours and structure. There is appropriate echogenicity and echotexture. No overt structural evidence of inflammatory, infiltrative or regenerative pathology is evident. Vascular and biliary tracts are of normal volume with no evidence of congestion. No pathological hepatic lymphadenopathy observed. The gall bladder lumen is moderately distended. The wall is thin and smooth. Luminal contents are anechoic. The cystic and common bile ducts are normal/not seen.

*Gastrointestinal*



**PATIENT**

Courage Shivdasani

The stomach and intestine are free of stasis and exhibit normal peristaltic activity. The gastric lumen is not distended. The gastric wall and pylorus are normal in thickness with a normal layering pattern. The pyloric outflow tract is patent. The small intestinal lumen is not dilated. The small intestinal wall thickness is normal with a normal layering pattern and appropriate mural detail. Discreet masses are not identified. The colonic wall is normal. No obstructive disease is noted.

**SPECIES**

Canine

***Pancreas***

The region of the pancreas is isoechoic relative to surrounding omental fat. No obvious parenchymal abnormalities are observed. There is no evidence of regional inflammation or effusion.

**BREED**

Mixed breed

***Free Abdomen***

The peritoneal cavity is normal. There is no evidence of inflammation or effusion. The abdominal lymph nodes are normal/not visible.

**SEX**

Female, spayed

**AGE**

12 Yrs.

**ULTRASONOGRAPHIC FINDINGS**

- The splenic parenchymal changes are non-specific and could be associated with antigenic stimulation, lymphoid hyperplasia, extramedullary hematopoiesis, splenitis or less likely, infiltrative neoplasia (i.e., round cell tumor).
- The bilateral adrenal nodules trend toward the benign (i.e., nodular hyperplasia). However, a unilateral or bilateral tumors cannot be completely excluded.
- Bilateral, chronic age-related renal changes.

**WEIGHT**

41.8 lbs.

**INTERPRETED BY**

Andrea Nicastro, DVM,  
Diplomate ACVIM  
(*Small Animal Internal  
Medicine*)

\*An obvious cause for the elevated liver enzymes is not identified in the study. However, a microscopic hepatopathy (i.e., bacterial cholangiohepatitis, Leptospirosis, chronic active hepatitis, copper-associated hepatotoxicity, reactive hepatopathy, thromboembolic disease, infiltrative neoplasia (less likely)) should be considered.

**INTERPRETATION OF THE FINDINGS & FURTHER RECOMMENDATIONS**

- Leptospirosis testing (i.e., blood and urine PCR, serology) and pre- and post-prandial serum bile acids are recommended. While awaiting test results, consider empirical treatment for bacterial cholangiohepatitis (i.e., amoxicillin clavulanic acid +/- metronidazole, Denamarin).
- Given the severe thrombocytopenia, consider a comprehensive tick panel (send to NC State) as well as three-view thoracic radiographs to assess for occult neoplasia in the chest.
- If the platelet count stabilizes and if hepatic enzymes are still elevated, hepatic tissue sampling (i.e., fine needle aspirate or surgical biopsy) can be considered. Surgical biopsies are preferred in that they are more likely to yield a definitive diagnosis. Aerobic and anaerobic bile cultures and additional hepatic tissue samples for potential copper quantitation should also be obtained.
- Consider testing for hyperadrenocorticism with a low-dose dexamethasone suppression test or ACTH stimulation test if clinical signs (i.e., PU/PD) develop in the future.
- A repeat abdominal ultrasound can be considered in 3 months to assess for progression of the adrenal nodules.

**IMAGING PERFORMED BY**

Jessica Miller

**HOSPITAL NAME**

Summit Dog and Cat

**REFERRING VET**

Dr. Vogler

**INVOICE**

13284

**DATE**

4/27/22



**PATIENT**

Courage Shivasani

**SPECIES**

Canine

**BREED**

Mixed breed

**SEX**

Female, spayed

**AGE**

12 Yrs.

**WEIGHT**

41.8 lbs.

**INTERPRETED BY**

Andrea Nicastro, DVM,  
Diplomate ACVIM  
(Small Animal Internal  
Medicine)

**IMAGING  
PERFORMED BY**

Jessica Miller

**HOSPITAL NAME**

Summit Dog and Cat

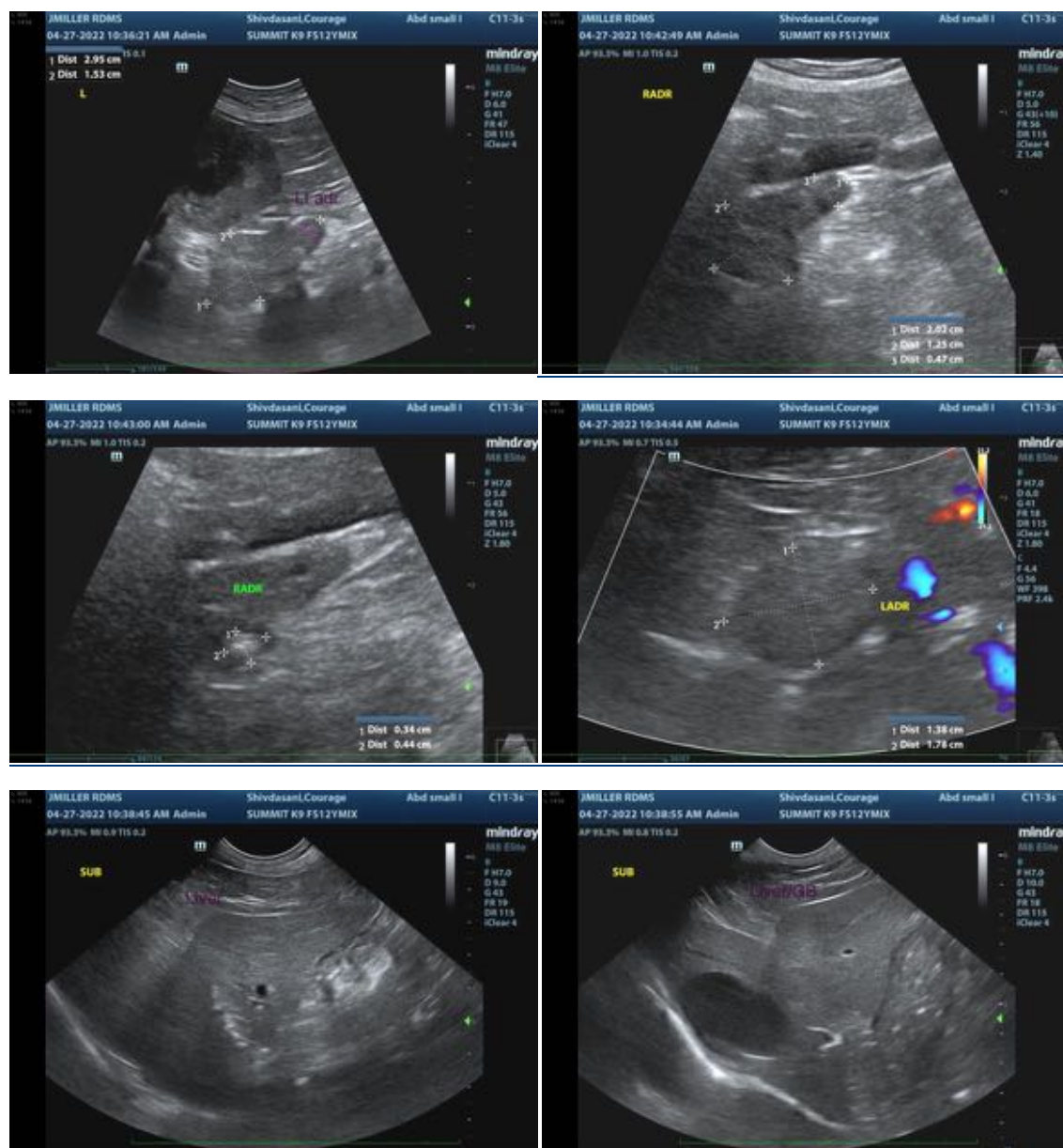
**REFERRING VET**

Dr. Vogler

**INVOICE**

13284

**DATE**  
4/27/22



The information and recommendations provided are based on the images presented by the referring veterinarian/sonographer. No evaluation can be communicated regarding pathology that was not visible in the image/video clips provided.

Thank you for this referral. If the clinical or image interpretation does not parallel your findings or if I can be of any further assistance please contact me.

Andrea Nicastro, DVM, Diplomate ACVIM (Small Animal Internal Medicine)

Andrea.nicastro@sonopath.com