



PATIENT

Bianca Masciulli

SPECIES

Canine

BREED

Havanese

SEX

Female, spayed

AGE

14.5 Yrs.

WEIGHT

10.6 lbs.

INTERPRETED BY

Andrea Nicastro, DVM,
Diplomate ACVIM
(*Small Animal Internal
Medicine*)

**IMAGING
PERFORMED BY**

Amy Mayhew

HOSPITAL NAME

SVS Imaging Michigan

REFERRING VET

Dr. Foster

INVOICE

14858

DATE

4/26/23

PRESENTING CLINICAL SIGNS

History: Pawing at the mouth, easier time with softer food
Abnormal PE/Chem/CBC/UA Results: Grade 2-3 dental disease present Blood work/UA revealed mild azotemia, with BUN 38 (6-31mg/dL), SDMA 14.9 (<14.0 UG/dL) and USG 1.027.

4DX negative, trace proteinuria

ULTRASONOGRAPHIC EXAMINATION OF THE ABDOMEN

Urinary System

The urinary bladder and visible portion of the pelvic urethra are normal for the degree of luminal distension. The urine is anechoic with no evidence of debris. Cystic calculi and discrete masses are not observed. The region of the trigone and the visible portion of the proximal urethra are normal.

The left kidney is normal in size (3.54 cm in length) with a normal shape, smooth peripheral margins and normal internal architecture. There is mild loss of corticomedullary distinction. Several hyperechoic shadowing diverticular foci are observed. Mild to moderate pyelectasia is present (0.37 cm in the transverse plane). There is no evidence of infarcts or hydronephrosis.

The right kidney is normal in size (3.99 cm in length) with a normal shape, smooth peripheral margins and normal internal architecture. There is mild loss of corticomedullary distinction. Several hyperechoic shadowing diverticular foci are observed. There is no evidence of pyelectasia, infarcts or hydronephrosis.

Adrenal Glands

The left adrenal gland is borderline enlarged (0.55 cm at cranial pole) (0.56 cm at caudal pole); normal shape; homogenous parenchyma. The glandular echogenicity and detail are unremarkable. Capsule, cortex, and medullary definition are normal. The phrenicoabdominal vein and surrounding vasculature are normal.

The right adrenal gland is mildly enlarged (0.87 cm at cranial pole) (0.65 cm at caudal pole); normal shape; homogenous parenchyma. The glandular echogenicity and detail are unremarkable. Capsule, cortex, and medullary definition are normal. The phrenicoabdominal vein and surrounding vasculature are normal.

Spleen

The spleen is subjectively normal in size (0.96 cm in width at the level of the hilus). A 0.91 cm hypoechoic nodule is observed at the cranial aspect. The lesion causes slight capsular expansion. The remaining peripheral margins are curvilinear. The remaining parenchyma is homogeneous. Splenic vasculature is normal with no obvious evidence of thrombosis.

Liver

The liver is subjectively normal in size with normal curvilinear peripheral contours. The parenchyma is hypoechoic relative to the spleen. A 2.64 cm isoechoic mass/lesion is observed adjacent to the diaphragm. In addition, a 0.63 hypoechoic nodule is seen on the right side and a 0.78 cm hyperechoic nodule is seen at the caudal aspect. A 0.73 cm cyst is visualized in the caudate process. Vascular and biliary tracts are of normal volume with no evidence of congestion. The gallbladder is of normal contours and contains some dependent echogenic debris. The wall is normal in thickness. No choleliths



PATIENT

are observed. The cystic and common bile ducts are normal.

Bianca Masciulli

Gastrointestinal

SPECIES

The stomach and intestine are free of stasis and exhibit normal peristaltic activity. The gastric lumen is not distended. The gastric wall and pylorus are normal in thickness with a normal layering pattern. The pyloric outflow tract is patent. The small intestinal lumen is not dilated. The small intestinal wall thickness is normal with a normal layering pattern and appropriate mural detail. Discreet masses are not identified. The colonic wall is normal. No obstructive disease is noted.

Canine

BREED

Pancreas

Havanese

The left limb of the pancreas is visible with normal curvilinear peripheral contours. The parenchyma is largely isoechoic relative to surrounding omental fat and slightly mottled in appearance. The pancreatic duct is visible but not overtly dilated. There is no evidence of peripancreatic inflammation or effusion.

SEX

Female, spayed

Free Abdomen

AGE

There is no obvious evidence of free fluid. The abdominal lymph nodes are normal/not visible.

14.5 Yrs.

ULTRASONOGRAPHIC FINDINGS

WEIGHT

Primary Findings:

10.6 lbs.

- Bilateral chronic renal changes with dystrophic mineralization. The left pyelectasia may be secondary to pyelonephritis, age-related remodeling, PU/PD (if applicable) or some combination thereof.
- The splenic nodule is concerning for an emerging tumor (i.e., sarcoma, round cell tumor). However, a focal benign lesion (i.e., inflammatory focus, lymphoid hyperplasia, extramedullary hematopoiesis or similar) is also possible.
- The hepatic mass/lesion adjacent to the diaphragm may represent an emerging tumor, regenerative nodule, inflammatory focus, granuloma, other. The other smaller hepatic nodules trend toward the benign (i.e., regenerative nodules) with a lower possibility of more insidious hepatic pathology.

INTERPRETED BY

Andrea Nicastro, DVM,
Diplomate ACVIM
(*Small Animal Internal
Medicine*)

**IMAGING
PERFORMED BY**

Amy Mayhew

HOSPITAL NAME

Secondary Findings:

- Minor, age-related pancreatic remodeling.
- Borderline bilateral adrenomegaly.

SVS Imaging Michigan

REFERRING VET

Dr. Foster

INTERPRETATION OF THE FINDINGS & FURTHER RECOMMENDATIONS

INVOICE

14858

- Given the patient's clinical history and bilateral renal changes, a urine culture and sensitivity is recommended as well as a baseline blood pressure measurement. Also consider transitioning to a prescription renal diet. Serial monitoring (i.e., every 3 months) of the patient's renal values is recommended to assess for progressive azotemia. If the patient is to undergo anesthesia, IV fluid diuresis is recommended for at least several hours prior to anesthesia, during the procedure and for several hours post procedure to ensure adequate renal profusion.

DATE

4/26/23



PATIENT

Bianca Masciulli

- Although unlikely, given the azotemia, consider screening for hypoadrenocorticism with a resting cortisol level.

SPECIES

Canine

- Regarding the splenic and hepatic nodules, consider fine needle aspirates, if clotting status is appropriate and if accessible. 25-gauge needles should be used. If tissue samples are not obtained at his time, consider a recheck ultrasound in 4-6 weeks to assess for growth of the lesions.

BREED

Havanese

SEX

Female, spayed

AGE

14.5 Yrs.

WEIGHT

10.6 lbs.

INTERPRETED BY

Andrea Nicastro, DVM,
Diplomate ACVIM
(Small Animal Internal
Medicine)

IMAGING PERFORMED BY

Amy Mayhew

HOSPITAL NAME

SVS Imaging Michigan

REFERRING VET

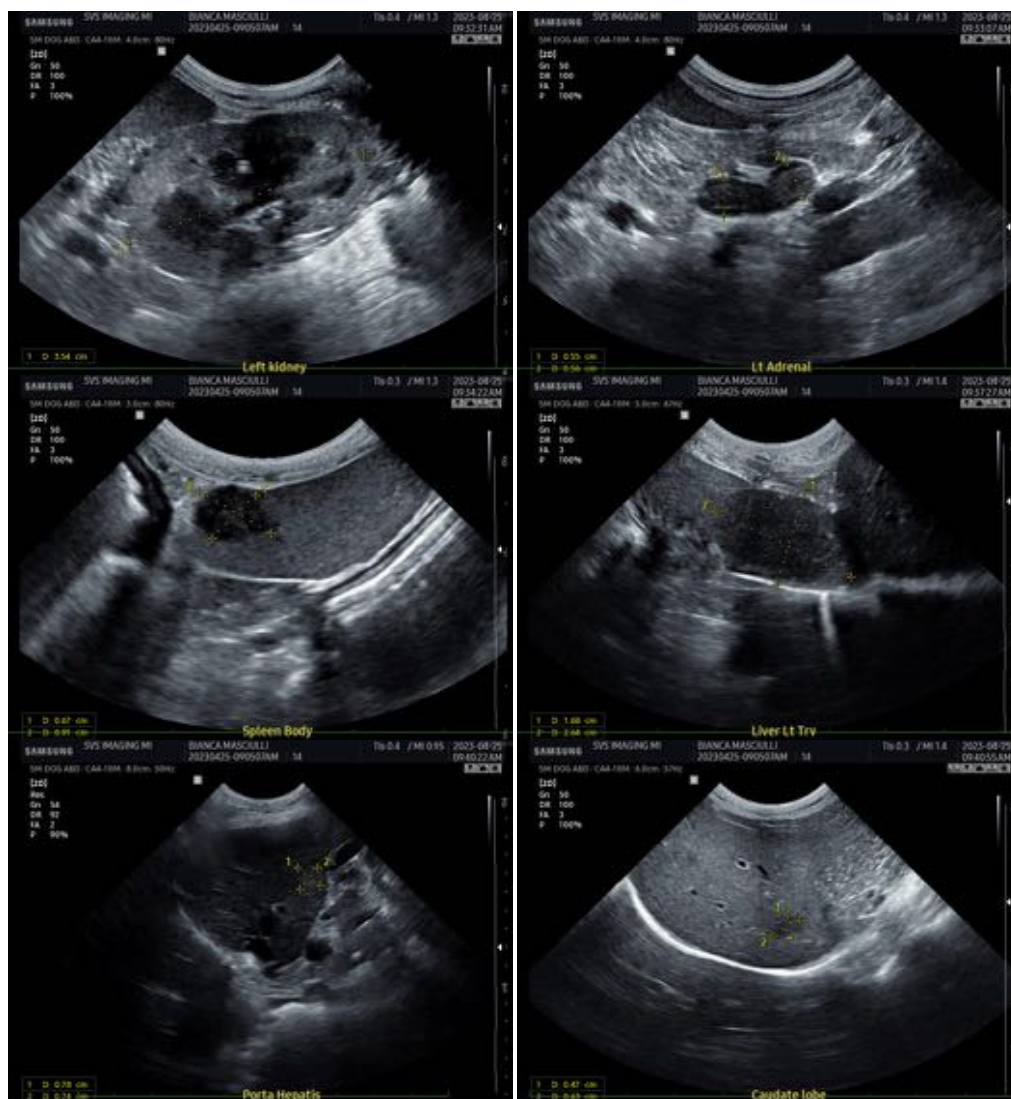
Dr. Foster

INVOICE

14858

DATE

4/26/23





PATIENT

Bianca Masciulli

SPECIES

Canine

BREED

Havanese

SEX

Female, spayed

AGE

14.5 Yrs.

WEIGHT

10.6 lbs.

INTERPRETED BY

Andrea Nicastro, DVM,
Diplomate ACVIM
(Small Animal Internal
Medicine)

**IMAGING
PERFORMED BY**

Amy Mayhew

HOSPITAL NAME

SVS Imaging Michigan

REFERRING VET

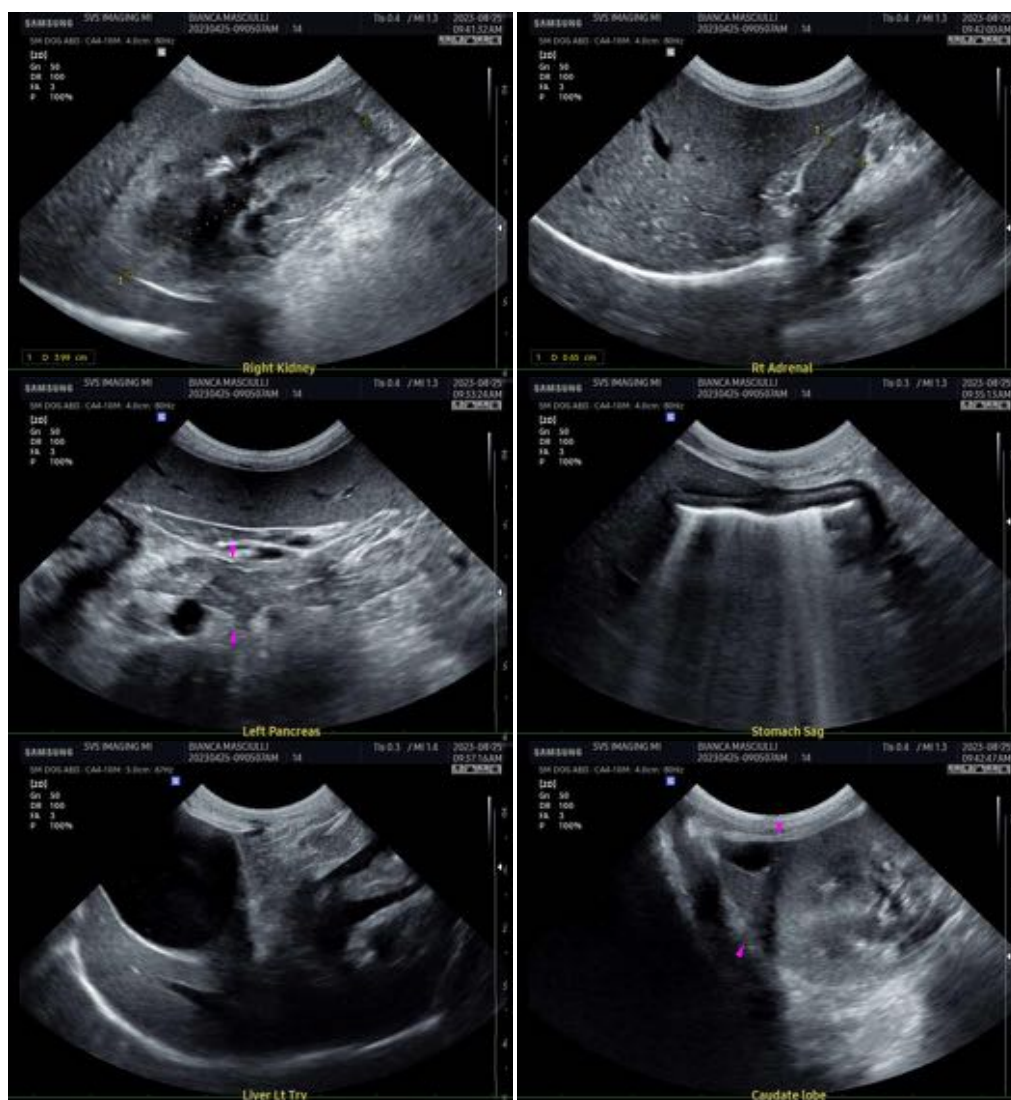
Dr. Foster

INVOICE

14858

DATE

4/26/23



The information and recommendations provided are based on the images presented by the referring veterinarian/sonographer. No evaluation can be communicated regarding pathology that was not visible in the image/video clips provided.

Thank you for this referral. If the clinical or image interpretation does not parallel your findings or if I can be of any further assistance please contact me.

Andrea Nicastro, MPH, DVM, Diplomate DACVIM (Small Animal Internal Medicine)
info@SonoPath.com