

**DATE PRESENTING CLINICAL SIGNS**

4/26/22

Was seen at ER on 3/26 for wound of unknown origin on the L thigh. Liver enzymes at that time were elevated. Pathology of the lesion came back as neutrophilic histiocytic panniculitis with fibrosis – no obvious etiologic agents noted. We have been seeing pet weekly for bandage changes as area is healing by second intension. We repeated LE last week and although improved still elevated. Pet was otherwise doing well. Urine cortisol/creat ration was very elevated . Pet presented today for lethargy, vomiting and diarrhea. Repeat labs showed still elevated alp and now elevated BUN, phosphorous. Can palpate some cranial organomegaly, pet also had bloody, crusty vaginal discharge and suspected UTI.

PATIENT

Skylar Buscemi

SPECIES

Canine

Current Medications: Cerenia inj - 3.3 ml, Metronidazole 500 mg BID (started 4/25), Amoxicillin 400 mg - 1.5 BID (started 4/25).

BREED

Husky

Lab Results: 3/26- ALT 247, ALP 4509, BUN 19 (normal), Creat 0.9 (normal), rest of small chem 10 and CBC WNL. 4/19- ALT 157, ALP 3030
4/25- WBC 18200, neut 15780, BUN 62, Creat 1.6 (still normal but up from last check), Phos 8.2, ALP >2000 (didn't dilute), ALT 106 (normal), CL 105 rest of CBC and Chem 17 wnl. Sedivue UA via cysto - RBC 16 per field, cocci present, glucose 50, , ket 15, ph 7.0, USG 1.024

SEX

Female, spayed

Date of Previous IntraPet Ultrasound: No previous.
Sedation: Not required to complete full diagnostic ultrasound.
Stat Report: Not requested.

AGE

3/28/2013

Imaging Performed By: Andi Parkinson, RDMS.

WEIGHT

73 lbs.

ULTRASONOGRAPHIC EXAMINATION OF THE ABDOMEN**Urinary System**

The urinary bladder, trigone, and pelvic urethra are normal in thickness and the mucosal surface is smooth. The bladder lumen is moderately distended with anechoic urine. No masses, inflammatory changes or calculi are observed. The region of the trigone is normal.

INTERPRETED BY

Andrea Nicastrò, DVM,
Diplomate ACVIM
(Small Animal Internal
Medicine)

The left kidney is normal size (7.35 cm in length); normal shape and architecture with smooth peripheral margins. There is a normal 1:3 cortex to medulla ratio with normal corticomedullary distinction. There is no evidence of pyelectasia, nephroliths, infarcts or hydroureter.

HOSPITAL NAME

Greenbrier VC

The right kidney is normal size (7.44 cm in length); normal shape and architecture with smooth peripheral margins. There is a normal 1:3 cortex to medulla ratio with normal corticomedullary distinction. There is no evidence of pyelectasia, nephroliths, infarcts or hydroureter.

REFERRING VET

Dr. Boccanfuso

Adrenal Glands

The left adrenal gland is mildly enlarged (0.85 cm at cranial pole) (0.93 cm at caudal pole) (3.36 cm in length); normal shape; homogenous parenchyma. The glandular echogenicity and detail are unremarkable. Capsule, cortex, and medullary definition are normal. The phrenicoabdominal vein and surrounding vasculature are normal.

INVOICE

13276

The right adrenal gland is upper limits of normal size (0.95 cm at cranial pole) (0.83 cm at caudal pole) (3.57 cm in length); normal shape; homogenous parenchyma. The glandular echogenicity and detail are unremarkable. Capsule, cortex, and medullary definition are normal. The phrenicoabdominal vein and surrounding vasculature are normal.

Spleen

The spleen is normal in size (1.40 cm in width at the level of the hilus) with a normal capsular contour. There is appropriate echogenicity and echotexture. No focal lesions are observed. Splenic vasculature is normal.

Liver

The liver is subjectively enlarged with slightly swollen peripheral contours. The parenchyma is hyperechoic relative to the spleen and diffusely homogeneous in appearance. No distinct focal lesions are observed. Vascular and biliary tracts are of normal volume with no evidence of congestion. The gall bladder lumen is moderately distended. The wall is thin and smooth. Luminal contents are anechoic. The cystic and common bile ducts are normal/not seen.

Gastrointestinal

The stomach and intestine are free of stasis and exhibit normal peristaltic activity. The gastric lumen is minimally fluid distended. The gastric wall and pylorus are normal in thickness with a normal layering pattern. The pyloric outflow tract is patent. The small intestinal lumen is not dilated. The small intestinal wall thickness is normal with a normal layering pattern and appropriate mural detail. Discreet masses are not identified. The colonic wall is normal. No obstructive disease is noted.

Pancreas

The left limb and base are prominent to enlarged with slightly irregular peripheral contours. The parenchyma is hypoechoic relative to surrounding omental fat. No distinct focal lesions are observed. The pancreatic duct is not overtly dilated. The surrounding mesentery is hyperechoic. A small amount of peripancreatic effusion is present.

Free Abdomen

Trace free fluid is observed in the cranial abdomen. The abdominal lymph nodes are normal/not visible.

ULTRASONOGRAPHIC FINDINGS

Primary Findings:

- The pancreatic changes are consistent with mild to moderate acute pancreatitis with regional peritonitis.
- The diffuse hepatic parenchymal changes are non-specific and, in conjunction with the liver enzyme pattern, are most consistent with a benign hepatopathy (i.e., vacuolar hepatopathy or regenerative nodular hyperplasia). Inflammatory disease is considered less likely given the normal ALT. Infiltrative neoplasia (i.e., lymphoma) is possible but considered less likely in this patient.

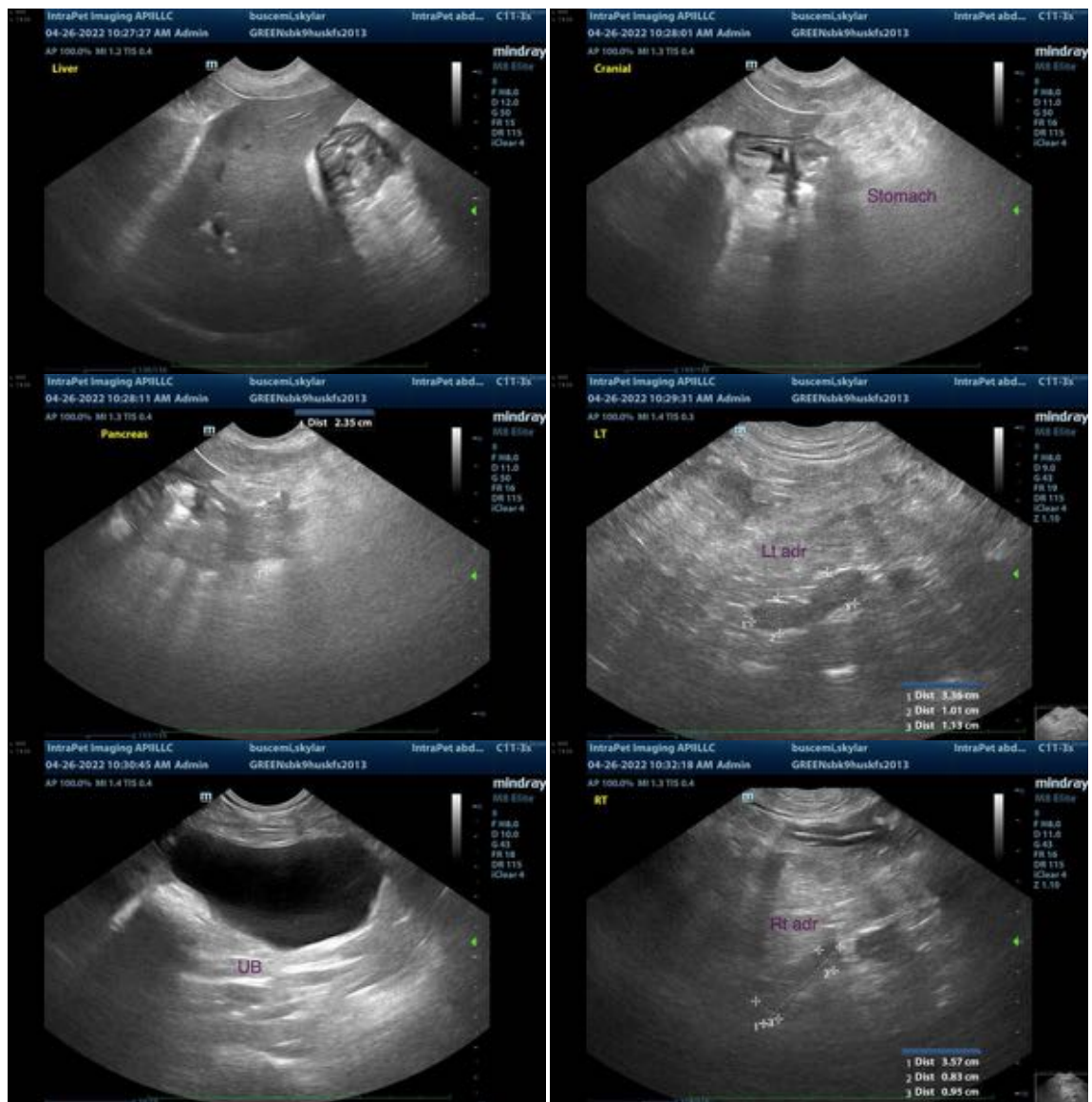
Secondary Findings:

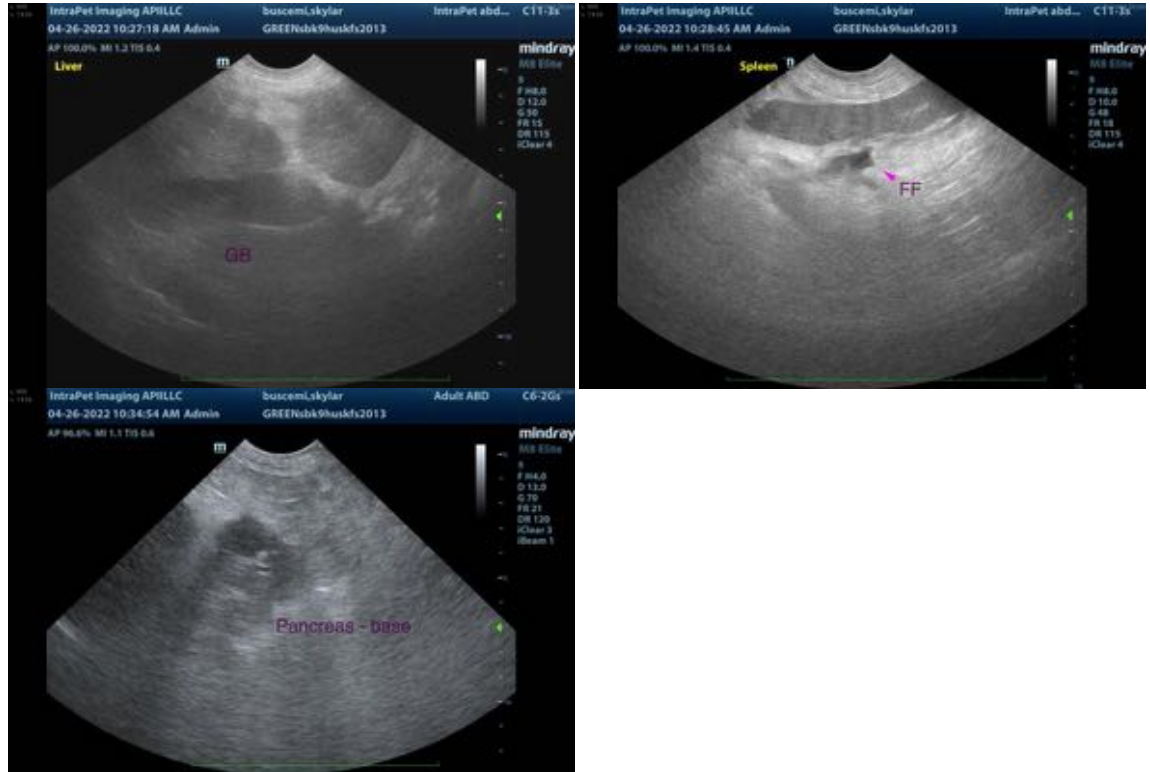
- Mild left adrenomegaly.

INTERPRETATION OF THE FINDINGS & FURTHER RECOMMENDATIONS

- Supportive care for pancreatitis is recommended including IV fluid therapy, gastric protectants, antiemetics, pain medication as needed, +/- fresh frozen plasma.
- Thoracic radiographs are recommended, as pancreatitis can sometimes result in pulmonary pathology.
- When the patient is eating again, a prescription low fat diet is recommended long term to help prevent pancreatitis flare ups.

- A urine culture and sensitivity is recommended, preferably on a pre-antibiotic sample or on a sample collected 5-7 days after the last dose of antibiotics.
- Serial monitoring of the patient's renal values is recommended to assess for progression of azotemia. Also consider a baseline blood pressure measurement.
- Consider testing for hyperadrenocorticism with a low-dose dexamethasone suppression test or ACTH stimulation test if clinical signs (i.e., PU/PD) develop in the future.





The information and recommendations provided are based on the images presented by the referring veterinarian. No evaluation can be communicated regarding pathology that was not visible in the image/video clips provided.

Thank you for this referral. If the clinical or image interpretation does not parallel your findings or if I can be of any further assistance please contact me.

Andrea Nicastro, DVM, Diplomate ACVIM (*Small Animal Internal Medicine*)
Andrea.nicastro@sonopath.com