

**DATE**

4/26/22

PATIENT

Baby Andy Gilpin

SPECIES

Canine

BREED

Tibetan spaniel

SEX

Male, neutered

AGE

12/7/2015

WEIGHT

17.7 lbs.

INTERPRETED BY

Andrea Nicastro, DVM,
 Diplomate ACVIM
 (Small Animal Internal
 Medicine)

HOSPITAL NAME

Hickory VH

REFERRING VET

Dr. McNesby

INVOICE

13278

PRESENTING CLINICAL SIGNS

Patient presented to AEH for vomiting/bloody diarrhea of less than 24 hours duration. Abdominal rads revealed fluid filled bowel loops, bloodwork, mild elevation in BUN, phosphorous, wbc count which responded to symptomatic treatment with IV fluids and antibiotics. Pet did well for approx. 1 month, then presented today with a 1 day history of lethargy and inappetence. Physical exam revealed mildly pain on abdominal palpation and a diffuse swelling in the right axillary region that owner reports has waxed and waned in size. Labwork revealed elevated WBC count, Snap CPL normal. FNA of mass : tentative for mast cell tumor - cytology pending. Treatment: SQ fluids, SQ cerenia, Amoxicillin and Cerenia TGH.

Current Medications: Amoxicillin 250 mg PO BID (started 4/22/22), Cerenia 16 mg Q24 hours (started 4/22/22), Simparica Trio - last given 3/23/22.

Date of Previous IntraPet Ultrasound: No previous.

Sedation: Not required to complete full diagnostic ultrasound.

Stat Report: Not requested.

Imaging Performed By: Andi Parkinson, RDMS.

ULTRASONOGRAPHIC EXAMINATION OF THE ABDOMEN**Urinary System**

The urinary bladder, trigone, and pelvic urethra are normal in thickness and the mucosal surface is smooth. The bladder lumen is moderately distended with mostly anechoic urine. No masses, inflammatory changes or calculi are observed. Ureteral papillae and visualized portion of the proximal urethra, visible to a depth of 2 cm, are normal.

The prostate is prominent in size for the patient's weight (1.41 cm in width) with a normal shape and smooth peripheral contours. The parenchyma is homogeneous. No focal lesions are observed. The prostatic urethra is not overtly dilated.

The left kidney is normal size (4.76 cm in length); normal shape and architecture with smooth peripheral margins. There is a normal 1:3 cortex to medulla ratio with mild loss of corticomedullary distinction. There is no evidence of pyelectasia, nephroliths, infarcts or hydroureter.

The right kidney is normal size (4.71 cm in length); normal shape and architecture with smooth peripheral margins. There is a normal 1:3 cortex to medulla ratio with mild loss of corticomedullary distinction. There is no evidence of pyelectasia, nephroliths, infarcts or hydroureter.

Adrenal Glands

The left adrenal gland is normal size (0.54 cm at cranial pole) (0.47 cm at caudal pole) (1.61 cm in length); normal shape; homogenous parenchyma. The glandular echogenicity and detail are unremarkable. Capsule, cortex, and medullary definition are normal. The phrenicoabdominal vein and surrounding vasculature are normal.

The right adrenal gland is upper limits of normal size (0.70 cm at cranial pole) (0.56 cm at caudal pole) (1.52 cm in length); normal shape; homogenous parenchyma. The glandular echogenicity and detail are unremarkable. Capsule, cortex, and medullary definition are normal. The phrenicoabdominal vein and surrounding vasculature are normal.

Spleen

The spleen is normal in size (0.89 cm in width at the level of the hilus) with a normal capsular contour. There is appropriate echogenicity and echotexture. No focal lesions are observed. Splenic vasculature is normal.

Liver

The liver is subjectively normal in size with normal contours and structure. There is appropriate echogenicity and echotexture. No overt structural evidence of inflammatory, infiltrative or regenerative pathology is evident. Vascular and biliary tracts are of normal volume with no evidence of congestion. No pathological hepatic lymphadenopathy observed. The gall bladder lumen is moderately distended. The wall is thin and smooth. Luminal contents are anechoic. The cystic and common bile ducts are normal/not seen.

Gastrointestinal

The gastric lumen is moderately distended with ingesta. The gastric wall is normal in thickness with a normal layering pattern. The pyloric outflow tract appears patent. The small intestinal lumen is not dilated. The small intestinal wall thickness is normal with a normal layering pattern and appropriate mural detail. Discreet masses are not identified. The colonic wall is normal. No obstructive disease is noted.

Pancreas

A portion of the pancreas is obscured by the gastric distention. In the region of the right limb, the pancreas is visible/prominent and largely isoechoic relative to surrounding omental fat and slightly mottled in appearance. No distinct focal lesions are observed. The pancreatic duct is not overtly dilated.

Free Abdomen

The peritoneal cavity is normal. There is no evidence of inflammation or effusion. The abdominal lymph nodes are normal/not visible.

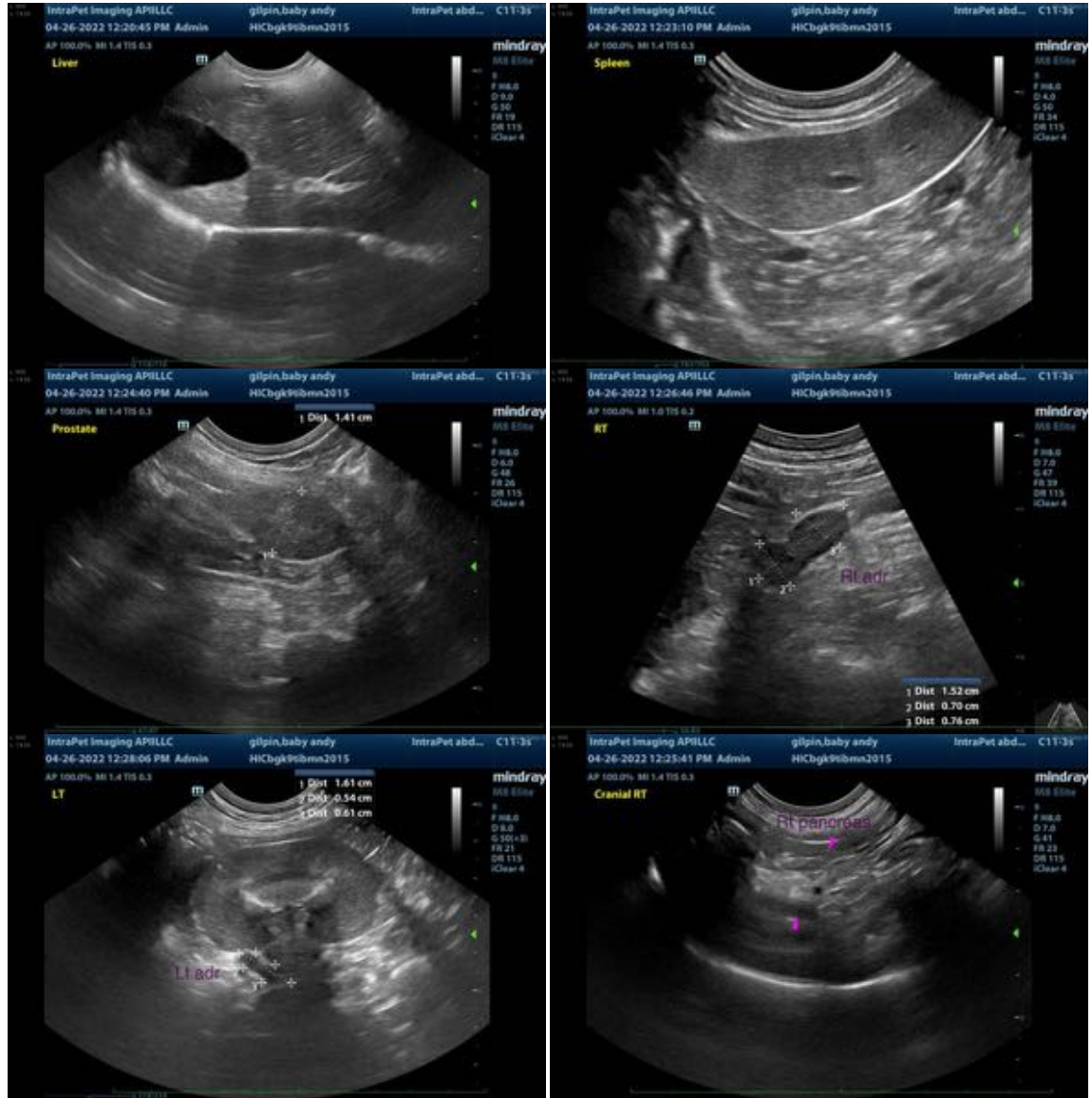
ULTRASONOGRAPHIC FINDINGS

- The pancreatic changes are most consistent with age-related parenchymal remodeling, potentially secondary to a prior inflammatory episode, early fibrosis or chronic pancreatitis.
- The prostate changes could be consistent with late-in-life neutering, normal variation or emerging neoplasia. Correlation with the patient's clinical history is recommended.
- Mild chronic renal changes.

*There is no obvious evidence of metastatic disease in the abdomen.

INTERPRETATION OF THE FINDINGS & FURTHER RECOMMENDATIONS

- Three-view thoracic radiographs are recommended to complete the metastatic check for mast cell disease.
- Given the prostate changes, consider a urine BRAF test to further screen for lower urinary tract neoplasia, particularly if the clinical suspicion for disease is high. It should be noted that a negative test does not completely rule out the possibility of cancer.



The information and recommendations provided are based on the images presented by the referring veterinarian. No evaluation can be communicated regarding pathology that was not visible in the image/video clips provided.

Thank you for this referral. If the clinical or image interpretation does not parallel your findings or if I can be of any further assistance please contact me.

Andrea Nicastro, DVM, Diplomate ACVIM (*Small Animal Internal Medicine*)
 Andrea.nicastro@sonopath.com