



PATIENT

Lucy Elder

SPECIES

Canine

BREED

Lab

SEX

Female Spayed

AGE

3/16/2020

WEIGHT

75

INTERPRETED BY

Andrea Nicastro DVM
Diplomate ACVIM
(Sm Animal Internal Med)

**IMAGING
PERFORMED BY**

Andrea Nicastro DVM
Diplomate ACVIM
(Sm Animal Internal Med)

HOSPITAL NAME

Animal Hospital of SC

REFERRING VET

Dr. Matthew Stone

INVOICE

22905

DATE

4-24-26

PRESENTING CLINICAL SIGNS

Clinical Exam Findings: Reoccur D+. Patient previously diagnosed with a gastromotility disorder which had been well managed with metoclopramide 30 minutes before meals but recently has developed intermittent vomiting and diarrhea. Lab-work unremarkable.
Abnormal lab-work values: emailed
Radiographic Findings: emailed

ULTRASONOGRAPHIC EXAMINATION OF THE ABDOMEN

Urinary System

The urinary bladder wall is normal in thickness. The mucosal surface is smooth. The bladder is moderately distended. Luminal contents are anechoic. No cystic calculi are observed. The region of the trigone and the proximal urethra, visible to a depth of 2 cm, are normal.

The left kidney is normal in size (6.05 cm in length) with a normal shape, architecture and smooth peripheral margins. There is a normal 1:3 cortex to medulla ratio with normal corticomedullary distinction. There is no evidence of pyelectasia, nephroliths, infarcts or hydroureter. Renal vasculature is normal.

The right kidney is normal in size (6.24 cm in length) with a normal shape, architecture and smooth peripheral margins. There is a normal 1:3 cortex to medulla ratio with normal corticomedullary distinction. There is no evidence of pyelectasia, nephroliths, infarcts or hydroureter. Renal vasculature is normal.

Adrenal Glands

The left adrenal gland is normal in size (0.46 cm at cranial pole) (0.54 cm at caudal pole) with a normal shape and homogenous parenchyma. The glandular echogenicity and detail are unremarkable. Capsule, cortex, and medullary definition are normal. The phrenicoabdominal vein and surrounding vasculature are normal.

The right adrenal gland is normal in size (0.78 cm at cranial pole) (0.53 cm at caudal pole) with a normal shape and homogenous parenchyma. The glandular echogenicity and detail are unremarkable. Capsule, cortex, and medullary definition are normal. The phrenicoabdominal vein and surrounding vasculature are normal.

Spleen

The spleen is normal in size (1.76 cm in width at the level of the hilus) with a normal capsular contour. There is appropriate echogenicity and echotexture. No focal lesions are observed. Splenic vasculature is normal.

Liver

The liver is subjectively normal in size with normal contours and structure. There is appropriate echogenicity and echotexture. No overt structural evidence of inflammatory, infiltrative, or regenerative pathology is evident. Vascular and biliary tracts are of normal volume with no evidence of congestion. The portal vein to caudal vena cava ratio is approximately 1: 1. The portal vein to caudal vena cava ratio is approximately 1: 1.

The gallbladder lumen is moderately distended. The wall is thin and smooth. Luminal contents are mostly anechoic. The cystic and common bile ducts are normal/not seen.

Gastrointestinal

The gastric lumen is not distended. The gastric wall and pylorus are normal in thickness with a normal layering pattern. The pyloric outflow tract is patent. The small intestinal lumen is not dilated. The small intestinal wall is normal in thickness with a normal layering pattern and appropriate mural detail. Discreet



PATIENT

Lucy Elder

masses are not identified. The ileoceccocolic junction and colonic wall are normal. There is no evidence of an obstructive pattern.

SPECIES

Canine

Pancreas

The region of the pancreas is isoechoic relative to surrounding omental fat. No obvious parenchymal abnormalities are observed. There is no evidence of regional inflammation or effusion.

BREED

Lab

Lymph Nodes

The abdominal lymph nodes are normal/not visible.

SEX

Female Spayed

Free Abdomen

The peritoneal cavity is normal. There is no evidence of inflammation or effusion.

Other

The uterine stump is visible (measuring 0.70 cm in width). No obvious pathology is observed.

AGE

3/16/2020

A brief echocardiogram reveals no evidence of pericardial effusion or obvious right atrial/auricular mass.

ULTRASONOGRAPHIC FINDINGS

WEIGHT

75

Structurally unremarkable abdomen.

*An obvious cause for the patient's clinical signs is not definitively identified in this study. Considerations include a microscopic enteropathy (i.e., food allergy/intolerance, inflammatory bowel disease, infectious/parasitic disease), underlying metabolic issue, other.

INTERPRETED BY

Andrea Nicastrò DVM
Diplomate ACVIM
(Sm Animal Internal Med)

INTERPRETATION OF THE FINDINGS & FURTHER RECOMMENDATIONS

The following diagnostics/treatment recommendations can be considered:

IMAGING PERFORMED BY

Andrea Nicastrò DVM
Diplomate ACVIM
(Sm Animal Internal Med)

1. Texas GI panel including serum cobalamin, folate, PLI, TLI and resting cortisol level
2. A fecal evaluation for ova/Giardia
3. Prophylactic deworming with fenbendazole.
4. A 3-4-week hypoallergenic or hydrolyzed protein diet trial
5. Also consider initiating a probiotic with a high colony count +/- fiber supplement (i.e., psyllium).
6. Depending on the results of the above diagnostics/therapeutics, endoscopic or surgical gastrointestinal biopsies may be warranted.
7. Three-view thoracic radiographs should be performed prior to any anesthetic event.

HOSPITAL NAME

Animal Hospital of SC

REFERRING VET

Dr. Matthew Stone

INVOICE

22905

DATE

4-24-26



PATIENT

Lucy Elder

SPECIES

Canine

BREED

Lab

SEX

Female Spayed

AGE

3/16/2020

WEIGHT

75

INTERPRETED BY

Andrea Nicastrò DVM
 Diplomate ACVIM
 (Sm Animal Internal Med)

IMAGING PERFORMED BY

Andrea Nicastrò DVM
 Diplomate ACVIM
 (Sm Animal Internal Med)

HOSPITAL NAME

Animal Hospital of SC

REFERRING VET

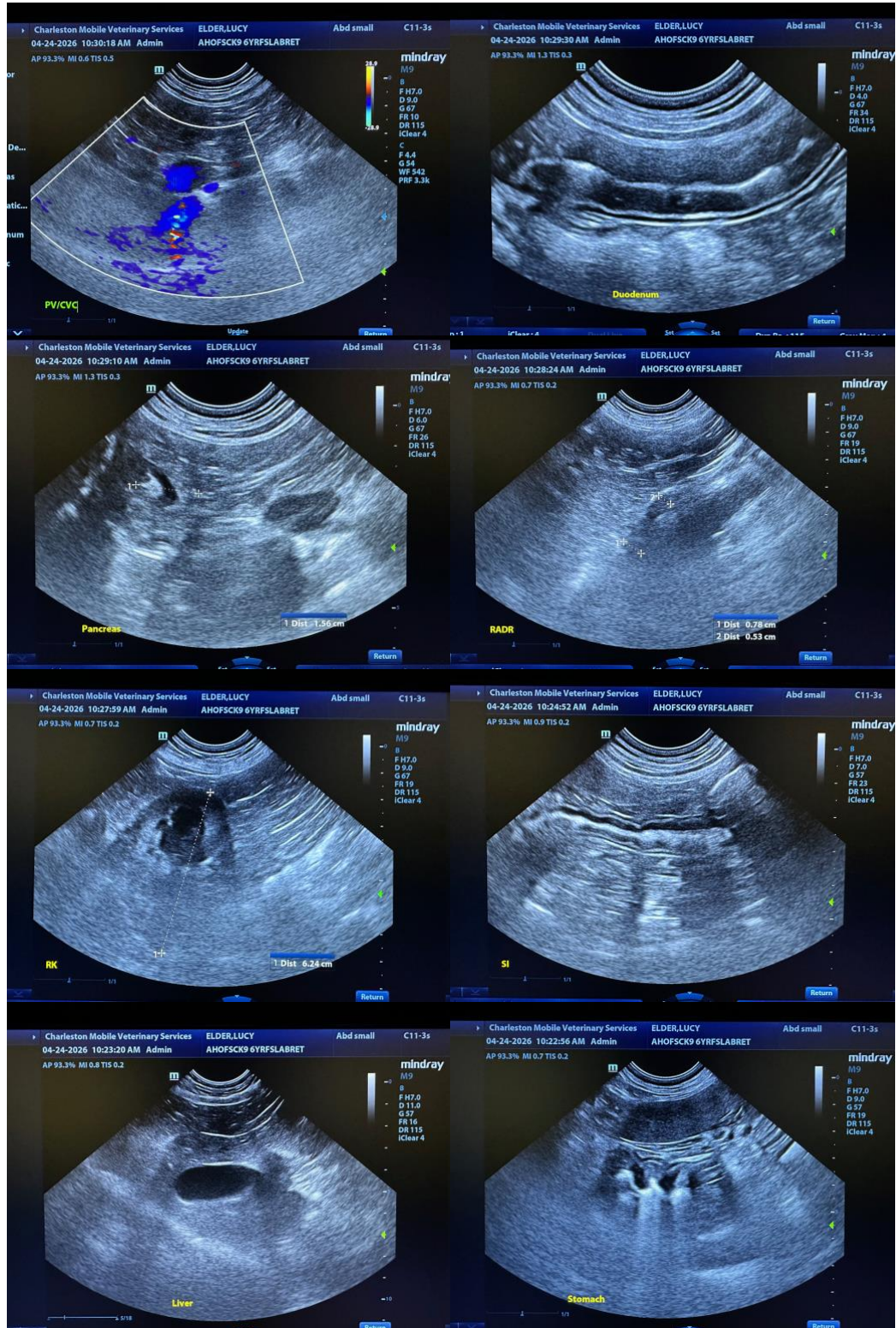
Dr. Matthew Stone

INVOICE

22905

DATE

4-24-26





PATIENT

Lucy Elder

SPECIES

Canine

BREED

Lab

SEX

Female Spayed

AGE

3/16/2020

WEIGHT

75

INTERPRETED BY

Andrea Nicastro DVM
 Diplomate ACVIM
 (Sm Animal Internal Med)

IMAGING PERFORMED BY

Andrea Nicastro DVM
 Diplomate ACVIM
 (Sm Animal Internal Med)

HOSPITAL NAME

Animal Hospital of SC

REFERRING VET

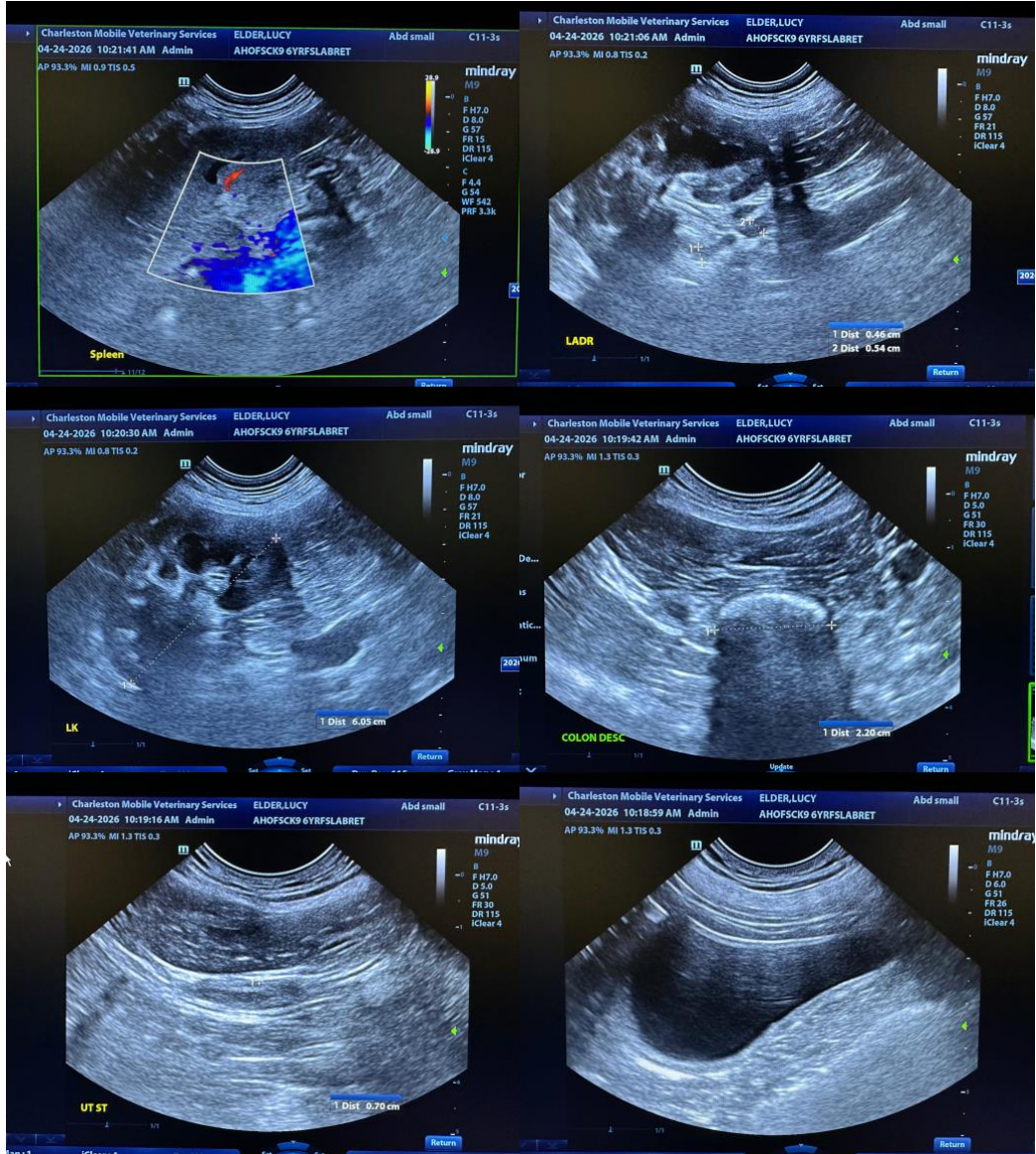
Dr. Matthew Stone

INVOICE

22905

DATE

4-24-26



The information and recommendations provided are based on the images presented by the referring veterinarian/sonographer. No evaluation can be communicated regarding pathology that was not visible in the image/video clips provided.

Thank you for this referral. If the clinical or image interpretation does not parallel your findings or if I can be of any further assistance, please contact me.

Andrea Nicastro, MPH, DVM, Diplomate DACVIM (Small Animal Internal Medicine)
info@SonoPath.com