



PATIENT PRESENTING CLINICAL SIGNS

Stanley Lenz History: Presented back in Mar 2023 straining to urinate and dark urine; sometimes blood in urine

SPECIES **This study was limited to the urinary system. There is a potential for pathology in organs that were not visualized.

Canine

ULTRASONOGRAPHIC EXAMINATION OF THE ABDOMEN

BREED *Urinary System*

Boxer

The urinary bladder is moderate distended. The wall is normal in thickness with a slightly irregular mucosal surface. Numerous cystic calculi are visualized (the largest measuring 1.87 cm in diameter). In addition, a 1.00 cm urolith is observed in the proximal urethra. A small amount of suspended echogenic debris is also observed within the bladder lumen.

SEX

ULTRASONOGRAPHIC FINDINGS

Neutered Male

Findings

AGE

- Numerus cystic calculi, along with a proximal urethral calculus. There is minor evidence of cystitis. The positive doppler flow over the cystic calculi is a twinkling artifact and does not represent true blood flow.

7 years

WEIGHT

INTERPRETATION OF THE FINDINGS & FURTHER RECOMMENDATIONS

70 lbs

- Retropulsion of the proximal urethrolith into the urinary bladder is recommended, followed by cystotomy with stone removal, analysis and culture.

INTERPRETED BY

Andrea Nicastro, DVM,
Diplomate ACVIM (*Small Animal Internal Medicine*)

IMAGING PERFORMED BY

Dr Shelley Lenz

HOSPITAL NAME

State Avenue VC

REFERRING VET

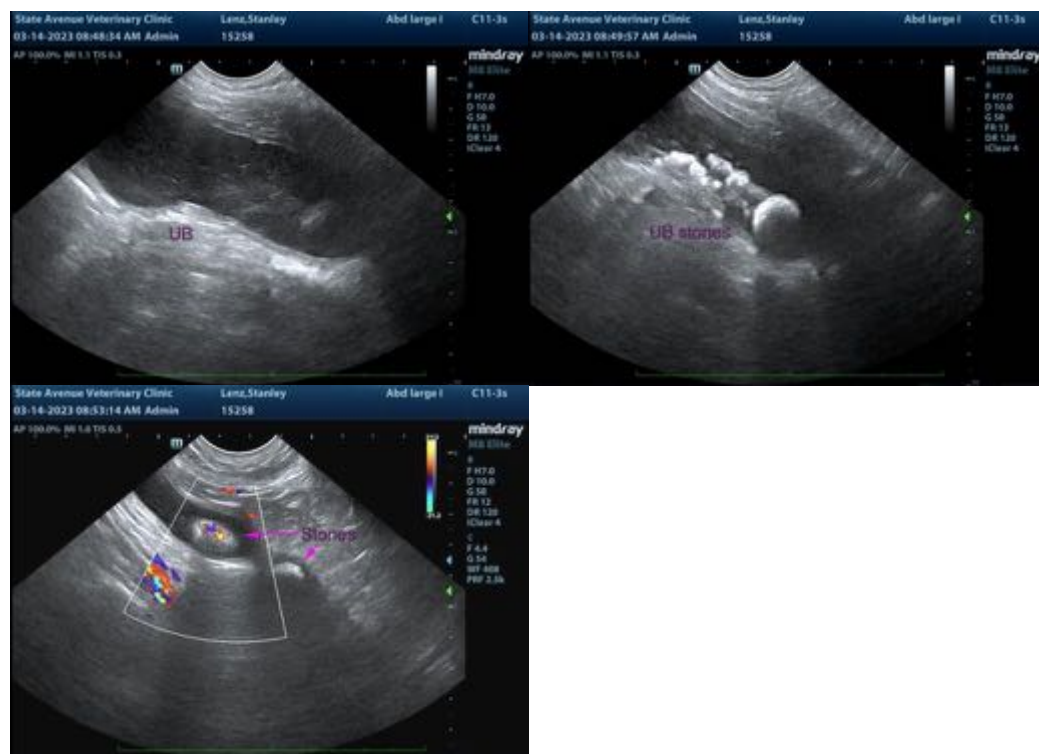
Dr Raul Casas-Dolz

INVOICE

12809

DATE

4.21.23





PATIENT

Stanley Lenz

The information and recommendations provided are based on the images presented by the referring veterinarian/sonographer. No evaluation can be communicated regarding pathology that was not visible in the image/video clips provided.

SPECIES

Canine

Thank you for this referral. If the clinical or image interpretation does not parallel your findings or if I can be of any further assistance, please contact me.

Andrea Nicastro, MPH, DVM, Diplomate DACVIM (Small Animal Internal Medicine)
info@SonoPath.com

BREED

Boxer

SEX

Neutered Male

AGE

7 years

WEIGHT

70 lbs

INTERPRETED BY

Andrea Nicastro, DVM,
Diplomate ACVIM (*Small Animal Internal Medicine*)

IMAGING PERFORMED BY

Dr Shelley Lenz

HOSPITAL NAME

State Avenue VC

REFERRING VET

Dr Raul Casas-Dolz

INVOICE

12809

DATE

4.21.23