**DATE PRESENTING CLINICAL SIGNS**

4.21.2023

Cushing's patient diagnosed in May of 2021. Has been relatively controlled with vetoryl but over the last several months has had slow weight loss and is ravenously hungry despite her stim tests being normal. Her last test 2 weeks ago was actually low and we backed off her vetoryl dose. Screening Bw overall was unremarkable. No GI signs.

PATIENT

Hula Dencler

Current Medications: trilostane 15 mg BID since 3/15/23, was previously on 20 mg BID for a while
 Lab Results: acth stim 9/9/22 pre 4.3 post 5.0. acth stim 3/10/23 pre 2.6 post 1.2

SPECIES

Canine

3/10/23 Senior panel - alkp 821, na 131 cl 100, creat 0.4, glob 2.0 rest wnl
 Date of Previous IntraPet Ultrasound: No previous.

BREED

Dachshund

Sedation: Not required to complete full diagnostic ultrasound.
 Stat Report: Not requested.
 Imaging Performed By: Rachel Brillhart, RDMS.

ULTRASONOGRAPHIC EXAMINATION OF THE ABDOMEN**SEX**

Female Spayed

Urinary System

The urinary bladder wall is normal in thickness and the mucosal surface is smooth. The bladder is moderately distended. Luminal contents are anechoic. No cystic calculi are observed. The region of the trigone and the proximal urethra, visible to a depth of 1-2 cm, are normal.

AGE

6/15/2010

The left kidney is normal in size (5.08 cm in length) with a normal shape, architecture and smooth peripheral margins. There is a normal 1:3 cortex to medulla ratio with normal corticomedullary distinction. Mild peyl is present (0.35 cm in the longitudinal plane). There is no evidence of nephroliths, infarcts or hydroureter. Renal vasculature is normal.

WEIGHT

14.1lbs

The right kidney is normal in size (5.02 cm in length) with a normal shape, architecture and smooth peripheral margins. There is a normal 1:3 cortex to medulla ratio with normal corticomedullary distinction. There is no evidence of pyelectasia, nephroliths, infarcts or hydroureter. Renal vasculature is normal.

INTERPRETED BY

Andrea Nicastrò,
 DVM, Diplomate
 ACVIM (Small Animal
 Internal Medicine)

Adrenal Glands

The left adrenal gland is mildly enlarged (0.90 cm at cranial pole) (0.84 cm at caudal pole) (2.44 cm in length) with a slightly irregular shape. The parenchyma is hypoechoic with loss of glandular detail. The phrenicoabdominal vein and surrounding vasculature are normal.

HOSPITAL NAME

Greenbrier VC

The right adrenal gland is mildly enlarged (0.78 cm at cranial pole) (1.03 cm at caudal pole) (2.50 cm in length) with with a slightly irregular shape. The parenchyma is hypoechoic with loss of glandular detail. The phrenicoabdominal vein and surrounding vasculature are normal

REFERRING VET

Dr. Boccanfuso

Spleen

The spleen is normal in size (1.36 cm in width at the level of the hilus) with a normal capsular contour. The parenchyma is slightly mottled in appearance. A 0.78 cm hypoechoic nodule is observed just caudal to the hilus. Splenic vasculature is normal.

INVOICE

12838

Liver

The liver is subjectively prominent in size with normal curvilinear peripheral contours. The parenchyma is isoechoic relative to the spleen and exhibits mild heterogeneity. No distinct focal lesions are observed. Hepatic vasculature and biliary tracts are of normal volume with no evidence of congestion.

The gall bladder lumen is moderately distended. The wall is thin and smooth. A scant amount of echogenic debris is observed within the lumen. The cystic and common bile ducts are normal/not seen.

Gastrointestinal

The gastric lumen is not distended. The gastric wall and pylorus are normal in thickness with a normal layering pattern. The pyloric outflow tract is patent. The small intestinal lumen is not dilated. The small intestinal wall is normal in thickness with a normal layering pattern and appropriate mural detail. The wall of the ileocecolic junction is prominent (up to 0.71 cm). Shadowing material is observed within the lumen of the ileocecolic junction. The remaining colonic wall is normal. There is no obvious evidence of an obstructive pattern.

Pancreas

The right limb of the pancreas is visible with normal curvilinear peripheral contours. The parenchyma is largely isoechoic relative to surrounding omental fat and slightly mottled in appearance. The pancreatic duct is visible but not overtly dilated. There is no evidence of peripancreatic inflammation or effusion.

Free Abdomen

The peritoneal cavity is normal. There is no evidence of inflammation or effusion. The abdominal lymph nodes are normal/not visible.

Other

A uterine stump is visible (0.55 cm in width). No obvious pathology is observed.

ULTRASONOGRAPHIC FINDINGS

Primary Findings

- The thickening of the ileocecolic junction wall may be a normal variant for this patient or may be secondary to inflammation or emerging neoplasia.

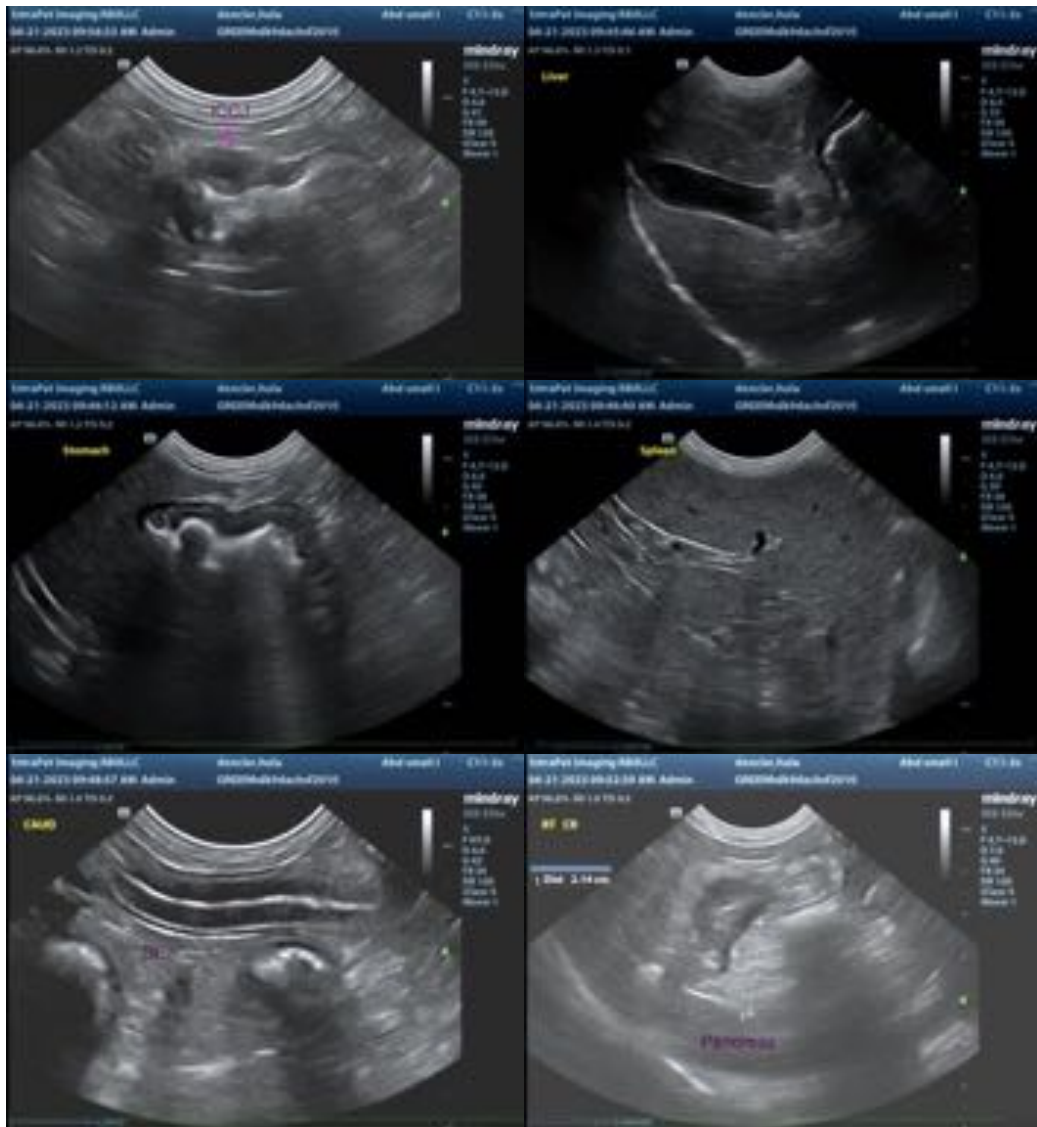Secondary Findings

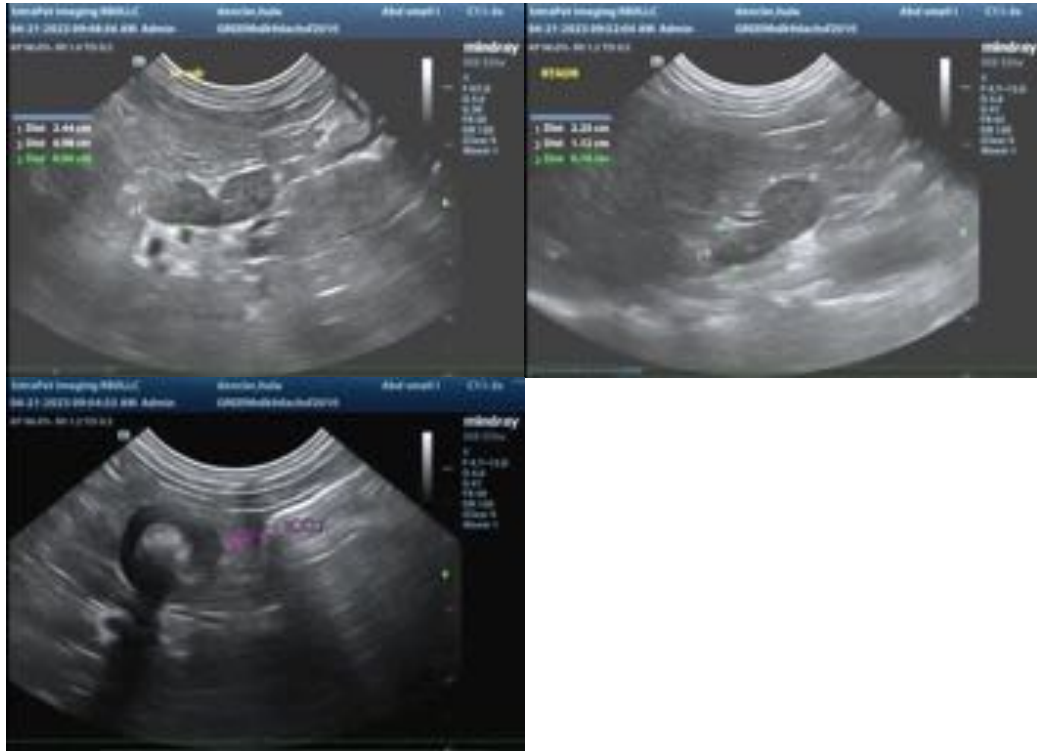
- The bilateral adrenomegaly is consistent with the previous diagnosis of pituitary-dependent hyperadrenocorticism.
- The splenic parenchymal changes are most consistent with a benign process such as lymphoid hyperplasia, extramedullary hematopoiesis, splenitis or antigenic stimulation with a low possibility of infiltrative neoplasia (i.e., lymphoma, mast cell neoplasia).
- The diffuse hepatic changes are non-specific and could be consistent with vacuolar hepatopathy, regenerative nodular hyperplasia, and/or age-related remodeling. Inflammatory and infiltrative disease are considered less likely.
- The pancreatic changes are most consistent with age-related parenchymal remodeling, potentially secondary to a prior inflammatory episode, early fibrosis or chronic pancreatitis.
- Visible uterine stump – incidental
- The left pyelectasia may be secondary to age-related remodeling and/or pyelonephritis. Correlation with the patient's clinical history and urinalysis findings is recommended.

INTERPRETATION OF THE FINDINGS & FURTHER RECOMMENDATIONS

- Regarding the changes of the ileocecolic junction, consider a repeat ultrasound in 3-4 weeks to assess for progression.

- Regarding the weight loss, consider the following:
 1. Three-view thoracic radiographs to assess for occult disease in the chest
 2. Orthopedic and neurologic examination to assess for nonmetabolic causes of weight loss
 3. Fecal evaluation for ova and Giardia
 4. Malabsorption panel, including serum cobalamin and folate, TLI and PLI
- Regarding the pyelectasia, a urinalysis +/- urine culture and sensitivity is recommended.





The information and recommendations provided are based on the images presented by the referring veterinarian/sonographer. No evaluation can be communicated regarding pathology that was not visible in the image/video clips provided.

Thank you for this referral. If the clinical or image interpretation does not parallel your findings or if I can be of any further assistance, please contact me.

Andrea Nicastro, MPH, DVM, Diplomate DACVIM (Small Animal Internal Medicine)
info@SonoPath.com