

**DATE PRESENTING CLINICAL SIGNS**

4.21.23

Acute anorexia; Vomiting and diarrhea the weekend of the 8th that resolved. She had gotten into the bathroom trash prior. She had an ALP of 614 on the 10th. She was referred to the ER because she was shaking and hiding in the bathroom and was treated symptomatically with metronidazole 500mg BID, omeprazole 20mg daily, Gabapentin 300mg BID, and Buprenorphine. . She has been off medications and was doing ok. Not eating is extremely abnormal for her. She has been previously treated with Ursodiol but is not currently on the medication since her GI upset. She had a nonspecific mild hepatopathy with a small nodule on ultrasound in September plus gall bladder sludge. She has also lost weight.

PATIENT

Elinor Moreland

SPECIES

Canine

BREED

Hound Mix

Current Medications: Omeprazole 20mg; cerenia injection given yesterday 4/20/23.

Lab Results: ALP ~650 4/10/23

Date of Previous IntraPet Ultrasound: No previous.

Sedation: Not required to complete full diagnostic ultrasound.

Stat Report: Not requested.

Imaging Performed By: Rachel Brillhart, RDMS.

SEX

Spayed Female

ULTRASONOGRAPHIC EXAMINATION OF THE ABDOMEN**Urinary System**

The urinary bladder wall is normal in thickness and the mucosal surface is smooth. The bladder is moderately distended. Luminal contents are anechoic. No cystic calculi are observed. The region of the trigone and visible portion of the proximal urethra are normal.

AGE

10/25/2012

The left kidney is normal in size (6.18 cm in length) with a normal shape, architecture and smooth peripheral margins. There is a normal 1:3 cortex to medulla ratio with minimal to mild loss of corticomedullary distinction. There is no evidence of pyelectasia, nephroliths, infarcts or hydroureter. Renal vasculature is normal.

WEIGHT

1b57.5 lbs

The right kidney is normal in size (6.42 cm in length) with a normal shape, architecture and smooth peripheral margins. There is a normal 1:3 cortex to medulla ratio with mild loss of corticomedullary distinction. There is no evidence of pyelectasia, nephroliths, infarcts or hydroureter. Renal vasculature is normal.

INTERPRETED BY

Andrea Nicastro,
DMV, Diplomate
DACVIM (Small
Animal
Internal Medicine)

Adrenal Glands

The left adrenal gland is borderline enlarged (0.75cm at cranial pole) (0.75 cm at caudal pole) (2.61 cm in length) with a normal shape and homogenous parenchyma. The glandular echogenicity and detail are unremarkable. Capsule, cortex, and medullary definition are normal. The phrenicoabdominal vein and surrounding vasculature are normal.

HOSPITAL NAME

Greenbrier VC

The right adrenal gland is mildly enlarged (1.12 cm at cranial pole) (0.89 cm at caudal pole) (2.73 cm in length) with a normal shape and smooth peripheral contours. A pinpoint hyperechoic focus is observed at the caudal pole. The glandular remaining echogenicity and detail are normal. The phrenicoabdominal vein and surrounding vasculature are normal.

REFERRING VET

Dr. Davies

Spleen

The spleen is normal in size (1.38 cm in width at the level of the hilus) with a normal capsular contour. The parenchyma is subtly mottled in appearance. No focal lesions are observed. Splenic vasculature is normal.

INVOICE

12836

Liver

The liver is subjectively normal in size with normal curvilinear peripheral contours. The parenchyma is isoechoic relative to the spleen and subtly mottled in appearance. A 1.36 cm ill-defined hypoechoic nodule

is observed on the right side. Hepatic vasculature and intrahepatic biliary tracts are of normal volume with no evidence of congestion.

The gall bladder lumen is moderately distended. The wall is thin and smooth. A small amount of aggregated, echogenic, suspended echogenic debris/sludge is observed within the lumen, along with a small amount of gravity-dependent mineralized sand. The cystic and common bile ducts are normal/not seen.

Gastrointestinal

The gastric lumen is moderately fluid-distended. The gastric wall and pylorus are normal in thickness with a normal layering pattern. The pyloric outflow tract is patent. The small intestinal lumen is diffusely fluid-distended (mild). The small intestinal wall is normal to borderline thickened (up to 0.43 cm) with retention of the normal layering pattern. Discreet masses are not identified. The colonic ileocecolic junction and colonic wall are normal. The colonic lumen is mildly fluid-distended. There is no obvious evidence of an obstructive pattern.

Pancreas

The right limb of the pancreas is prominent in size with normal curvilinear peripheral contours. The parenchyma is largely hyperechoic relative to surrounding omental fat and slightly mottled in appearance. The pancreatic duct is visible but not overtly dilated. There is no evidence of peripancreatic inflammation or effusion.

Free Abdomen

Trace free fluid is observed. A few prominent lymph nodes are observed in the mid- to caudal abdomen (the largest measuring 2.25 cm in length). Surrounding mesentery is mildly hyperechoic.

ULTRASONOGRAPHIC FINDINGS

Primary Findings

- Suspected diffuse gastrointestinal ileus, with a lower possibility of an obstruction (i.e., partial). The small intestinal wall changes are suggestive of an inflammatory process with a lower possibility of emerging neoplasia. The cause of the GI signs is unclear but may be secondary to dietary indiscretion, inflammatory bowel disease, food allergy/intolerance, infectious/parasitic disease, underlying metabolic issue, other).
- Trace ascites

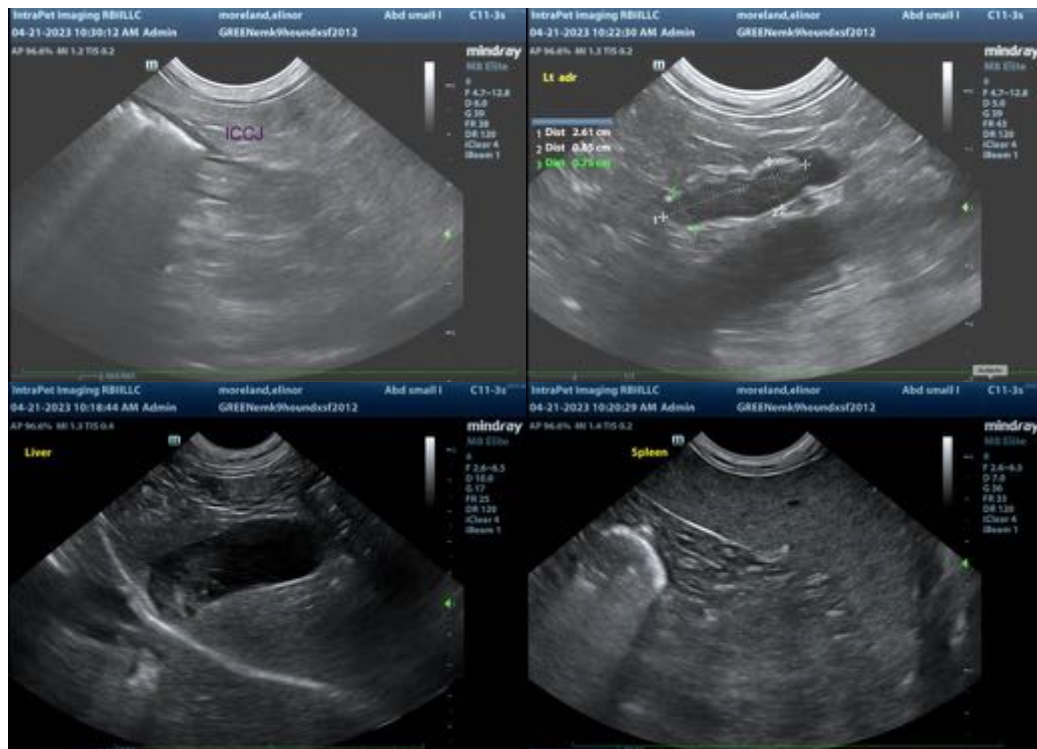
Secondary Findings

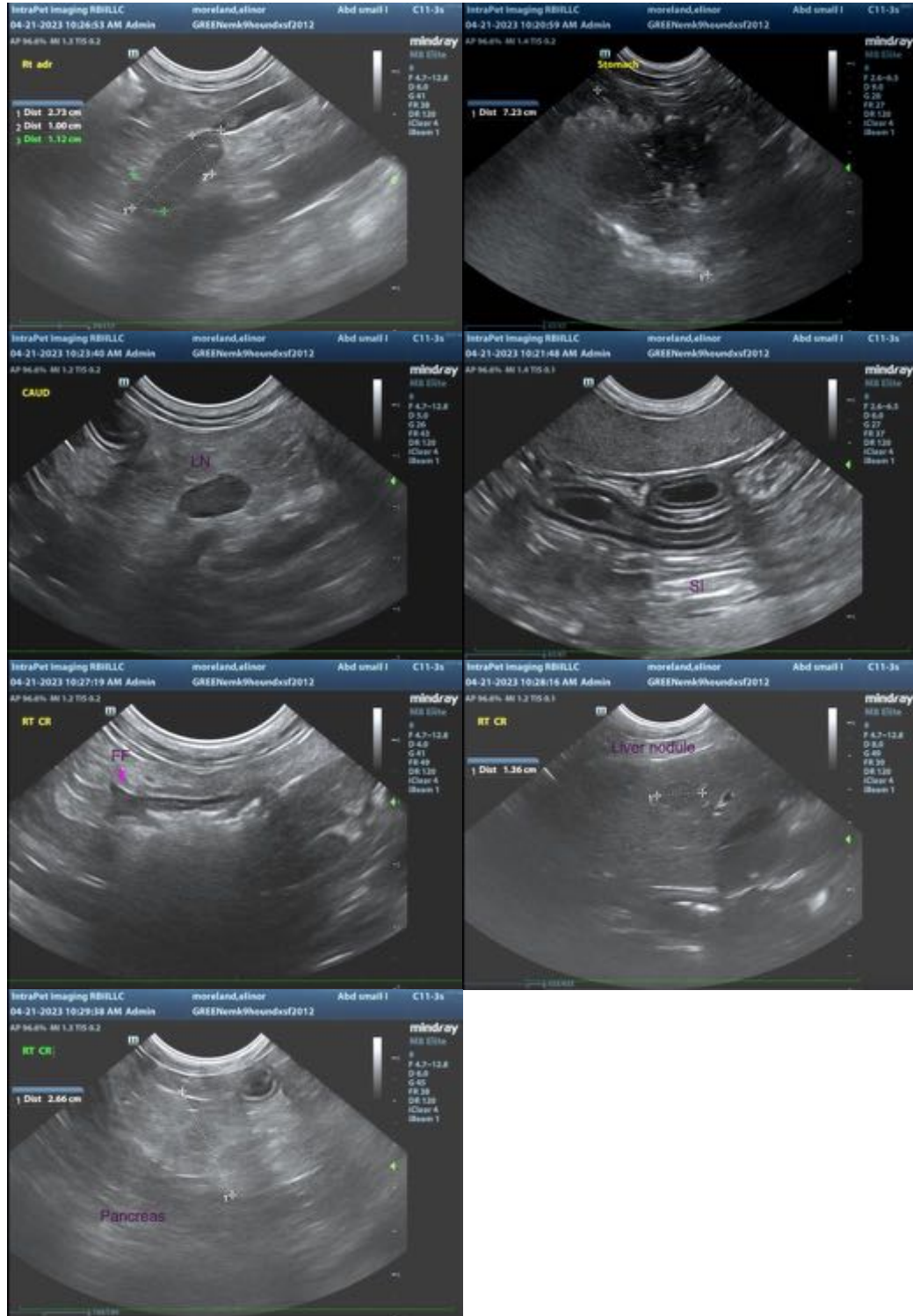
- The hepatic parenchymal changes, including the nodule, trend toward the benign (i.e., regenerative nodular hyperplasia, age-related remodeling, and/or vacuolar hepatopathy) with a lower possibility of a neoplastic process, inflammatory disease, or other hepatopathy.
- Gall bladder debris/sludge, non-mucocele
- Mild bilateral adrenomegaly. The hyperechoic focus at the caudal pole of the right adrenal gland may represent a benign area of mineralization, or less likely, an emerging neoplastic process.
- Mild bilateral renal changes
- The splenic parenchymal changes are most consistent with a benign process such as lymphoid hyperplasia, extramedullary hematopoiesis, splenitis or antigenic stimulation with a low possibility of infiltrative neoplasia (i.e., lymphoma, mast cell neoplasia).

- The pancreatic changes are most consistent with age-related parenchymal remodeling, potentially secondary to a prior inflammatory episode, early fibrosis or chronic pancreatitis.
- The lymphadenopathy could be consistent with reactive lymphadenopathy, lymphoid hyperplasia, emerging neoplasia. A benign process is favored.

INTERPRETATION OF THE FINDINGS & FURTHER RECOMMENDATIONS

- Given the GI changes, consider the following:
 1. Fecal evaluation for ova and Giardia
 2. Fecal PCR infectious disease panel
 3. Prophylactic deworming with Fenbendazole
 4. A malabsorption panel, including serum cobalamin and folate, TLI and PLI is also recommended.
 5. Initiation of a probiotic with a high colony count (i.e., Provable Forte or Visbiome) +/- a fiber supplement (if diarrhea is still present).
 6. Three-view thoracic radiographs are recommended to assess cardiopulmonary status, particularly in light of the patient's weight loss.
 7. Ultimately endoscopic or surgical gastrointestinal biopsies may be necessary to get a definitive diagnosis.
- Consider testing for hyperadrenocorticism with a low-dose dexamethasone suppression test or ACTH stimulation test if clinical signs (i.e., PU/PD) develop in the future.





The information and recommendations provided are based on the images presented by the referring veterinarian/sonographer. No evaluation can be communicated regarding pathology that was not visible in the image/video clips provided.

Thank you for this referral. If the clinical or image interpretation does not parallel your findings or if I can be of any further assistance, please contact me.

Andrea Nicastro, MPH, DVM, Diplomate DACVIM (Small Animal Internal Medicine)
info@SonoPath.com