



PATIENT

Kugel Berman

SPECIES

Canine

BREED

Mixed

SEX

Spayed Female

AGE

13 years

WEIGHT

55 lbs

INTERPRETED BY

Andrea Nicastro, DVM,
Diplomate ACVIM
(Small Animal Internal
Medicine)

IMAGING PERFORMED BY

Dr. Scott

HOSPITAL NAME

Ho Ho Kus
VACUOLAR
HEPATOPATHY

REFERRING VET

Dr. Eisenberg

INVOICE

10775

DATE

4/21/22

PRESENTING CLINICAL SIGNS

History: 1-2 week hx of GI signs. Started with vomiting/diarrhea, vomited stopped by app worsening and hemorrhagic diarrhea

Abnormal PE/Chem/CBC/UA Results: PE WNL CBC/CHem WNL, spec elevated 515, rads unremarkable

ULTRASONOGRAPHIC EXAMINATION OF THE ABDOMEN

Urinary System

The urinary bladder is mildly distended with mostly anechoic urine. The wall in the region of the apex and the dorsal aspect is thickened (up to 0.96 cm) and irregular, with protruding areas. No cystic calculi are observed. The region of the trigone and the visible portion of the proximal urethra are normal.

The left kidney presented normal size (6.59 cm in length); normal shape and architecture with smooth peripheral margins. There is a normal 1:3 cortex to medulla ratio with minimal to mild loss of corticomedullary distinction. At least 2 small cortical cysts are visualized. There is no evidence of pyelectasia, nephroliths, infarcts or hydroureter.

The right kidney presented normal size (6.38 cm in length); normal shape and architecture with smooth peripheral margins. There is a normal 1:3 cortex to medulla ratio with minimal to mild loss of corticomedullary distinction. There is no evidence of pyelectasia, nephroliths, infarcts or hydroureter.

Adrenal Glands

The left adrenal gland is enlarged (0.81 cm at cranial pole) (1.27 cm at caudal pole) (2.28 cm in length); with an irregular shape. A 1.30 x 1.14 cm hyperechoic nodule is observed at the caudal pole. Glandular echogenicity and detail at the cranial pole appear normal. The phrenicoabdominal vein and surrounding vasculature appear normal.

The right adrenal gland is normal size (1.78 cm at cranial pole) (0.69 cm at caudal pole) (2.97 cm in length); normal shape; homogenous parenchyma. The glandular echogenicity and detail are unremarkable. Capsule, cortex, and medullary definition are normal. The phrenicoabdominal vein and surrounding vasculature are normal.

Spleen

The spleen is normal in size (1.79 cm in width at the level of the hilus) with a normal capsular contour. There is appropriate echogenicity and echotexture. No focal lesions are observed. Splenic vasculature is normal.

Liver

The liver is normal to prominent in size with slightly irregular peripheral contours. The parenchyma is hypoechoic relative to the spleen and diffusely mottled in appearance. A 3.26 x 2.55 cm hypoechoic swelling/mass appears to be arising from the left side. The lesion causes capsular expansion. Hepatic vasculature and intrahepatic biliary tracts are of normal volume with no evidence of congestion.

The gall bladder lumen is moderately distended. The wall is thin and smooth. A small to moderate amount of aggregated, echogenic, partially dependent debris/sludge is observed within the lumen. The cystic and common bile ducts are normal.

Gastrointestinal

The gastric lumen is mildly fluid-distended. The gastric wall is borderline thickened (up to 0.48 cm) in the region of the fundus. There is retention of the normal layering pattern. The pyloric outflow tract is patent. A >3.50 cm segment of small intestine is severely thickened (up to 0.67 cm), irregular, hypoechoic, slightly

plicated, with a suspected loss of the normal layering pattern. The lumen in this segment is mildly dilated with chyme and gas. The mesentery effacing the serosal surface in this region is hyperechoic. In the remaining small intestinal segments, the lumen is not dilated, and the wall is normal in thickness with a normal layering pattern. The colonic wall is normal.

Pancreas

The region of the pancreas is isoechoic relative to surrounding omental fat. No obvious parenchymal abnormalities are observed. There is no evidence of regional inflammation or effusion.

Free Abdomen

There is no obvious evidence of free fluid. The abdominal lymph nodes are normal/not visible.

ULTRASONOGRAPHIC FINDINGS

Primary Findings

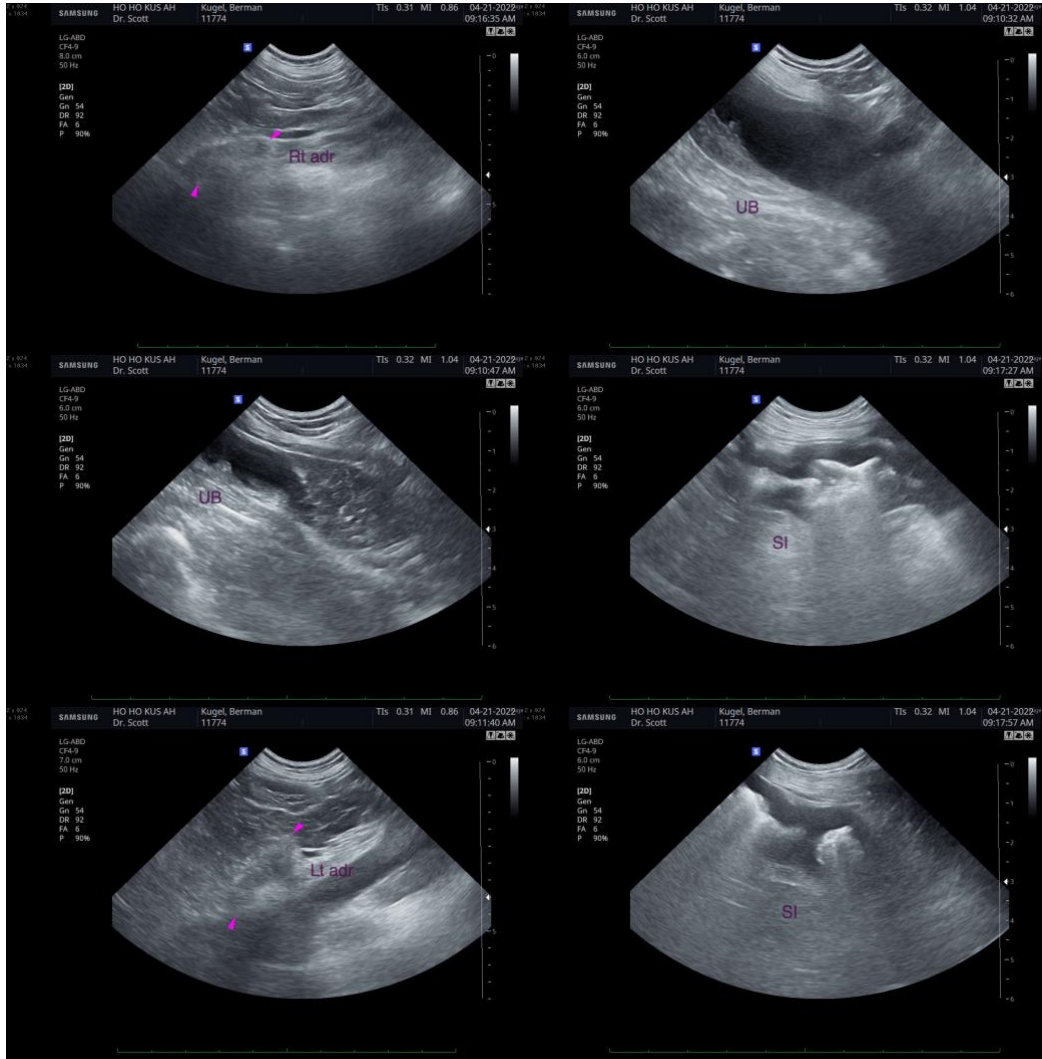
- The thickened segment of small intestine is concerning for infiltrative neoplasia (i.e., adenocarcinoma, lymphoma). However, a severe inflammatory process (i.e., pyogranulomatous) cannot be excluded. A foreign body in this region is possible but considered less likely given the lack of luminal dilation proximal to the thickened region. Regional peritonitis is present.

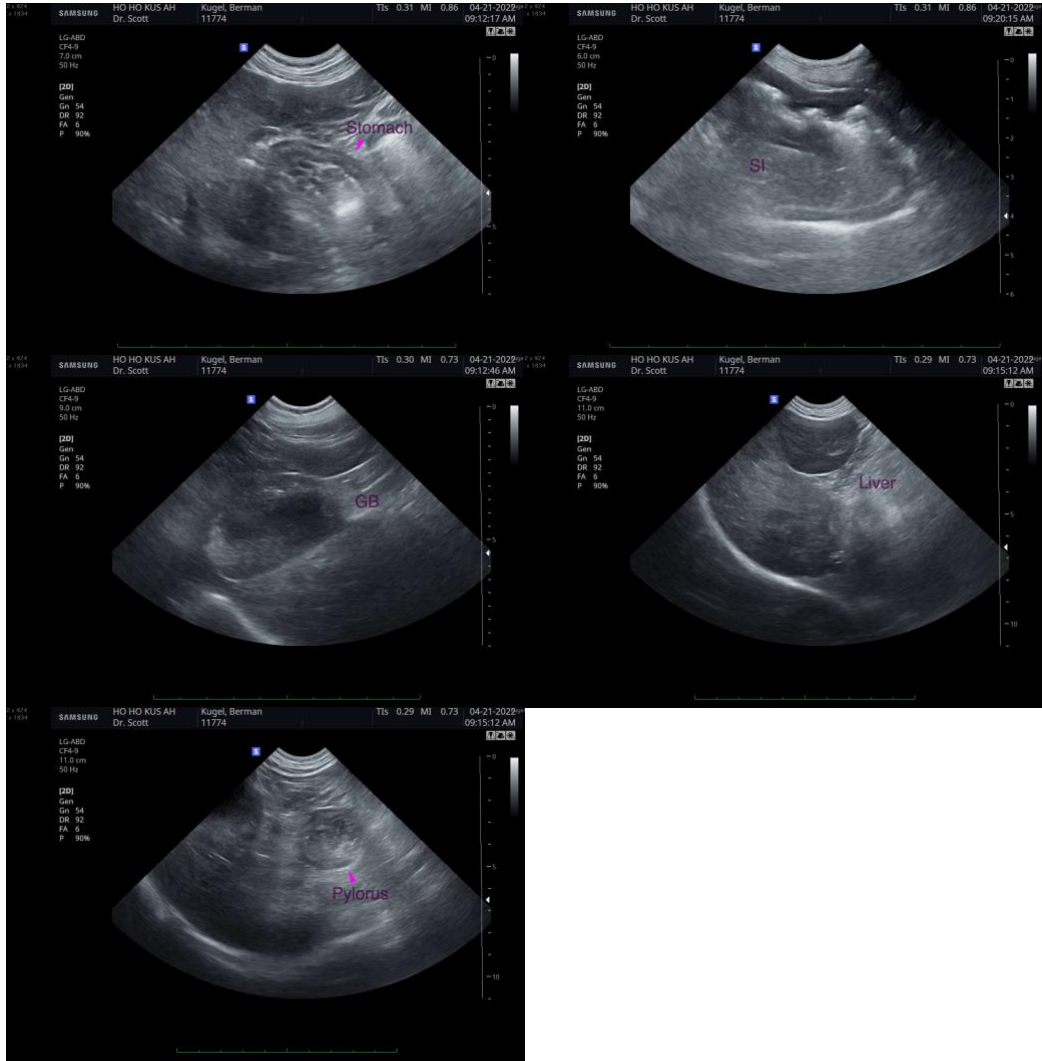
Secondary Findings

- Hepatic mass, suspected to be on the left side. Differentials include adenoma, adenocarcinoma, regenerative nodular hyperplasia, focal inflammatory process, other. A neoplastic process is slightly favored.
- Chronic age-related renal changes.
- The left adrenal nodule could be consistent with nodular hyperplasia. Alternatively, an emerging tumor (i.e., adenoma, adenocarcinoma, pheochromocytoma) is possible.
- The thickened urinary bladder wall could be consistent with polypoid cystitis, or less likely, infiltrative neoplasia (i.e., transitional cell carcinoma). If the patient has a history of urinary tract infections, polypoid cystitis is more likely.

INTERPRETATION OF THE FINDINGS & FURTHER RECOMMENDATIONS

- Three-view thoracic radiographs are recommended to assess for pulmonary metastases.
- Consider fine-needle aspirates of the thickened bowel segments and hepatic mass (if clotting status is appropriate). Twenty-five gauge-needles should be used. If cytology results are inconclusive, an abdominal exploratory with biopsies of these areas, as well as of the urinary bladder can be considered.
- A malabsorption panel, including serum cobalamin and folate, TLI and PLI, is also recommended





The information and recommendations provided are based on the images presented by the referring veterinarian/sonographer. No evaluation can be communicated regarding pathology that was not visible in the image/video clips provided.

Thank you for this referral. If the clinical or image interpretation does not parallel your findings or if I can be of any further assistance, please contact me.

Andrea Nicastro, DVM, Diplomate DACVIM (Small Animal Internal Medicine)
info@SonoPath.com