


PATIENT PRESENTING CLINICAL SIGNS

Bam Bam Deveaux
SPECIES
 Canine

History: Bam Bam was diagnosed with Cushing's in January. An ultrasound was performed around this time with SonoPath which also showed an emerging mucocele. Has been on 15 mg of Vetoryl since then. We have done a 1 week post starting vetoryl ACTH stim which was normal...this is now a 2-3 month missed the 1 month acth recheck and we decided to recheck the gallbladder today as well. Has also been getting 130 mg of Ursodiol SID for the past few months.

BREED ULTRASONOGRAPHIC EXAMINATION OF THE ABDOMEN
Shih Tzu Urinary System

The bladder is moderately distended. A small amount of suspended echogenic debris is observed within the lumen. No masses, inflammatory changes or calculi are observed. Ureteral papillae and visualized portion of the proximal urethra, visible to a depth of 2 cm, are normal.

SEX

Neutered Male
 The prostate is normal in size (0.51 cm in width) and shape. Parenchyma is homogenous. The prostatic urethra appears normal without evidence of dilation or obstruction.

AGE

12 years
 The left kidney is normal in size with a normal shape and smooth peripheral contours. The cortex is diffusely thickened and hyperechoic to slightly heterogenous with pinpoint hyperechoic to mineralized foci. There is moderate loss of corticomedullary distinction. Hyperechoic shadowing diverticular foci are seen. There is trace pyelectasia (0.17 cm in the transverse plane). There is no evidence of infarcts or hydroureter. Renal vasculature is normal.

WEIGHT

19.8 lbs
 The right kidney is normal in size with a normal shape and smooth peripheral contours. The cortex is diffusely thickened and hyperechoic to slightly heterogenous with pinpoint hyperechoic to mineralized foci. There is moderate loss of corticomedullary distinction. Hyperechoic shadowing diverticular foci are seen. There is trace pyelectasia (0.13 cm in the transverse plane). There is no evidence of infarcts or hydroureter. Renal vasculature is normal.

INTERPRETED BY

Andrea Nicastro,
 DVM, Diplomate
 ACVIM (*Small Animal
 Internal Medicine*)

IMAGING PERFORMED BY

Charlie Rodriguez

HOSPITAL NAME

Bethany Family PC

REFERRING VET

Dr. Charlie Rodriguez

Adrenal Glands

The left adrenal gland is enlarged (0.62 cm at cranial pole) (0.74 cm at caudal pole) (2.64 cm in length). A 1.48 x 1.03 cm hyperechoic nodule is observed in the cranial to mid-aspect. The lesion causes capsular expansion. Glandular echogenicity and detail at the cranial pole appear relatively normal. The parenchyma at the caudal pole is mildly heterogenous with some loss of glandular detail. The phrenicoabdominal vein and surrounding vasculature appear normal.

The right adrenal gland is enlarged (1.22 cm at cranial pole) (0.72 cm at caudal pole); with an irregular shape. A 1.78 x 1.02 cm hyperechoic nodule is observed at the cranial to mid-aspect. The parenchyma at the caudal aspect is slightly heterogenous, with some loss of glandular detail. The phrenicoabdominal vein and surrounding vasculature appear normal.

Spleen

The spleen is normal in size (1.17 cm in width at the level of the hilus) with a normal capsular contour. There is appropriate echogenicity and echotexture. No focal lesions are observed. Splenic vasculature is normal.

INVOICE

10792

DATE

4/21/22

Liver

The liver is subjectively enlarged with slightly swollen peripheral contours. The parenchyma is isoechoic relative to the spleen and diffusely homogeneous in appearance and coarse echotexture. No distinct focal lesions are observed. Vascular and biliary tracts are of normal volume with no evidence of congestion.

The gall bladder lumen is moderately distended. The wall is thin and smooth. A moderate amount of aggregated, echogenic, partially dependent debris/sludge is observed within the lumen.

Gastrointestinal

The gastric lumen is moderately distended with ingesta. The gastric wall is normal in thickness with a normal layering pattern. The small intestinal lumen is not dilated. The small intestinal wall thickness is normal with a normal layering pattern and appropriate mural detail. Discreet masses are not identified. The colonic wall is normal. No obstructive or overt infiltrative disease is noted.

Pancreas

The region of the pancreas is isoechoic relative to surrounding omental fat. No obvious parenchymal abnormalities are observed. There is no evidence of regional inflammation or effusion.

Free Abdomen

The peritoneal cavity is normal. There is no evidence of inflammation or effusion. The abdominal lymph nodes are normal/not visible.

ULTRASONOGRAPHIC FINDINGS

Primary Findings

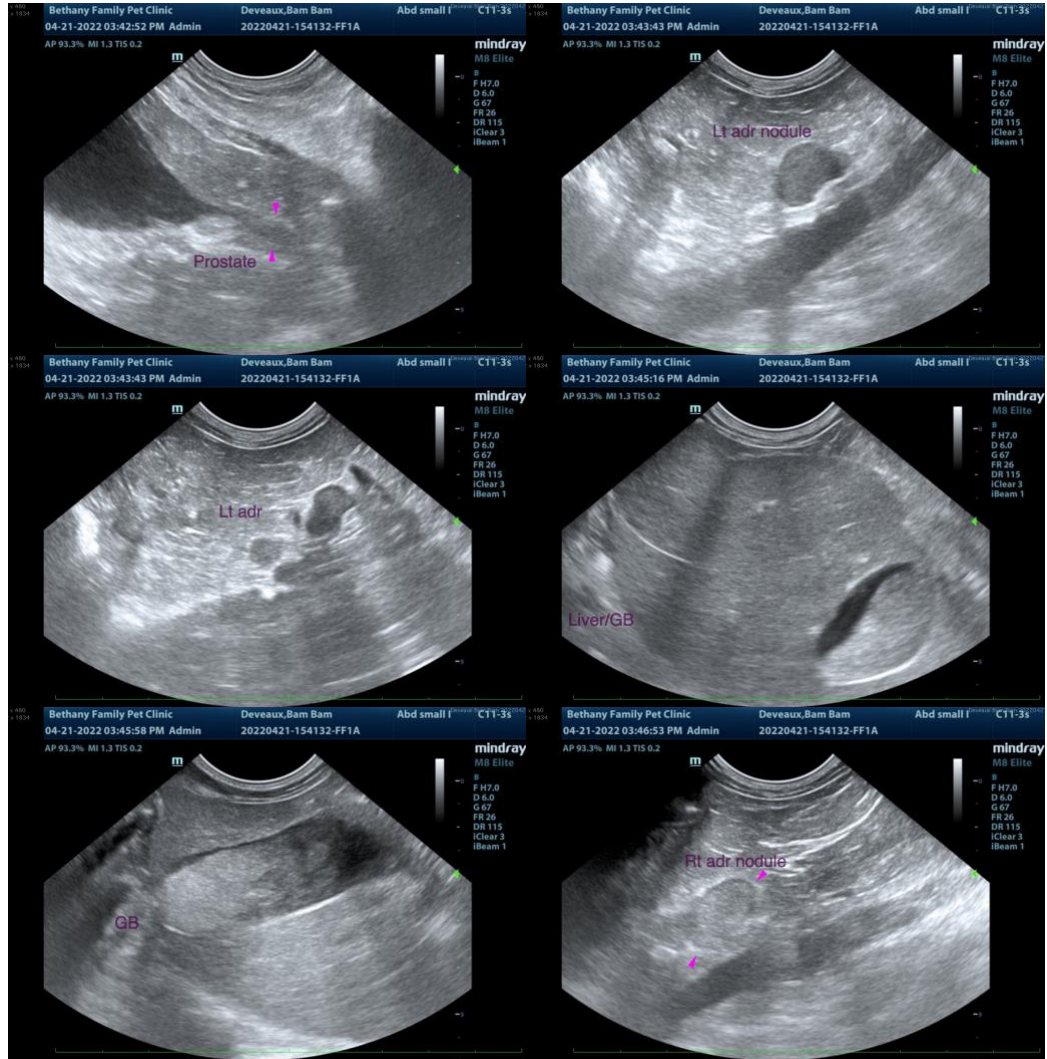
- Gall bladder sludge. Differentials include cholestasis, early mucocele formation, secondary to fasting. The gall bladder appears slightly improved compared to the previous sonogram.
- Bilateral adrenomegaly with nodules bilaterally. The nodules are similar to slightly larger compared to the previous sonogram.
- Suspected benign diffuse hepatopathy. Top differentials include vacuolar hepatopathy and/or regenerative nodular hyperplasia.

Secondary Findings

- Bilateral chronic nephropathy with dystrophic mineralization

INTERPRETATION OF THE FINDINGS & FURTHER RECOMMENDATIONS

Continued ursodiol therapy is recommended with serial sonographic monitoring (i.e, every 2-3 months) of the gall bladder to assess for progression to a fully-formed mucocele. Continued treatment for pituitary-dependent Cushing's Disease with serial monitoring of cortisol levels is recommended.



The information and recommendations provided are based on the images presented by the referring veterinarian/sonographer. No evaluation can be communicated regarding pathology that was not visible in the image/video clips provided.

Thank you for this referral. If the clinical or image interpretation does not parallel your findings or if I can be of any further assistance, please contact me.

Andrea Nicastro, DVM, Diplomate DACVIM (Small Animal Internal Medicine)
info@SonoPath.com