



**PATIENT**

Yoshi Hoffman

**SPECIES**

Canine

**BREED**

Yorkshire Terrier

**SEX**

Neutered Male

**AGE**

9 years

**WEIGHT**

13.8 lbs

**INTERPRETED BY**

Andrea Nicastro, DVM,  
Diplomate ACVIM (*Small  
Animal Internal Medicine*)

**IMAGING  
PERFORMED BY**

Dr. Gabriel Ferrer

**HOSPITAL NAME**

Paseos VC

**REFERRING VET**

Dr. Franco Ortiz

**INVOICE**

12797

**DATE**

4.20.23

**PRESENTING CLINICAL SIGNS**

History: Presented as a recheck abdominal ultrasound 6 months as recommended by previous study done on 9-22-22. Pt is having diarrhea and sporadic vomiting. There is pot belly abdomen Recommend re check ultrasound suspect Cushings and /or liver hepatopathy plus possible IBD bouts will treat GI signs and schedule abdominal ultrasound ASAP +/- LDDST if indicated

Abnormal PE/Chem/CBC/UA Results: fecal - neg cbc - wnl

**ULTRASONOGRAPHIC EXAMINATION OF THE ABDOMEN**

**Urinary System**

The urinary bladder wall is normal in thickness and the mucosal surface is smooth. The bladder is moderately distended. Luminal contents are anechoic. No cystic calculi are observed. The region of the trigone and the proximal urethra, visible to a depth of 1-2 cm, are normal.

The prostate is normal in size (0.96 cm in width) and shape. Parenchyma is homogenous. The prostatic urethra appears normal without evidence of dilation or obstruction.

The left kidney is normal in size (4.95 cm in length) with a normal shape, architecture and smooth peripheral margins. The cortex is isoechoic relative to the spleen with a few cortical cysts visualized. Hyperechoic shadowing diverticular foci are visualized. There is a normal 1:3 cortex to medulla ratio with moderate loss of corticomedullary distinction. There is no evidence of pyelectasia, infarcts or hydroureter.

The right kidney is normal in size (4.57 cm in length) with a normal shape, architecture and smooth peripheral margins. The cortex is isoechoic relative to the spleen with several cortical cysts visualized. There is a normal 1:3 cortex to medulla ratio with moderate loss of corticomedullary distinction. There is no evidence of pyelectasia, nephroliths, infarcts or hydroureter.

**Adrenal Glands**

The left adrenal gland is normal in size (0.43 cm at cranial pole) (0.47 cm at caudal pole) (2.01 cm in length) with a normal shape and homogenous parenchyma. The glandular echogenicity and detail are unremarkable. Capsule, cortex, and medullary definition are normal. The phrenicoabdominal vein and surrounding vasculature are normal.

The right adrenal gland is borderline enlarged (0.96 cm at cranial pole) (0.55 cm at caudal pole) (1.79 cm in length) with a normal shape and homogenous parenchyma. The glandular echogenicity and detail are unremarkable. Capsule, cortex, and medullary definition are normal. The phrenicoabdominal vein and surrounding vasculature are normal.

**Spleen**

The spleen is normal in size (1.42 cm in width at the level of the hilus) with a normal capsular contour. There is appropriate echogenicity and echotexture. A 0.40 cm ill-defined hypoechoic nodule is observed at the medial aspect. Splenic vasculature is normal.

**Liver**

The liver is subjectively prominent to enlarged with slightly swollen peripheral contours. At the tip of the left lateral lobe, the peripheral margin is slightly irregular. The parenchyma is isoechoic relative to the spleen. A 0.69 cm ill-defined hypoechoic nodule/area is observed on the left side. The remaining parenchyma is homogenous. Hepatic vasculature and intrahepatic biliary tracts are of normal volume with no evidence of congestion.



**PATIENT**

Yoshi Hoffman

The gall bladder lumen is moderately distended. The wall is thin and smooth. A small to moderate amount of echogenic, mostly gravity-dependent debris is observed within the lumen. The cystic and common bile ducts are normal/not seen.

**SPECIES**

Canine

**Gastrointestinal**

The stomach and intestine are free of stasis and exhibit normal peristaltic activity. The gastric lumen is not distended. The gastric wall and pylorus are normal in thickness with a normal layering pattern. The pyloric outflow tract is patent. The small intestinal lumen is not dilated. The small intestinal wall is normal in thickness with a normal layering pattern and appropriate mural detail. Discreet masses are not identified. The colonic wall is normal. There is no evidence of an obstructive pattern.

**BREED**

Yorkshire Terrier

**Pancreas**

The right limb is prominent in size with minimal deviation from the normal peripheral contours. The parenchyma is largely isoechoic relative to surrounding omental fat and mottled in appearance. A 0.64 cm hypoechoic nodule is observed near the base. The pancreatic duct is not overtly dilated.

**SEX**

Neutered Male

**Free Abdomen**

The mesentery in the cranial abdomen is hyperechoic. There is no obvious evidence of free fluid. The abdominal lymph nodes are normal/not visible.

**AGE**

9 years

**ULTRASONOGRAPHIC FINDINGS**

**WEIGHT**

13.8 lbs

**Primary Findings**

- The etiology of the hyperechoic mesentery in the cranial abdomen is unclear. It may be secondary to gastroenteritis, mild pancreatitis, other.
- There is evidence of age-related pancreatic remodeling +/- fibrosis. The pancreatic nodule likely represents benign nodular hyperplasia with a lower possibility of an emerging tumor.

**INTERPRETED BY**

Andrea Nicastro, DVM,  
Diplomate ACVIM (*Small  
Animal Internal Medicine*)

**IMAGING  
PERFORMED BY**

Dr. Gabriel Ferrer

**Secondary Findings**

- The bilateral renal changes are consistent with interstitial nephrosis/nephritis with cortical cyst. Changes are similar to the previous sonogram.
- Borderline right adrenomegaly
- The splenic nodule trends toward the benign (i.e., focus of lymphoid hyperplasia or similar) with a lower possibility of an emerging tumor.
- The diffuse hepatic parenchymal changes are most consistent with vacuolar hepatopathy (i.e., idiopathic/endocrine). However, correlation with the patient's liver values is recommended. The hepatic nodule also trends toward the benign (i.e., regenerative nodule) with a lower possibility of an emerging tumor, granuloma, inflammatory focus, other.

**HOSPITAL NAME**

Paseos VC

**REFERRING VET**

Dr. Franco Ortiz

**INTERPRETATION OF THE FINDINGS & FURTHER RECOMMENDATIONS**

**INVOICE**

12797

- Baseline lab work, including a CBC, chemistry panel, urinalysis and T4 is recommended (if not performed recently).

**DATE**

4.20.23

- Given the sonographic change, consider a cPLI +/- a full malabsorption panel, including serum cobalamin and folate, TLI and PLI to further assess for pancreatitis and maldigestion/malabsorption.



## PATIENT

Yoshi Hoffman

## SPECIES

Canine

## BREED

Yorkshire Terrier

## SEX

Neutered Male

## AGE

9 years

## WEIGHT

13.8 lbs

## INTERPRETED BY

Andrea Nicastro, DVM,  
Diplomate ACVIM (*Small Animal Internal Medicine*)

## IMAGING PERFORMED BY

Dr. Gabriel Ferrer

## HOSPITAL NAME

Paseos VC

## REFERRING VET

Dr. Franco Ortiz

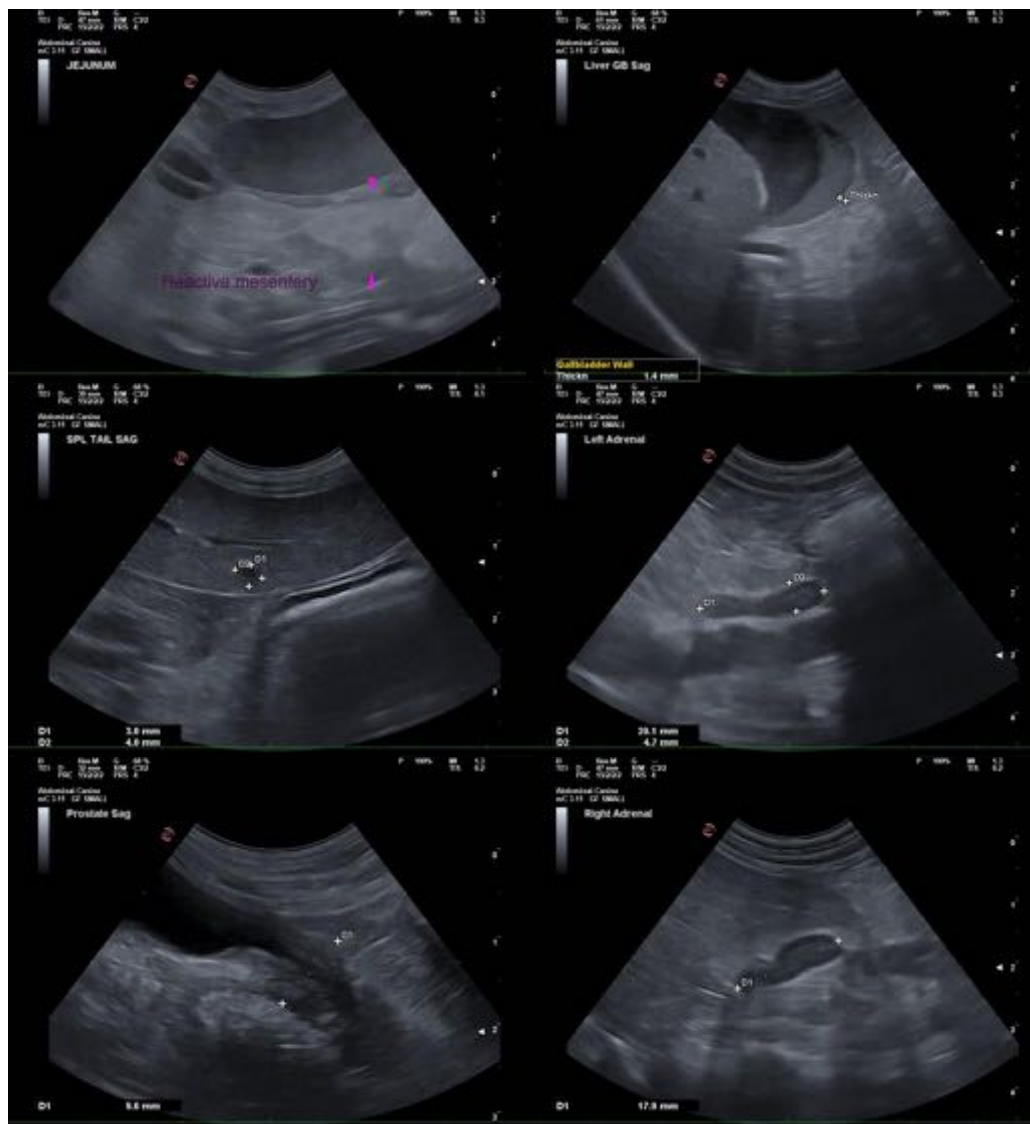
## INVOICE

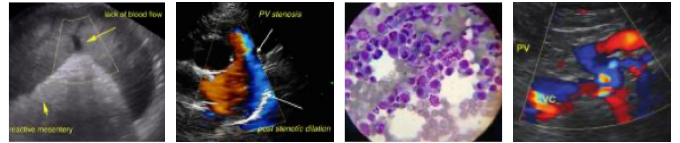
12797

## DATE

4.20.23

- A fecal evaluation for ova and Giardia is also recommended (if not already performed).
- Prophylactic deworming with Fenbendazole is also recommended.
- If the vomiting and diarrhea are chronic in nature, consider a 2-4-week limited antigen or hydrolyzed protein diet trial.
- A probiotic +/- fiber supplement (i.e., Metamucil or Konsyl) may also be beneficial.
- Ultimately, endoscopic or surgical biopsies may be necessary to get a definitive diagnosis.
- Once the patient's GI signs have been addressed, if signs of Cushing's disease are present, consider further testing (i.e., low-dose dexamethasone suppression test or ACTH stimulation test).





**PATIENT**

Yoshi Hoffman

**SPECIES**

Canine

**BREED**

Yorkshire Terrier

**SEX**

Neutered Male

**AGE**

9 years

**WEIGHT**

13.8 lbs

**INTERPRETED BY**

Andrea Nicastro, DVM,  
Diplomate ACVIM (Small  
Animal Internal Medicine)

**IMAGING  
PERFORMED BY**

Dr. Gabriel Ferrer

**HOSPITAL NAME**

Paseos VC

**REFERRING VET**

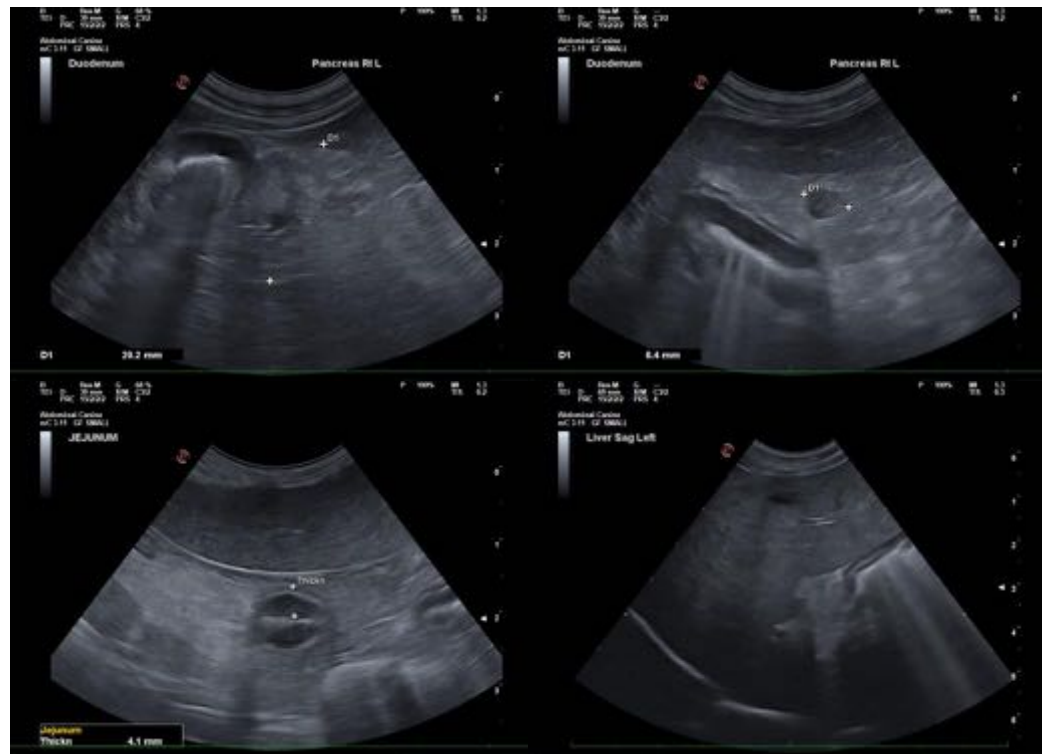
Dr. Franco Ortiz

**INVOICE**

12797

**DATE**

4.20.23



The information and recommendations provided are based on the images presented by the referring veterinarian/sonographer. No evaluation can be communicated regarding pathology that was not visible in the image/video clips provided.

Thank you for this referral. If the clinical or image interpretation does not parallel your findings or if I can be of any further assistance, please contact me.

**Andrea Nicastro, MPH, DVM, Diplomate DACVIM (Small Animal Internal Medicine)**  
[info@SonoPath.com](mailto:info@SonoPath.com)