

**PATIENT PRESENTING CLINICAL SIGNS**

Ozzie Roberts History: PU/PD, proteinuria. No change despite Telmisartan UPC 1.9. Current meds: 1) Telmisartan 10 mg SID, 2 )Benazepril 10 SID.

**SPECIES ULTRASONOGRAPHIC EXAMINATION OF THE ABDOMEN**

Canine **Urinary System**

The urinary bladder is moderately distended. The wall in the region of the apex is thickened and irregular with several polypoid-like lesions. The remaining urinary bladder wall is normal in thickness with a smooth mucosal surface. Several cystic calculi are observed within the lumen (the largest measuring approximately 0.40 cm in diameter). The region of the trigone and visible portion of the proximal urethra are normal.

**BREED**

Welsh Terrier

**SEX**

The prostate is normal in size (0.94 cm in width) and shape. Parenchyma is homogenous. The prostatic urethra appears normal without evidence of dilation or obstruction.

Neutered Male

The left kidney is normal in size (5.32 cm in length) with a normal shape, architecture and smooth peripheral margins. There is a normal 1:3 cortex to medulla ratio with moderate loss of corticomedullary distinction. There is no evidence of pyelectasia, nephroliths, infarcts or hydronephrosis.

**AGE**

12 years

The right kidney is normal in size (5.67 cm in length) with a normal shape, smooth peripheral margins, and normal internal architecture. There is moderate loss of corticomedullary distinction. Several hyperechoic shadowing diverticular foci are observed. There is no evidence of pyelectasia, infarcts or hydronephrosis.

**WEIGHT**

23.6 lbs

**Adrenal Glands**

The left adrenal gland is enlarged (1.71 cm at cranial pole) (2.22 cm at caudal pole) (3.43 cm in length) with a mass effect. The parenchyma is heterogenous and vascular in appearance, with complete loss of glandular detail. There is no obvious evidence of vascular invasion.

**INTERPRETED BY**

Andrea Nicastro, DVM,  
Diplomate ACVIM (Small  
Animal Internal Medicine)

The right adrenal gland is in normal size (0.80 cm at cranial pole) (0.51 cm at caudal pole) (2.04 cm in length) with a normal shape and homogenous parenchyma. The glandular echogenicity and detail are unremarkable. Capsule, cortex, and medullary definition are normal. The phrenicoabdominal vein and surrounding vasculature are normal.

**IMAGING PERFORMED BY**

Pamela Harrigan, RDCS

**Spleen**

The spleen is normal in size (1.22 cm in width at the level of the hilus) with a normal capsular contour. The parenchyma is subtly mottled in appearance. A 0.53 cm hypoechoic nodule is observed approximately mid-spleen. Splenic vasculature is normal.

**HOSPITAL NAME**

Norfolk County VS

**Liver**

The liver is subjectively prominent in size with normal curvilinear peripheral contours. The parenchyma is isoechoic relative to the spleen and subtly mottled in appearance. A 1.63 cm isoechoic nodule is observed deep on the left side. Hepatic vasculature and intrahepatic biliary tracts are of normal volume with no evidence of congestion.

**REFERRING VET**

Aurora Richards,  
DVM

The gall bladder lumen is moderately distended. The wall is thin and smooth. A moderate amount of echogenic sludge is observed within the lumen (most of which is suspended, some of which is adhered to the luminal surface). The cystic and common bile ducts are normal/not seen.

**INVOICE**

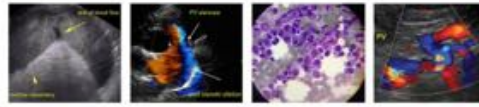
12813

**Gastrointestinal**

The stomach and intestine are free of stasis and exhibit normal peristaltic activity. The gastric lumen is mildly distended with ingesta. The gastric wall and pylorus are normal in thickness with a normal layering pattern. The pyloric outflow tract is patent. The small intestinal lumen is not dilated. The small intestinal wall is normal in thickness with a normal layering pattern and appropriate mural

**DATE**

4.20.23



**PATIENT**

Ozzie Roberts

detail. Discreet masses are not identified. The ileocecolic junction and colonic wall are normal. There is no evidence of an obstructive pattern.

**SPECIES**

Canine

**Pancreas**

The right limb of the pancreas is visible with normal curvilinear peripheral contours. The parenchyma is slightly hyperechoic relative to surrounding omental fat and slightly mottled in appearance. The pancreatic duct is visible but not overtly dilated. There is no evidence of peripancreatic inflammation or effusion.

**BREED**

Welsh Terrier

**Free Abdomen**

There is no obvious evidence of free fluid. The abdominal lymph nodes are normal/not visible.

**ULTRASONOGRAPHIC FINDINGS**

**SEX**

Neutered Male

**Primary Findings**

- Left adrenal mass effect. Neoplasia (i.e., adenoma, adenocarcinoma, pheochromocytoma) is consider likely. Benign macronodular hyperplasia cannot be completely excluded.
- The hepatic parenchymal changes are nonspecific and could be secondary to to vacuolar hepatopathy, regenerative nodular hyperplasia, age-related remodeling, inflammatory disease, fibrosis, other hepatopathy, or some combination thereof. Correlation with the patient's liver values is recommended. The left hepatic nodule could be consistent with a regenerative nodule, an emerging tumor, granuloma, inflammatory focus, other.
- The gall bladder changes could be consistent with an emerging mucocele, cholestasis or less likely, fasting.
- Cystic calculi. The urinary bladder wall changes in the region of the apex are most consistent with polypoid cystitis, with a lower possibility of emerging neoplasia.

**AGE**

12 years

**WEIGHT**

23.6 lbs

**INTERPRETED BY**

Andrea Nicastro, DVM,  
 Diplomate ACVIM (Small  
 Animal Internal Medicine)

**Secondary Findings**

- The pancreatic changes are most consistent with age-related parenchymal remodeling, potentially secondary to a prior inflammatory episode, early fibrosis or chronic pancreatitis.
- Bilateral chronic age-related renal changes
- The splenic parenchymal changes are most consistent with a benign process such as lymphoid hyperplasia, extramedullary hematopoiesis, splenitis or antigenic stimulation with a low possibility of infiltrative neoplasia (i.e., lymphoma, mast cell neoplasia).

**IMAGING PERFORMED BY**

Pamela Harrigan, RDCS

**HOSPITAL NAME**

Norfolk County VS

**INTERPRETATION OF THE FINDINGS & FURTHER RECOMMENDATIONS**

- Given the left adrenal changes, consider the following:
  1. Three-view thoracic radiographs to assess for metastatic disease
  2. Baseline blood pressure measurement
  3. Further testing for a functional tumor (i.e., low-dose dexamethasone suppression test, urine/blood catecholamine levels)
  4. +/- abdominal CT scan to assess for vascular invasion, particularly if an adrenalectomy is to be considered.

**REFERRING VET**

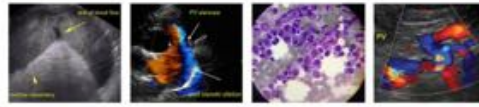
Aurora Richards,  
 DVM

**INVOICE**

12813

**DATE**

4.20.23



**PATIENT**

Ozzie Roberts

**SPECIES**

Canine

**BREED**

Welsh Terrier

**SEX**

Neutered Male

**AGE**

12 years

**WEIGHT**

23.6 lbs

**INTERPRETED BY**

Andrea Nicastro, DVM,  
 Diplomate ACVIM (Small  
 Animal Internal Medicine)

**IMAGING PERFORMED BY**

Pamela Harrigan, RDCS

**HOSPITAL NAME**

Norfolk County VS

**REFERRING VET**

Aurora Richards,  
 DVM

**INVOICE**

12813

**DATE**

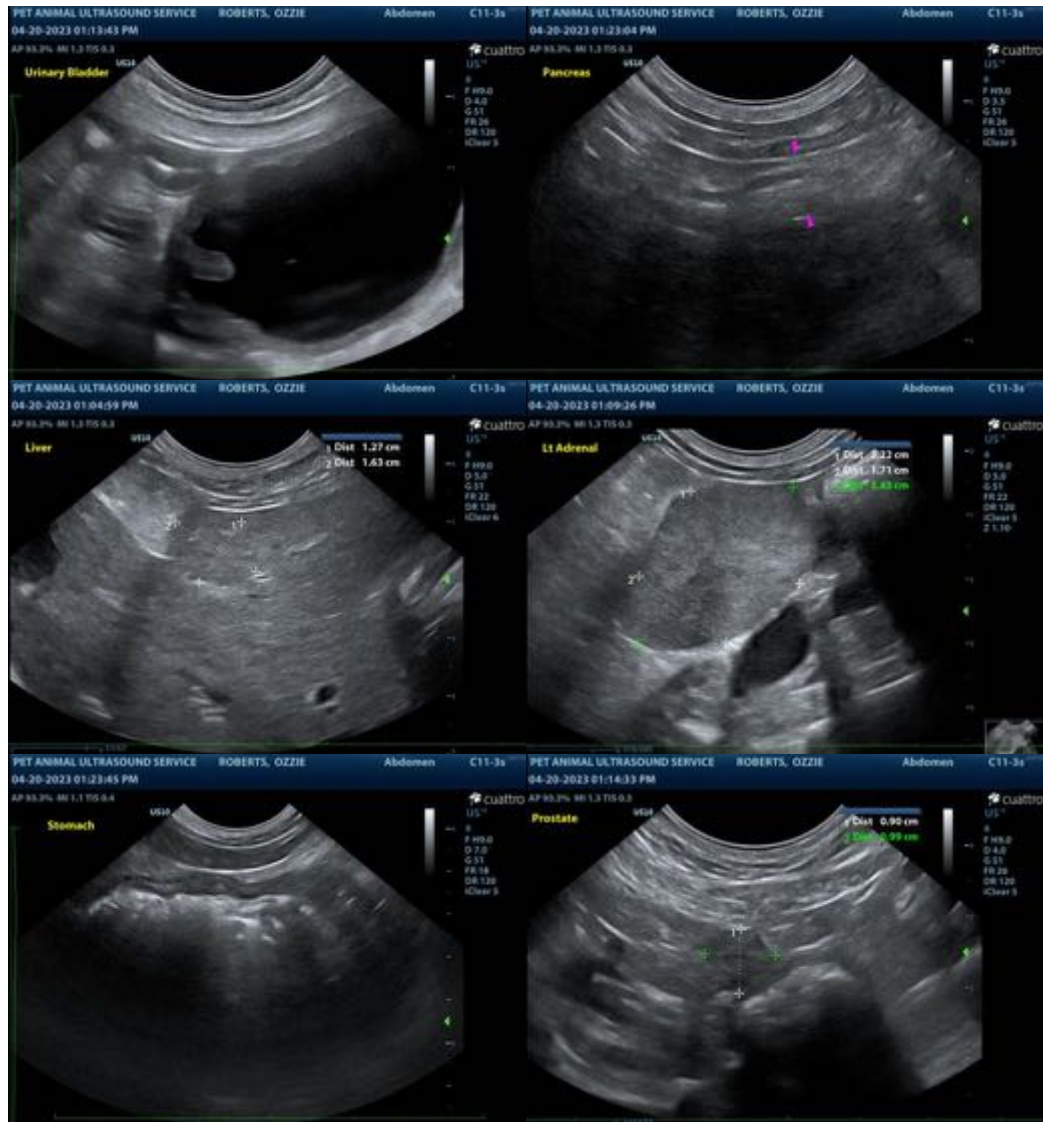
4.20.23

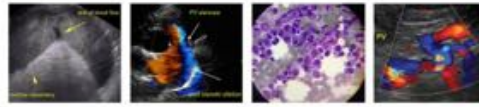
- Regarding the refractory proteinuria, consider the following:

1. Adjustment in the Telamasartin and/or Benazepril dosage
2. Initiation of omega 3 fatty acids
3. Transition to a prescription renal diet
4. Address systemic hypertension (if present).

- Regarding the hepatic nodule, consider a fine-needle aspirate (if clotting status is appropriate). A 25-gauge needle should be used. If aspiration is not pursued at this time, consider a repeat ultrasound in 4-8 weeks to assess for growth.

- Regarding the cystic calculi, consider a cystotomy with stone removal, analysis and culture, or an attempt at medical dissolution (i.e., broad-spectrum antibiotics, urinary diet).





**PATIENT**

Ozzie Roberts

**SPECIES**

Canine

**BREED**

Welsh Terrier

**SEX**

Neutered Male

**AGE**

12 years

**WEIGHT**

23.6 lbs

**INTERPRETED BY**

Andrea Nicastro, DVM,  
 Diplomate ACVIM (Small  
 Animal Internal Medicine)

**IMAGING PERFORMED BY**

Pamela Harrigan, RDCS

**HOSPITAL NAME**

Norfolk County VS

**REFERRING VET**

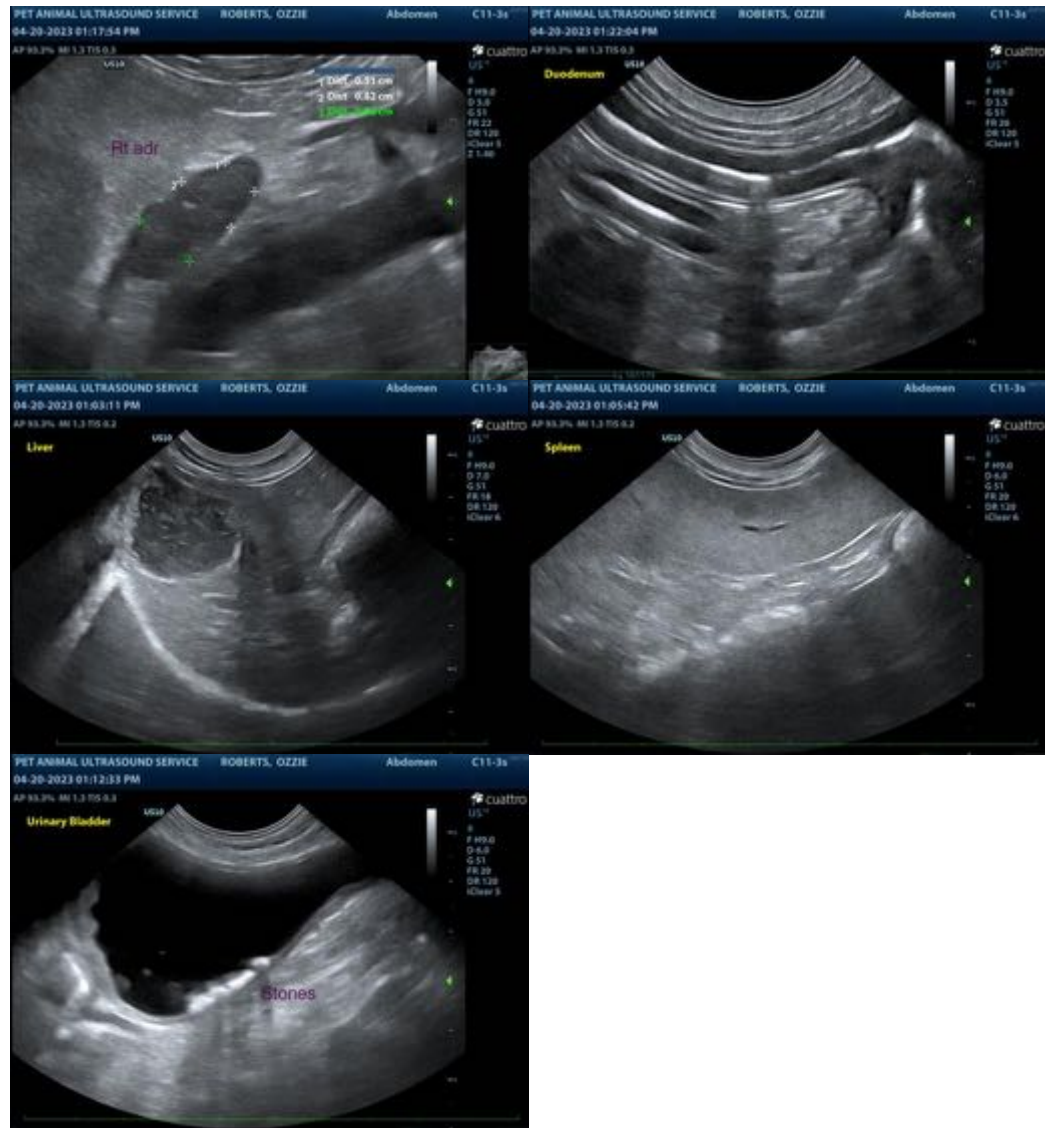Aurora Richards,  
 DVM

**INVOICE**

12813

**DATE**

4.20.23



The information and recommendations provided are based on the images presented by the referring veterinarian/sonographer. No evaluation can be communicated regarding pathology that was not visible in the image/video clips provided.

Thank you for this referral. If the clinical or image interpretation does not parallel your findings or if I can be of any further assistance, please contact me.

Andrea Nicastro, MPH, DVM, Diplomate DACVIM (Small Animal Internal Medicine)  
[info@SonoPath.com](mailto:info@SonoPath.com)