

**DATE PRESENTING CLINICAL SIGNS**

4/20/2022

Flare-up of decreased appetite, vomiting. Went to ER for 24 hours IV fluids and supportive care. Hx: asthma, diabetes, pancreatitis, liver masses (suspected benign). Owner reported ER heard a new murmur; unknown grade (waiting on ER records). ProBNP had been submitted due to chronic pred and returned normal.

PATIENT

Fezzik Conroy

SPECIES

Feline

BREED

DMH

SEX

Neutered Male

AGE

9/6/2006

WEIGHT

15.16 lbs

INTERPRETED BY

Andrea Nicastro,
DMV, Diplomate
DACVIM (Small
Animal
Internal Medicine)

HOSPITAL NAME

Frederick Road
Veterinary Hospital

REFERRING VET

Dr. Beyer

INVOICE

10777

Current Medications: Prednisolone 10mg/mL 0.3mL SID, Lantus insulin 1 unit BID, Cerenia PRN, Dasuquin, Gabapentin for vet visits- 100mg the night before and am of US.

Lab Results: Spec FPL 11.2 (0.0-3.5). Spec FPL last flare up was 50 in 2020 (at recheck several days after ER stay). SDMA 12 (0-14), Creat 1.7 (0.9-2.3), BUN/UREA 49 (16-37), ALKP 71 (12-59), ALT was elevated at ER.

Date of Previous IntraPet Ultrasound: 1/8/20. See attached.

Sedation: Not required to complete full diagnostic ultrasound.

Stat Report: Not requested.

Imaging Performed By: Andi Parkinson, RDMS.

ULTRASONOGRAPHIC EXAMINATION OF THE ABDOMEN**Urinary System**

The urinary bladder, trigone, and pelvic urethra are normal in thickness and the mucosal surface is smooth. The bladder lumen is moderately distended with mostly anechoic urine. No masses, inflammatory changes or calculi are observed. The region of the trigone and the visible portion of the proximal urethra are normal.

The left kidney is normal size (4.27 cm in length); with a slightly irregular shape and architecture with smooth peripheral margins. There is a normal 1:3 cortex to medulla ratio with minimal to mild loss of corticomedullary distinction. A few nonobstructive nephroliths are visualized. There is no evidence of pyelectasia or hydroureter.

The right kidney is normal size (4.48 cm in length); with a slightly irregular shape and architecture with smooth peripheral margins. There is a normal 1:3 cortex to medulla ratio with minimal to mild loss of corticomedullary distinction. A few nonobstructive nephroliths are visualized. A cortical infarct is observed at the caudolateral aspect. There is no evidence of pyelectasia or hydroureter.

Adrenal Glands

The left adrenal gland is normal size (0.29 cm width). Normal shape and glandular echogenicity. The phrenicoabdominal vein and surrounding vasculature are normal.

The right adrenal gland is normal size (0.35 cm width). Normal shape and glandular echogenicity. The phrenicoabdominal vein and surrounding vasculature are normal.

Spleen

The spleen is normal in size (0.90 cm in width at the level of the hilus) with a normal capsular contour. There is appropriate echogenicity and echotexture. No focal lesions are observed. Splenic vasculature is normal.

Liver

The liver is subjectively enlarged with swollen/irregular peripheral contours. Several multiseptated, cystic and heterogenous nodules/masses are observed throughout the organ, the largest measuring 3.63 x 3.16

cm. Some of the parenchyma is homogenous, whereas in other areas, there is heterogeneity. Hepatic vasculature and intrahepatic biliary tracts are of normal volume with no evidence of congestion.

The gall bladder lumen is moderately distended. The wall is thin and smooth. A moderate amount of aggregated, echogenic to mineralized, gravity dependent debris is observed within the lumen. The cystic and common bile ducts are normal.

Gastrointestinal

The gastric lumen is mildly distended with ingesta and soft, shadowing material. The gastric wall and pylorus are normal in thickness with a normal layering pattern. The pyloric outflow tract is patent. The small intestinal lumen is not dilated. The small intestinal wall thickness is normal with a normal layering pattern and appropriate mural detail. Discreet masses are not identified. The colonic wall is normal. No obstructive disease is noted.

Pancreas

The left limb of the pancreas is visible with normal curvilinear peripheral contours. The parenchyma is largely isoechoic relative to surrounding omental fat and slightly mottled in appearance. The pancreatic duct is visible but not overtly dilated. There is no evidence of peripancreatic inflammation or effusion.

Free Abdomen

There is no evidence of free fluid. The abdominal lymph nodes are normal/not visible.

ULTRASONOGRAPHIC FINDINGS

Primary Findings

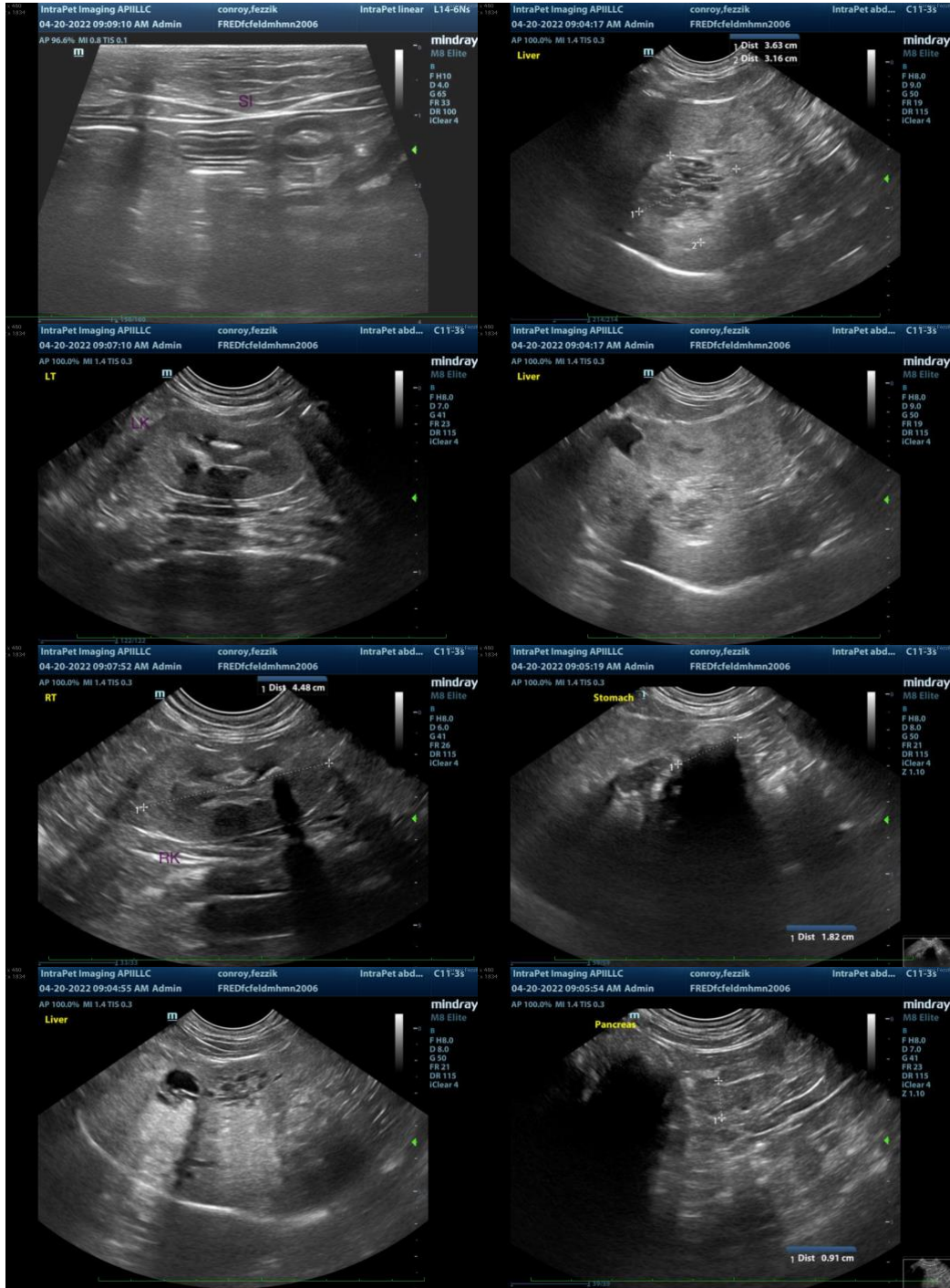
- Multiple, cystic, heterogenous hepatic masses. Top differentials include biliary cystadenoma and cystadenocarcinoma. The lesions have progressed since the previous scan. The diffuse hepatic parenchyma changes could be consistent with an inflammatory hepatopathy (i.e., bacterial cholangiohepatitis, lymphoplasmacytic hepatitis), age-related remodeling, hepatic lipidosis, infiltrative neoplasia (less likely), other hepatopathy.

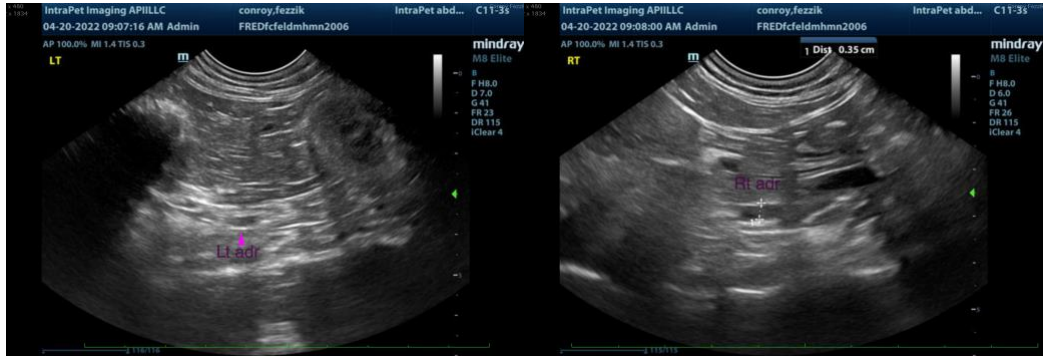
Secondary Findings

- Bilateral age-related renal changes with nonobstructive nephrocalcinosis and a right cortical infarct. Changes are similar to the previous sonogram.
- Age-related pancreatic remodeling +/- fibrosis. Chronic low-grade pancreatitis is also a possibility, particularly if the patient exhibits pain on cranial abdominal palpation. Changes are similar to the previous sonogram.
- The gastric luminal contents could be consistent with normal ingesta and/or foreign material (i.e., hair).

INTERPRETATION OF THE FINDINGS & FURTHER RECOMMENDATIONS

Supportive care for gastroenteritis is recommended. Also consider a fecal evaluation for ova and Giardia and a malabsorption panel, including serum cobalamin and folate, TLI and PLI. If clinical signs do not improve within 48-72 hours of supportive care, consider repeat abdominal imaging to reassess the shadowing material in the gastric lumen +/- GI biopsies (i.e., endoscopic or surgical). A liver biopsy should also be obtained if surgery is pursued.





The information and recommendations provided are based on the images presented by the referring veterinarian/sonographer. No evaluation can be communicated regarding pathology that was not visible in the image/video clips provided.

Thank you for this referral. If the clinical or image interpretation does not parallel your findings or if I can be of any further assistance, please contact me.

Andrea Nicastro, DVM, Diplomate DACVIM (Small Animal Internal Medicine)
info@SonoPath.com