

**DATE PRESENTING CLINICAL SIGNS**

4/20/2022

Diabetic for almost one year. Had an episode of hypoglycemia one week ago (which was managed at home due to his fractious nature). Owner took to the ER because pet was not eating well in the next few days following his hypoglycemic episode.

**PATIENT**

Blackie McDonald

Current Medications: Metronidazole 60 mg BID since ER visit, Mirtazapine (15 mg T) 1/4 tablet every 3 days. no insulin since blood sugar was still normal at ER.

**SPECIES**

Lab Results: From ER: PCV/TS: 35/ 8.2. CBC: Hct = 33.4, WBC: 8.98, plt - 237. Chem: glob = 5.8, Alt = 370, Alkp = 447, GGT = 11, Bili = 1.4

Feline

Radiographs: From ER: There is stool in the descending colon, does not appear to be overly firm. Kidneys are different sizes w/ one appearing to be small, hepatomegaly, decrease in abdominal detail, large urinary bladder.

**BREED**

DSH

Date of Previous IntraPet Ultrasound: No previous.

**SEX**

Neutered Male

Sedation: Not required to complete full diagnostic ultrasound.

Stat Report: Not requested.

Imaging Performed By: Andi Parkinson, RDMS.

**AGE**

6/16/2011

**ULTRASONOGRAPHIC EXAMINATION OF THE ABDOMEN****WEIGHT**

14 lbs

**Urinary System**

The urinary bladder, trigone, and pelvic urethra are normal in thickness and the mucosal surface is smooth. The bladder lumen is moderately distended with mostly anechoic urine. No masses, inflammatory changes or calculi are observed. Ureteral papillae and visualized portion of the proximal urethra, visible to a depth of 2 cm, are normal.

**INTERPRETED BY**

Andrea Nicastro,  
DMV, Diplomate  
DACVIM (Small  
Animal  
Internal Medicine)

The left kidney is normal size (3.92 cm in length); normal shape and architecture with smooth peripheral margins. The cortex is mildly thickened and there is moderate loss of corticomedullary distinction. Hyperechoic shadowing diverticular foci are visualized. There is no evidence of pyelectasia, infarcts or hydroureter.

The right kidney is normal size (3.78 cm in length); normal shape and architecture with smooth peripheral margins. The cortex is mildly thickened and there is moderate loss of corticomedullary distinction. Hyperechoic shadowing diverticular foci are visualized. There is no evidence of pyelectasia, infarcts or hydroureter.

**HOSPITAL NAME**

Harborside Mobile  
Veterinary Clinic

**Adrenal Glands**

The region of the adrenal glands is evaluated. No obvious pathology is observed.

**REFERRING VET**

Dr. Hawkins

**Spleen**

The spleen is subjectively enlarged (1.14 cm in width at the level of the hilus) with slightly swollen peripheral contours. There is appropriate echogenicity and echotexture. No focal lesions are observed. Splenic vasculature is normal.

**INVOICE**

10776

**Liver**

The liver is subjectively enlarged with slightly swollen peripheral contours. The parenchyma is subjectively hypoechoic. An ill-defined, multiseptated cystic area is observed on the right side. The remaining parenchyma is homogenous. Hepatic vasculature and intrahepatic biliary tracts are of normal volume with no evidence of congestion. The portal vein to caudal vena cava ratio is approximately 1: 1.

The gall bladder is moderately distended. A bilobed conformation is suspected. The wall is normal in thickness. A small amount of echogenic debris is observed within the lumen. The cystic and common bile ducts are visible/tortuous, but not overtly dilated. A small amount of echogenic debris is observed within the common bile duct lumen.

### ***Gastrointestinal***

The gastric lumen is not distended. The gastric wall and pylorus are normal in thickness with a normal layering pattern. The pyloric outflow tract is patent. The small intestinal lumen is not dilated. The small intestinal wall overall all is normal in thickness with a normal layering pattern. There is disruption in the normal 1:3 muscularis: mucosal ratio in most segments. In one segment of small intestine, a mass appears to be engulfing the bowel loop with questionable invasion into the wall. The colonic wall is normal. There is no evidence of an obstructive pattern.

### ***Pancreas***

The left limb and base are prominent in size with minimal deviation from the normal peripheral contours. The parenchyma is slightly hypoechoic relative to surrounding omental fat and mottled in appearance. The pancreatic duct is visible, but not overtly dilated (0.18 cm in diameter). There is no evidence of peripancreatic effusion.

### ***Free Abdomen***

There is no obvious evidence of free fluid. Several enlarged, rounded, midabdominal lymph nodes are seen. In addition, a 0.93 cm gastric lymph node is visualized, as well as a few prominent lymph nodes in the right cranial quadrant. Surrounding mesentery is hyperechoic (see also "Other" category).

### ***Other***

A 4.31 x 3.20 cm irregular, hypoechoic mass is observed in the midabdominal cavity. The mass is engulfing a short segment of bowel, with possible invasion into the intestinal wall. Surrounding mesentery is hyperechoic.

## **ULTRASONOGRAPHIC FINDINGS**

### **Primary Findings**

- The origin of the mid-abdominal mass is unclear. It is thought to be arising from a mesenteric lymph node and engulfing +/- invading a segment of bowel. However, a bowel mass with invasion into lymph node cannot be completely excluded. Regional peritonitis is present.
- The diffuse abdominal lymphadenopathy could be consistent with infiltrative neoplasia (i.e., lymphoma, reactive lymphadenopathy or lymphoid hyperplasia).
- The diffuse small intestinal wall changes could be consistent with emerging lymphoma or inflammatory bowel disease.

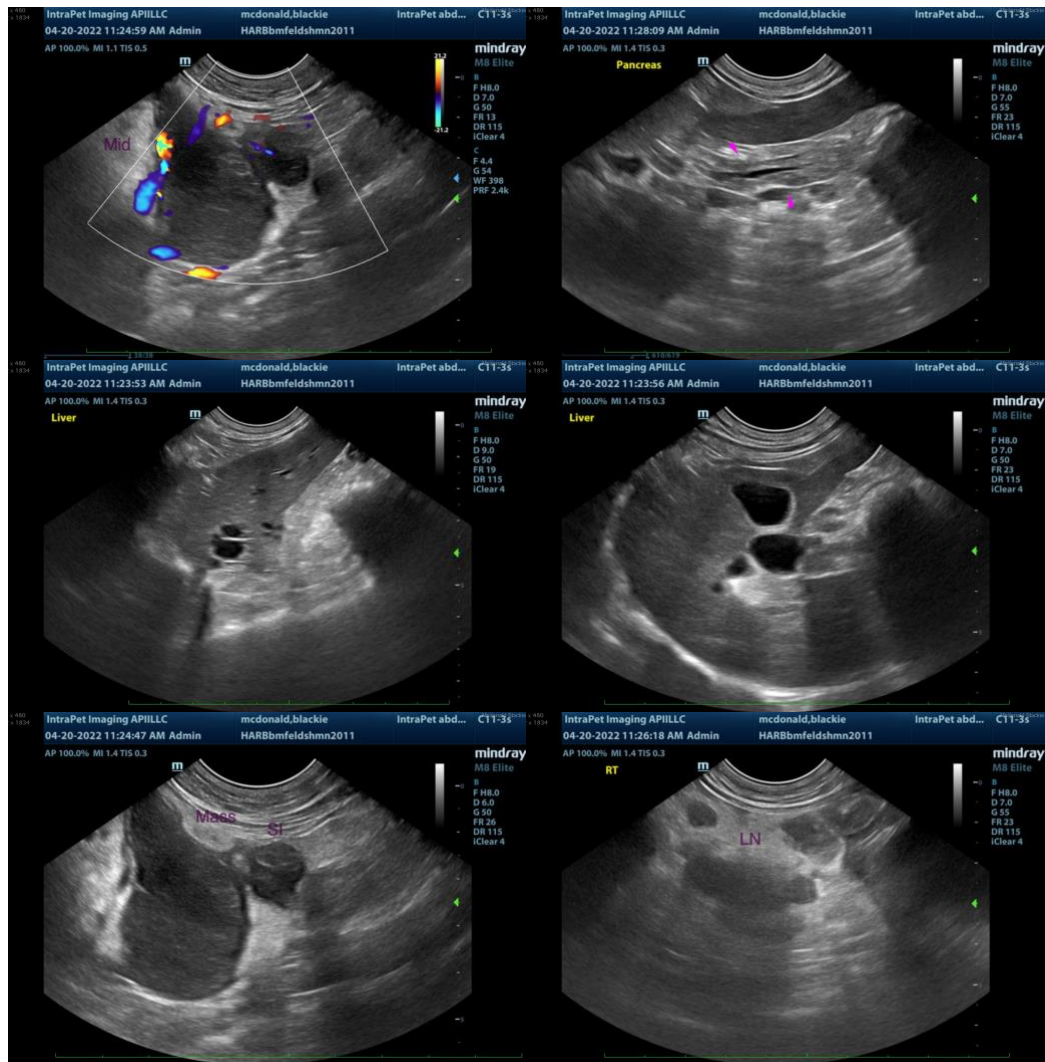
### **Secondary Findings**

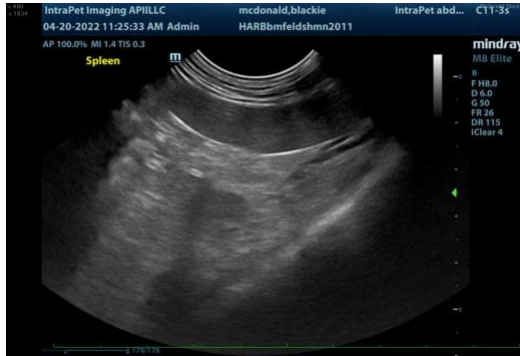
- Age-related pancreatic remodeling +/- fibrosis. Mild chronic pancreatitis may also be present. Correlation with the patient's clinical history is recommended.
- The bilateral renal changes are consistent with chronic interstitial nephrosis/nephritis.
- The splenomegaly may be secondary to infiltrative neoplasia, lymphoid hyperplasia, extramedullary hematopoiesis, splenitis or antigenic stimulation.

- The hepatic parenchymal changes could be consistent with infiltrative neoplasia, inflammatory disease, passive congestion, or other hepatopathy. The multiseptated, cystic hepatic lesion could be consistent with a biliary cystadenoma or cystadenocarcinoma. Cystadenoma is favored.

### INTERPRETATION OF THE FINDINGS & FURTHER RECOMMENDATIONS

- Three-view thoracic radiographs are recommended to assess for pulmonary metastases.
- Fine-needle aspirates of the midabdominal mass +/- liver and spleen can be considered (if clotting status is appropriate). If cytology results are inconclusive, surgical biopsies may be necessary to get a definitive diagnosis.
- A GI panel including serum cobalamin and folate, TLI and PLI is also recommended.





The information and recommendations provided are based on the images presented by the referring veterinarian/sonographer. No evaluation can be communicated regarding pathology that was not visible in the image/video clips provided.

Thank you for this referral. If the clinical or image interpretation does not parallel your findings or if I can be of any further assistance, please contact me.

**Andrea Nicastro, DVM, Diplomate DACVIM (Small Animal Internal Medicine)**  
info@SonoPath.com