

**DATE PRESENTING CLINICAL SIGNS**

4/18/22

Presents for recurrent urinary tract infections. Elevated liver values. Mild non regenerative anemia.

**PATIENT**

Teddy Hicks

Current Medications: Meds started 3/29/22- Thyro tabs 0.5mg BID, Marboquin 100mg SID for 14 days, Carprofen 50mg BID. Gabapentin 300mg 2-3 hours prior to AUS.

Lab Results: HCT 35.7%, ALT 311, ALP 244, Cholesterol 388, Hypothyroid diagnosed.

Date of Previous IntraPet Ultrasound: No previous.

Sedation: Torbugesic IV.

Stat Report: Not requested.

Imaging Performed By: Stephanie Pearce RDCS, RVT.

**SPECIES**

Canine

**BREED**

Coonhound mix

**SEX**

Male, neutered

**AGE**

3/12/2006

**WEIGHT**

66.9 lbs.

**INTERPRETED BY**

Andrea Nicastro, DVM,  
 Diplomate ACVIM  
 (Small Animal Internal  
 Medicine)

**HOSPITAL NAME**

Eastern AH

**REFERRING VET**

Dr. Haviland

**INVOICE**

13216

**ULTRASONOGRAPHIC EXAMINATION OF THE ABDOMEN****Urinary System**

The urinary bladder, trigone, and pelvic urethra are normal in thickness and the mucosal surface is slightly irregular. The bladder lumen is moderately distended. A scant amount of suspended echogenic debris is observed within the lumen. No masses, inflammatory changes or calculi are observed. Ureteral papillae and visualized portion of the proximal urethra, visible to a depth of 2 cm, are normal.

The prostate is normal in size (1.70 cm in width) and shape. Parenchyma is homogenous. The prostatic urethra appears normal without evidence of dilation or obstruction.

The left kidney is normal size (4.76 cm in length); normal shape and architecture with smooth peripheral margins. There is a normal 1:3 cortex to medulla ratio with minimal loss of corticomedullary distinction. Mild pyelectasia is present (0.30 cm in the longitudinal plane). A small cortical cyst is observed at the lateral aspect. There is no evidence of nephroliths, infarcts or hydroureter. Renal vasculature is normal.

The right kidney is normal size (5.77 cm in length); normal shape and architecture with smooth peripheral margins. There is a normal 1:3 cortex to medulla ratio with normal corticomedullary distinction. There is no evidence of pyelectasia, nephroliths, infarcts or hydroureter. Renal vasculature is normal.

**Adrenal Glands**

The left adrenal gland is normal size (0.50 cm at cranial pole) (0.52 cm at caudal pole) (2.25 cm in length); normal shape; homogenous parenchyma. The glandular echogenicity and detail are unremarkable. Capsule, cortex, and medullary definition are normal. The phrenicoabdominal vein and surrounding vasculature are normal.

The right adrenal gland is normal size (0.98 cm at cranial pole) (0.65 cm at caudal pole) (2.44 cm in length); normal shape; homogenous parenchyma. The glandular echogenicity and detail are unremarkable. Capsule, cortex, and medullary definition are normal. The phrenicoabdominal vein and surrounding vasculature are normal.

**Spleen**

The spleen is normal in size (2.33 cm in width at the level of the hilus) with a normal capsular contour. There is appropriate echogenicity and echotexture. No focal lesions are observed. Splenic vasculature is normal.

**Liver**

The liver is subjectively normal in size with normal contours and structure. There is appropriate echogenicity and echotexture. No overt structural evidence of inflammatory, infiltrative or regenerative pathology is evident. Vascular and biliary tracts are of normal volume with no evidence of congestion. No pathological hepatic lymphadenopathy observed. The gall bladder lumen is moderately distended. The wall is thin and smooth. Luminal contents are mostly anechoic. The cystic and common bile ducts are normal/not seen.

### ***Gastrointestinal***

The gastric lumen is not distended. The gastric wall is normal in thickness with a normal layering pattern. The small intestinal lumen is not dilated. The small intestinal wall thickness is normal with a normal layering pattern and appropriate mural detail. Discreet masses are not identified. The colonic wall is normal. No obstructive disease is noted.

### ***Pancreas***

The region of the pancreas is isoechoic relative to surrounding omental fat. No obvious parenchymal abnormalities are observed. There is no evidence of regional inflammation or effusion.

### ***Free Abdomen***

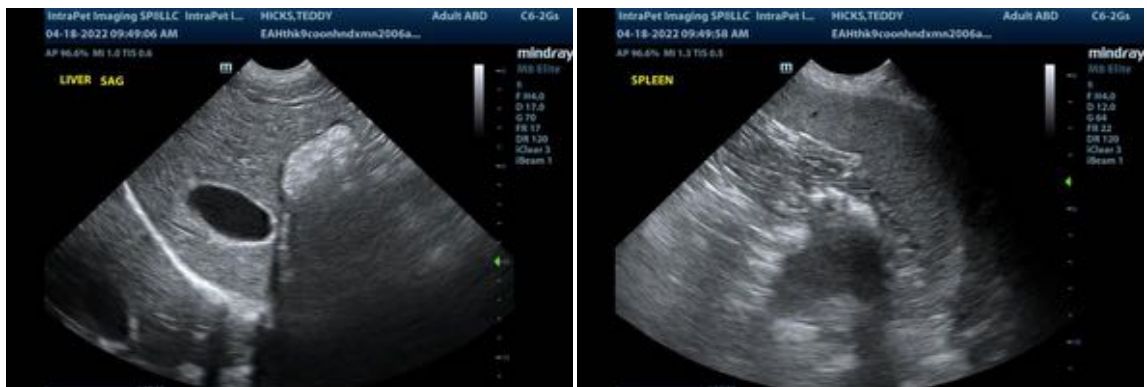
The peritoneal cavity is normal. There is no evidence of inflammation or effusion. The abdominal lymph nodes are normal/not visible.

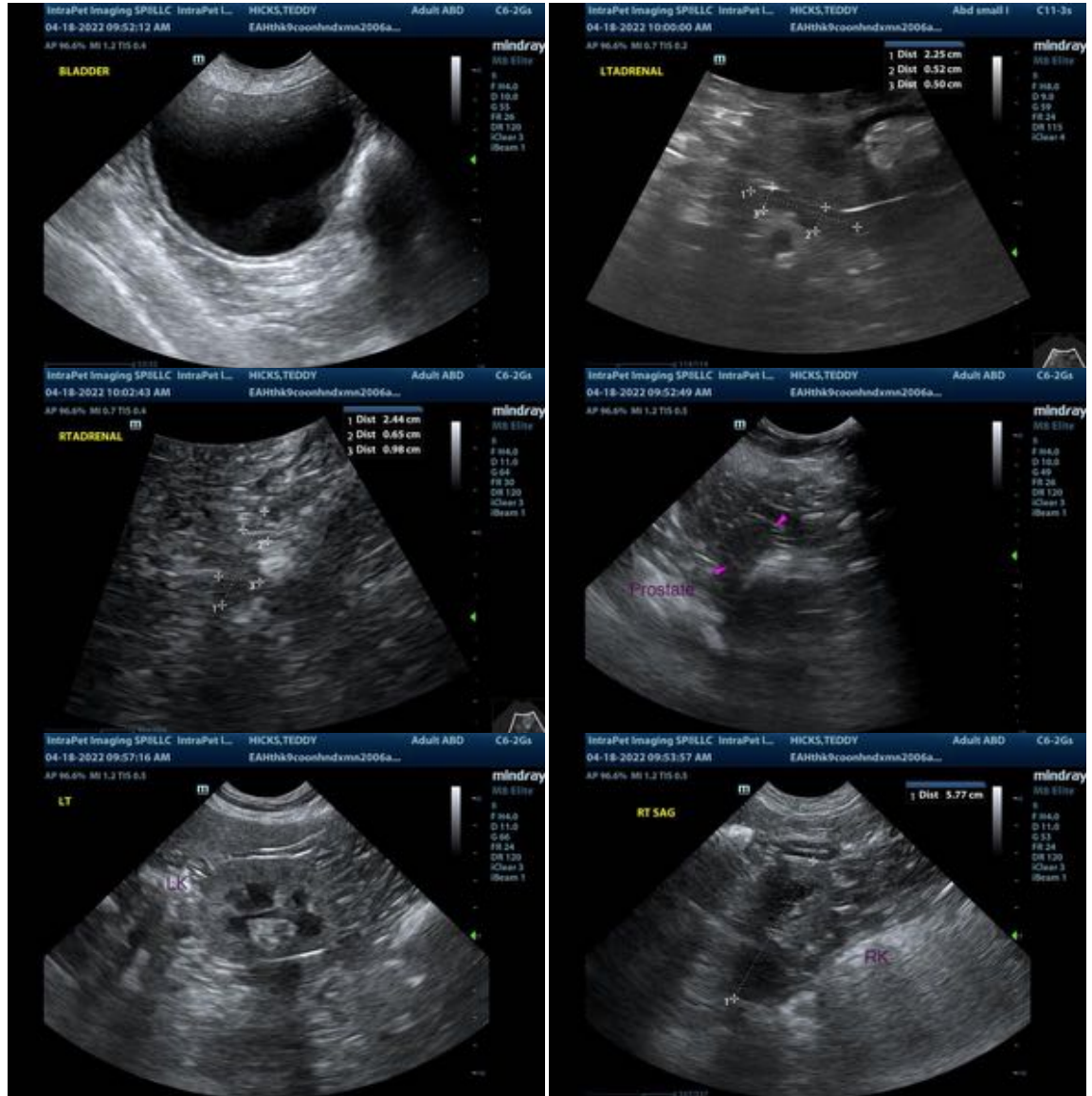
## **ULTRASONOGRAPHIC FINDINGS**

- Minor bilateral, age-related renal changes with left pyelectasia.
- An obvious cause for the elevated liver enzymes is not identified in the study. However, a microscopic hepatopathy (i.e., bacterial cholangiohepatitis, Leptospirosis, chronic active hepatitis, copper-associated hepatotoxicity, infiltrative neoplasia (less likely)) should be considered.

## **INTERPRETATION OF THE FINDINGS & FURTHER RECOMMENDATIONS**

- A urine culture and sensitivity is recommended, preferably on a pre-antibiotic sample or a sample collected 5-7 days after the last dose of antibiotics.
- Consider pre- and post-prandial serum bile acids to assess hepatic function, Leptospirosis testing (i.e., blood and urine PCR +/- hepatic tissue sampling (i.e., fine needle aspirate or surgical biopsy). If biopsies are pursued, aerobic and anaerobic bile cultures and acquisition of additional hepatic tissue samples for potential copper quantitation are recommended.
- If a more conservative approach is desired, consider rechecking liver values 5-7 days after initiating a broad-spectrum antibiotic therapy. If the liver values improve, continue antibiotics for at least 4 weeks and 1 week beyond normalization of the ALT. If liver values do not improve with antibiotics, hepatic tissue sampling should be reconsidered. Thoracic radiographs should be performed prior to anesthesia to assess cardiopulmonary status.





The information and recommendations provided are based on the images presented by the referring veterinarian. No evaluation can be communicated regarding pathology that was not visible in the image/video clips provided.

Thank you for this referral. If the clinical or image interpretation does not parallel your findings or if I can be of any further assistance please contact me.

Andrea Nicastro, DVM, Diplomate ACVIM (*Small Animal Internal Medicine*)  
 Andrea.nicastro@sonopath.com