

**DATE PRESENTING CLINICAL SIGNS**

4/18/22

Chronic vomiting, history of probable IBD, hyperthyroid.

PATIENT

Garfield Brennan

Current Medications: Methimazole 5mg ¼ SID.
 Date of Previous IntraPet Ultrasound: No previous.
 Sedation: Not required to complete full diagnostic ultrasound.
 Stat Report: Not requested.
 Imaging Performed By: Andi Parkinson

SPECIES

Feline

ULTRASONOGRAPHIC EXAMINATION OF THE ABDOMEN**Urinary System**

The urinary bladder, trigone, and pelvic urethra are normal in thickness and the mucosal surface is smooth. The bladder lumen is moderately distended with anechoic urine. No masses, inflammatory changes or calculi are observed. Ureteral papillae and visualized portion of the proximal urethra, visible to a depth of 2 cm, are normal.

BREED

Domestic shorthair

SEX

Male, neutered

The left kidney is normal size (3.43 cm in length); normal shape and architecture with smooth peripheral margins. There is a normal 1:3 cortex to medulla ratio with mild loss of corticomedullary distinction. There is no evidence of pyelectasia, nephroliths, infarcts or hydroureter.

AGE

2/14/2009

The right kidney is normal size (3.83 cm in length); normal shape and architecture with smooth peripheral margins. There is a normal 1:3 cortex to medulla ratio with mild loss of corticomedullary distinction. There is no evidence of pyelectasia, nephroliths, infarcts or hydroureter.

WEIGHT

13.6 lbs.

Adrenal Glands

The region of the left adrenal gland is evaluated. No obvious pathology is observed.

The right adrenal gland is normal in size (0.40 cm width). Normal shape and glandular echogenicity. The phrenicoabdominal vein and surrounding vasculature are normal.

INTERPRETED BY

Andrea Nicastro, DVM,
 Diplomate ACVIM
 (Small Animal Internal
 Medicine)

Spleen

The spleen is normal in size (0.69 cm in width at the level of the hilus) with a normal capsular contour. There is appropriate echogenicity and echotexture. No focal lesions are observed. Splenic vasculature is normal.

HOSPITAL NAME

White Marsh AH

Liver

The liver is subjectively normal in size with normal contours and structure. There is appropriate echogenicity and echotexture. No overt structural evidence of inflammatory, infiltrative or regenerative pathology is evident. Vascular and biliary tracts are of normal volume with no evidence of congestion. No pathological hepatic lymphadenopathy observed. The gall bladder lumen is moderately distended. A bi-lobed confirmation is suspected. The wall is normal in thickness. Luminal contents are mostly anechoic. The cystic and common bile ducts are normal.

REFERRING VET

Dr. Brennan

Gastrointestinal

The stomach and intestine are free of stasis and exhibit normal peristaltic activity. The gastric lumen is not distended. The gastric wall and pylorus are normal in thickness with a normal layering pattern. The pyloric outflow tract is patent. The small intestinal lumen is not dilated. The small intestinal wall is normal to moderately thickened (up to 0.36 cm) with a normal layering pattern and appropriate mural detail. There is disruption in the normal 1:3 muscularis: mucosal ratio in most segments with a 1:1 ratio in some segments. Discreet masses are not identified. The colonic wall is normal. No obstructive disease is noted.

INVOICE

13225

Pancreas

The region of the pancreas is isoechoic relative to surrounding omental fat. No obvious parenchymal abnormalities are observed. There is no evidence of regional inflammation or effusion.

Free Abdomen

There is no evidence of free fluid. A few prominent mesenteric lymph nodes are visualized, the largest measuring 1.61 cm in length.

ULTRASONOGRAPHIC FINDINGS

Primary Findings:

- The small intestinal wall changes are most consistent with inflammatory bowel disease with potential for emerging lymphoma.
- The prominent abdominal lymph nodes are most consistent with reactive lymphadenitis or lymphoid hyperplasia. Neoplastic infiltration is considered less likely.

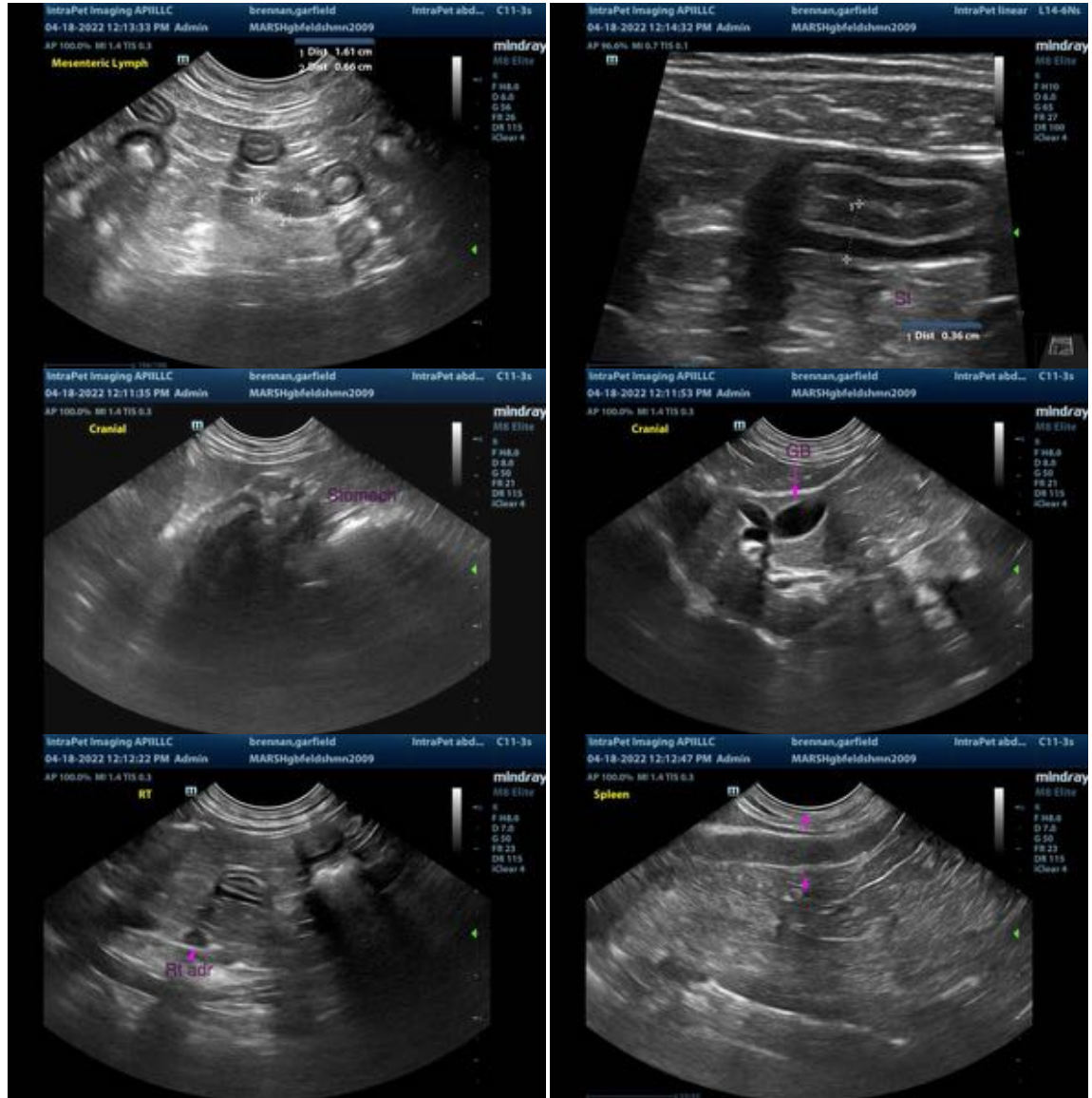
Secondary Findings:

- Bilateral, non-specific age-related renal changes.
- Bi-lobed gallbladder- incidental.

INTERPRETATION OF THE FINDINGS & FURTHER RECOMMENDATIONS

The following diagnostic/treatment recommendations can be considered:

1. Serum cobalamin, folate, PLI and TLI
2. A fecal evaluation for ova/Giardia
3. A 6-week limited antigen diet trial to assess for food allergies
4. For patients where chronic vomiting is present but additional diagnostics are not to be performed, consider triple therapy as empirical treatment for Helicobacter gastritis:
Amoxicillin: 10-22 mg/kg PO q 12 hours x 14-21 days
Metronidazole: 10-15 mg/kg PO q 12 hours for 14-21 days
Omeprazole: 0.7 mg/kg PO q 24 hours for 14-21 days
(+/- the addition of Bismuth subsalicylate: 3.85 mg/kg PO q 6-8 hours x 14-21 days)
5. Also consider heartworm antigen and antibody testing as heartworm disease can be a cause of chronic vomiting in cats.
6. Thoracic radiographs (three-view) are recommended to assess for occult esophageal disease.
7. If the above diagnostics/therapeutics are inconclusive, endoscopic or surgical gastrointestinal biopsies may be warranted.



The information and recommendations provided are based on the images presented by the referring veterinarian. No evaluation can be communicated regarding pathology that was not visible in the image/video clips provided.

Thank you for this referral. If the clinical or image interpretation does not parallel your findings or if I can be of any further assistance please contact me.

Andrea Nicastro, DVM, Diplomate ACVIM (*Small Animal Internal Medicine*)
 Andrea.nicastro@sonopath.com