

**DATE**

4/18/22

PRESENTING CLINICAL SIGNS

Work up prior to dental surgery. June 2021: Heart - No murmur (appreciated today) or arrhythmia. Strong peripheral synchronous pulses
h/o intermittent vomiting and h/o murmur - noted by previous hospital, grade 1-2.

PATIENTD'Artagnen
Sappenfield

Current Medications: None.

Date of Previous IntraPet Ultrasound: No previous.

Sedation: Not required to complete full diagnostic ultrasound.

Stat Report: Not requested.

Imaging Performed By: Andi Parkinson

SPECIES

Feline

BREED

Domestic shorthair

SEX

Male, neutered

AGE

4/28/2011

WEIGHT

14.94 lbs.

INTERPRETED BY

Andrea Nicastro, DVM,
Diplomate ACVIM
(*Small Animal Internal
Medicine*)

HOSPITAL NAME

Happy Tails VH

REFERRING VET

Dr. Calpeno

INVOICE

13224

ULTRASONOGRAPHIC EXAMINATION OF THE ABDOMEN**Urinary System**

The urinary bladder, trigone, and pelvic urethra are normal in thickness and the mucosal surface is smooth. The bladder lumen is moderately distended. A small to moderate amount of suspended echogenic debris is observed within the lumen. No masses, inflammatory changes or calculi are observed. Ureteral papillae and visualized portion of the proximal urethra, visible to a depth of 2 cm, are normal.

The left kidney is normal size (4.28 cm in length); normal shape and architecture with smooth peripheral margins. There is a normal 1:3 cortex to medulla ratio with minimal to mild loss of corticomedullary distinction. There is no evidence of pyelectasia, nephroliths, infarcts or hydroureter.

The right kidney is normal size (4.68 cm in length); normal shape and architecture with smooth peripheral margins. There is a normal 1:3 cortex to medulla ratio with minimal to mild loss of corticomedullary distinction. There is no evidence of pyelectasia, nephroliths, infarcts or hydroureter.

Adrenal Glands

The region of the adrenal glands is evaluated. No obvious pathology is observed.

Spleen

The spleen is normal in size (0.91 cm in width at the level of the hilus) with a normal capsular contour. There is appropriate echogenicity and echotexture. No focal lesions are observed. Splenic vasculature is normal.

Liver

The liver is subjectively normal in size with normal contours and structure. There is appropriate echogenicity and echotexture. No overt structural evidence of inflammatory, infiltrative or regenerative pathology is evident. Vascular and biliary tracts are of normal volume with no evidence of congestion. No pathological hepatic lymphadenopathy observed. The gall bladder lumen is moderately distended. The wall is thin and smooth. Luminal contents are anechoic. The cystic and common bile ducts are normal.

Gastrointestinal

The stomach and intestine are free of stasis and exhibit normal peristaltic activity. The gastric lumen is mildly fluid distended. The gastric wall and pylorus are normal in thickness with a normal layering pattern. The pyloric outflow tract is patent. The small intestinal lumen is not dilated. The small intestinal wall is normal to borderline thickened (up to 0.27 cm) with a normal layering pattern and appropriate mural detail. There is disruption in the normal 1:3 muscularis: mucosal ratio in most segments. Discreet masses are not identified. The ileocecal colic junction and colonic wall are normal. No obstructive disease is noted.

Pancreas

The left limb of the pancreas is visible with normal curvilinear peripheral contours. The parenchyma is largely isoechoic relative to surrounding omental fat. No distinct focal lesions are observed. The pancreatic duct is

not overtly dilated.

Free Abdomen

The peritoneal cavity is normal. There is no evidence of inflammation or effusion. The abdominal lymph nodes are normal/not visible.

ULTRASONOGRAPHIC FINDINGS

Primary Findings:

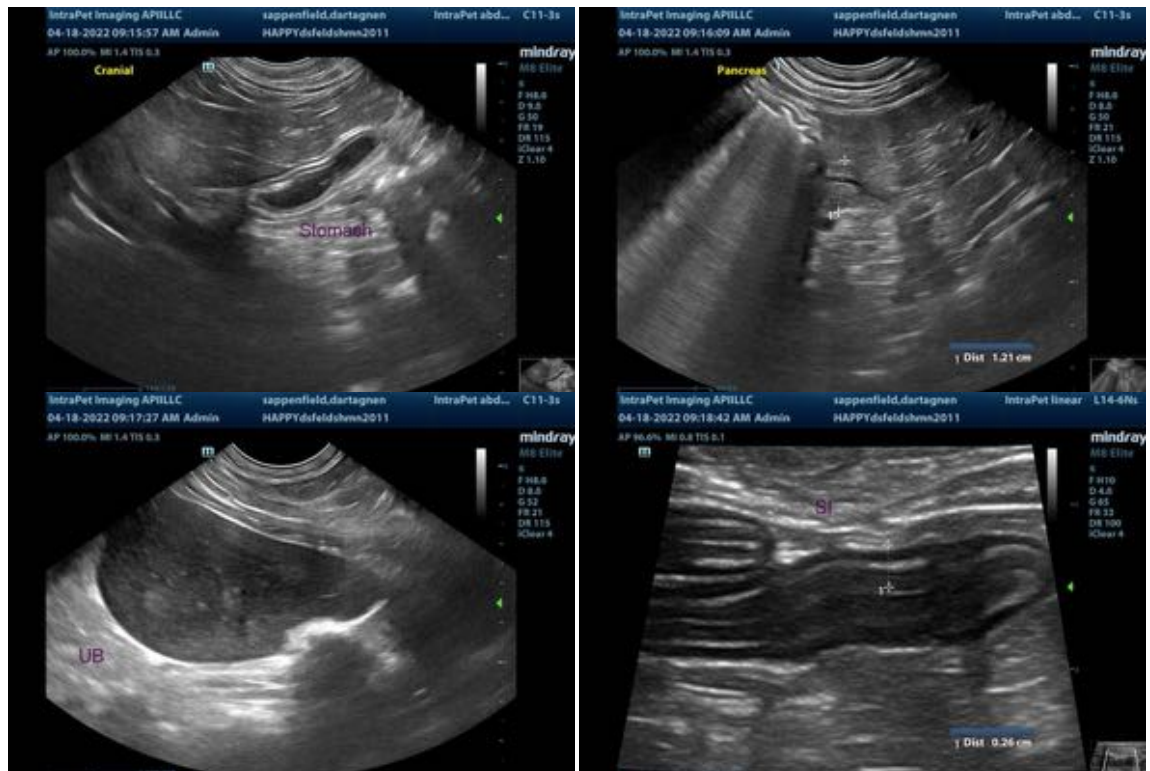
- Bowel pattern suggestive of inflammatory bowel disease. There is some potential for emerging lymphoma. However, neoplasia is considered less likely at this time.

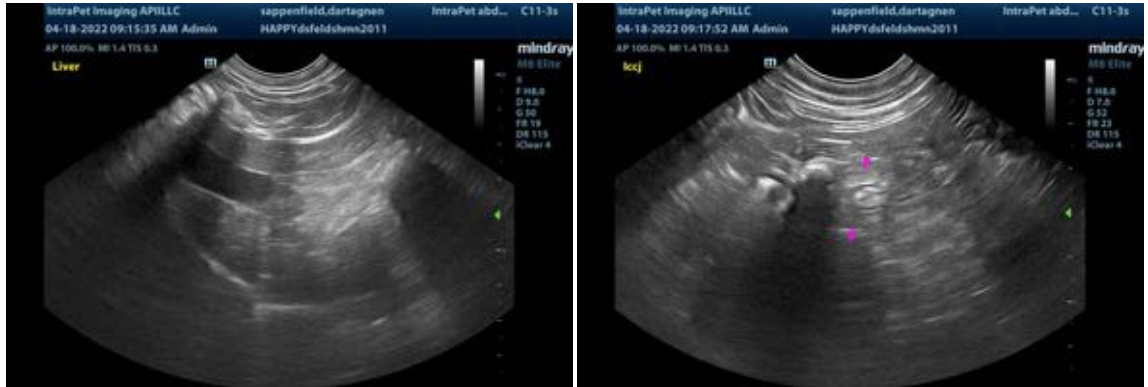
Secondary Findings:

- Minor age-related renal changes.
- Urinary bladder debris.

INTERPRETATION OF THE FINDINGS & FURTHER RECOMMENDATIONS

Given the history of chronic intermittent vomiting, further workup could include a GI panel (send to Texas A&M), fecal evaluation for ova and Giardia, hypoallergenic diet trial +/- GI biopsies (i.e., endoscopic or surgical).





The information and recommendations provided are based on the images presented by the referring veterinarian. No evaluation can be communicated regarding pathology that was not visible in the image/video clips provided.

Thank you for this referral. If the clinical or image interpretation does not parallel your findings or if I can be of any further assistance please contact me.

Andrea Nicastro, DVM, Diplomate ACVIM (*Small Animal Internal Medicine*)
Andrea.nicastro@sonopath.com