

PATIENT PRESENTING CLINICAL SIGNS

Ernie Malsatzki History: Bouts of vomiting and diarrhea every 7 to 10 days. Intermittent hyporexia, bilious vomiting, history of IMHA, CHF, 5/6 murmur, dental disease.
SPECIES Zyrtec, enalapril 2.5mg bid, pimobendan 2.5 mg 1/2 bid, furosemide 12.5 mg tab 1/4 bid
 Abnormal PE/Chem/CBC/UA Results: Anaplasma positive. All else WNL USG 1.058 PLT 395 HCT
Canine 58.2%

BREED ULTRASONOGRAPHIC EXAMINATION OF THE ABDOMEN

Chihuahua *Urinary System*

SEX

Neutered Male

AGE

11 years 7 mos

WEIGHT

11 lbs

INTERPRETED BY

Andrea Nicastro DVM
 Diplomate ACVIM
 (Sm Animal Internal Med)

IMAGING PERFORMED BY

Chloe Lowe, CVT

HOSPITAL NAME

Kingston AH

REFERRING VET

Dr. Alden

INVOICE

22866

DATE

4-15-26

The urinary bladder wall is normal in thickness. The mucosal surface is smooth. The bladder is moderately distended. Luminal contents are mostly anechoic. No cystic calculi are observed. The region of the trigone and the proximal urethra, visible to a depth of 2 cm, are normal.

The prostate is normal in size (0.97 cm in width) and shape. Parenchyma is homogenous. The prostatic urethra appears normal without evidence of dilation or obstruction.

The left kidney is normal in size (4.06 cm in length) with a normal shape, smooth peripheral margins, and normal internal architecture. There is mild loss of corticomedullary distinction. Several hyperechoic shadowing diverticular foci are observed. At least one, small, mineralized focus is observed in the cortex. There is no evidence of pyelectasia, infarcts or hydronephrosis. Renal vasculature is normal.

The right kidney is normal in size (3.95 cm in length) with a normal shape, architecture and smooth peripheral margins. There is a normal 1:3 cortex to medulla ratio with minimal- to mild loss of corticomedullary distinction. There is no evidence of pyelectasia, nephroliths, infarcts or hydronephrosis. Renal vasculature is normal.

Adrenal Glands

The left adrenal gland is normal in size (0.45 cm at cranial pole) (0.47 cm at caudal pole) with a normal shape and homogenous parenchyma. The glandular echogenicity and detail are unremarkable. Capsule, cortex, and medullary definition are normal. The phrenicoabdominal vein and surrounding vasculature are normal.

The right adrenal gland is normal in size (0.99 cm at cranial pole) (0.38 cm at caudal pole) with a normal shape and homogenous parenchyma. The glandular echogenicity and detail are unremarkable. Capsule, cortex, and medullary definition are normal. The phrenicoabdominal vein and surrounding vasculature are normal.

Spleen

The spleen is normal in size (1.18 cm in width at the level of the hilus) with a normal capsular contour. There is appropriate echogenicity and echotexture. No focal lesions are observed. Splenic vasculature is normal.

Liver

The liver is prominent-in-size, with smooth peripheral contours. The parenchyma is isoechoic- to to slightly hypoechoic relative to the spleen and diffusely homogeneous in appearance. No distinct focal lesions are observed. Vascular and biliary tracts are of normal volume with no evidence of congestion.

The gallbladder lumen is moderately distended. The wall is thin and smooth. Luminal contents are mostly anechoic. The cystic and common bile ducts are normal/not seen.

Gastrointestinal

The gastric lumen is not distended. The gastric wall is normal in thickness with a normal layering



PATIENT Ernie Malsatzki pattern. The small intestinal lumen is not dilated. The small intestinal wall is normal in thickness with a normal layering pattern and appropriate mural detail. Discreet masses are not identified. The colonic wall is normal. There is no evidence of an obstructive pattern.

SPECIES *Pancreas*
 Canine The region of the pancreas is isoechoic relative to surrounding omental fat. No obvious parenchymal abnormalities are observed. There is no evidence of regional inflammation or effusion.

BREED *Lymph Nodes*
 Chihuahua The abdominal lymph nodes are normal/not visible.

SEX *Free Abdomen*
 Neutered Male The peritoneal cavity is normal. There is no evidence of inflammation or effusion.

ULTRASONOGRAPHIC FINDINGS

- Equivocal hepatomegaly
- Mild bilateral nonspecific age-related renal changes

AGE 11 years 7 mos

*An obvious cause for the patient's clinical signs is not definitively identified in this study. Considerations include a microscopic enteropathy (i.e., food allergy/intolerance, inflammatory bowel disease, infectious/parasitic disease), underlying metabolic issue, other.

WEIGHT 11 lbs

INTERPRETATION OF THE FINDINGS & FURTHER RECOMMENDATIONS

INTERPRETED BY

The following diagnostics/treatment recommendations can be considered:

Andrea Nicastro DVM
 Diplomate ACVIM
 (Sm Animal Internal Med)

1. Texas GI panel including serum cobalamin, folate, PLI, TLI and resting cortisol level
2. A fecal evaluation for ova/Giardia
3. Prophylactic deworming with fenbendazole.
4. A 3-4-week hypoallergenic or hydrolyzed protein diet trial
5. Also consider initiating a probiotic with a high colony count +/- fiber supplement (i.e., psyllium).
6. Depending on the results of the above diagnostics/therapeutics, endoscopic or surgical gastrointestinal biopsies may be warranted.
7. Three-view thoracic radiographs should be performed prior to any anesthetic event.

IMAGING PERFORMED BY

Chloe Lowe, CVT

HOSPITAL NAME

Kingston AH

REFERRING VET

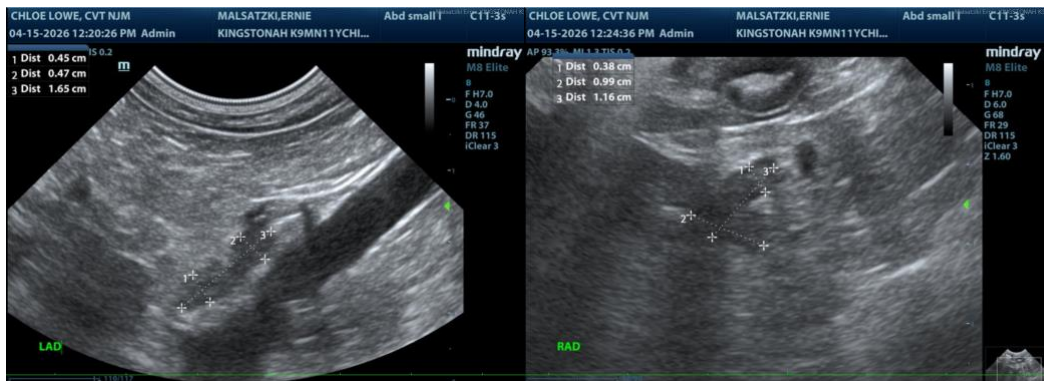
Dr. Alden

INVOICE

22866

DATE

4-15-26





PATIENT

Ernie Malsatzki

SPECIES

Canine

BREED

Chihuahua

SEX

Neutered Male

AGE

11 years 7 mos

WEIGHT

11 lbs

INTERPRETED BY

Andrea Nicastro DVM
 Diplomate ACVIM
 (Sm Animal Internal Med)

IMAGING PERFORMED BY

Chloe Lowe, CVT

HOSPITAL NAME

Kingston AH

REFERRING VET

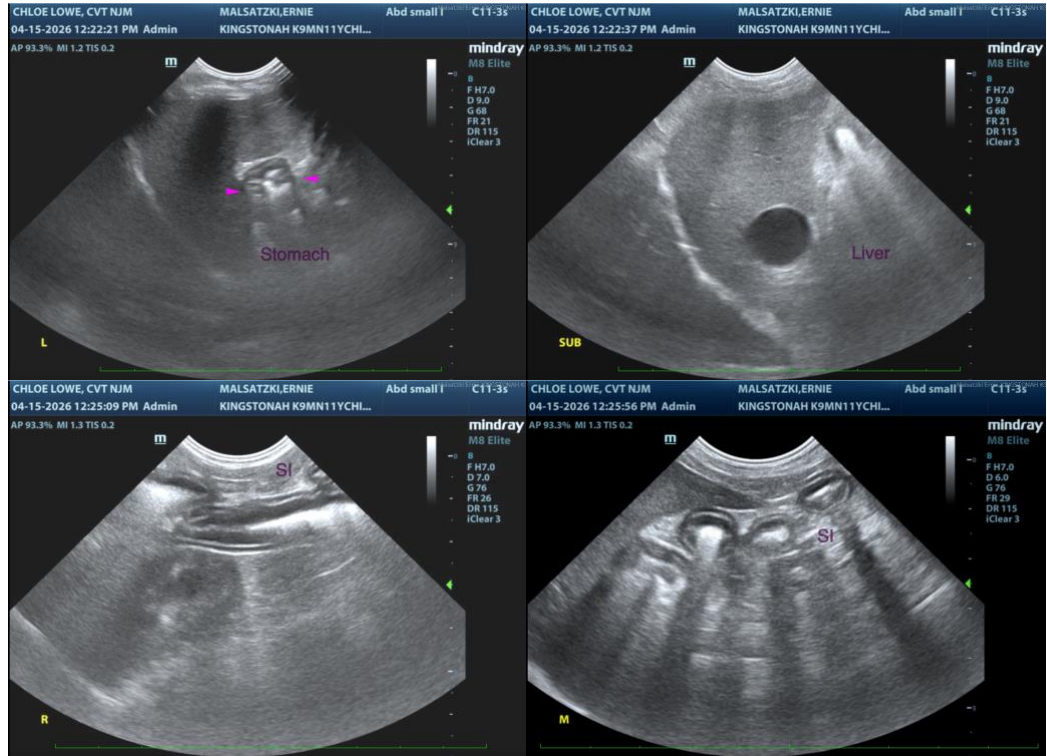
Dr. Alden

INVOICE

22866

DATE

4-15-26



The information and recommendations provided are based on the images presented by the referring veterinarian/sonographer. No evaluation can be communicated regarding pathology that was not visible in the image/video clips provided.

Thank you for this referral. If the clinical or image interpretation does not parallel your findings or if I can be of any further assistance, please contact me.

Andrea Nicastro, MPH, DVM, Diplomate DACVIM (Small Animal Internal Medicine)
info@SonoPath.com