



PATIENT PRESENTING CLINICAL SIGNS

Joey Winters

History: Increased alkaline phosphates, r/o liver disease
Abnormal PE/Chem/CBC/UA Results: cbc wnl alkphos 430 urine specific gravity 1.08

SPECIES

Canine

ULTRASONOGRAPHIC EXAMINATION OF THE ABDOMEN

BREED *Urinary System*

Mini Poodle

The urinary bladder, trigone, and pelvic urethra are normal in thickness and the mucosal surface is smooth. The bladder lumen is moderately distended with anechoic urine. No masses, inflammatory changes or calculi are observed. Ureteral papillae and visualized portion of the proximal urethra, visible to a depth of 2 cm, are normal.

SEX

Neutered Male

The prostate is normal in size (0.82 cm in width) and shape. Parenchyma is homogenous. The prostatic urethra appears normal without evidence of dilation or obstruction.

AGE

10 years

The left kidney presented normal size (4.69 cm in length); normal shape and architecture with smooth peripheral margins. A few cortical cysts are present, the largest measuring 0.59 cm in diameter. There is a normal 1:3 cortex to medulla ratio with normal corticomedullary distinction. There is no evidence of pyelectasia, nephroliths, infarcts or hydroureter. Renal vasculature is normal.

WEIGHT

28 lbs

The right kidney presented normal size (4.80 cm in length); normal shape and architecture with smooth peripheral margins. One to two small cortical cysts are seen. There is a normal 1:3 cortex to medulla ratio with normal corticomedullary distinction. There is no evidence of pyelectasia, nephroliths, infarcts or hydroureter. Renal vasculature is normal.

INTERPRETED BY *Adrenal Glands*

Andrea Nicastro, DVM,
Diplomate ACVIM (*Small Animal Internal Medicine*)

The left adrenal gland is normal size (0.50 cm at cranial pole) (0.57 cm at caudal pole) (2.37 cm in length); normal shape; homogenous parenchyma. The glandular echogenicity and detail are unremarkable. Capsule, cortex, and medullary definition are normal. The phrenicoabdominal vein and surrounding vasculature are normal.

IMAGING PERFORMED BY

Dr. Carlos Abdul-Chani

The right adrenal gland is normal size (0.54 cm at cranial pole) (0.53 cm at caudal pole) (2.61 cm in length); normal shape; homogenous parenchyma. The glandular echogenicity and detail are unremarkable. Capsule, cortex, and medullary definition are normal. The phrenicoabdominal vein and surrounding vasculature are normal.

HOSPITAL NAME

Byram AH

Spleen

The spleen is prominent in size (2.03 cm in width at the level of the hilus) with slightly swollen peripheral contours. The parenchyma is subtly mottled in appearance. A few, small myelolipomas are observed in the region of the hilus. Splenic vasculature is normal.

REFERRING VET

Dr. Carlos Abdul-Chani

Liver

The liver is subjectively prominent in size with swollen curvilinear peripheral contours. The parenchyma is isoechoic relative to the spleen and exhibits mild heterogeneity. No distinct focal lesions are observed. Hepatic vasculature and biliary tracts are of normal volume with no evidence of congestion. The portal vein to caudal vena cava ratio is approximately 1: 1.

INVOICE

10753

DATE

4/15/22

The gall bladder lumen is moderately distended. The wall is thin and smooth. A moderate amount of echogenic-to-mineralized gravity dependent debris is observed within the lumen. The cystic and common bile ducts are normal.

Gastrointestinal

The stomach and intestine are free of stasis and exhibit normal peristaltic activity. The gastric lumen is not distended. The gastric wall and pylorus are normal in thickness with a normal layering pattern. The small intestinal lumen is not dilated. The small intestinal wall thickness is normal with a normal layering pattern and appropriate mural detail. Discreet masses are not identified. The colonic wall is normal. No obstructive or overt infiltrative disease is noted.

Pancreas

The base and right limb of the pancreas is visible with normal curvilinear peripheral contours. The parenchyma is largely isoechoic relative to surrounding omental fat and slightly mottled in appearance. The pancreatic duct is visible but not overtly dilated. There is no evidence of peripancreatic inflammation or effusion.

Free Abdomen

The peritoneal cavity is normal. There is no evidence of inflammation or effusion. The abdominal lymph nodes are normal/not visible.

ULTRASONOGRAPHIC FINDINGS

Primary Findings

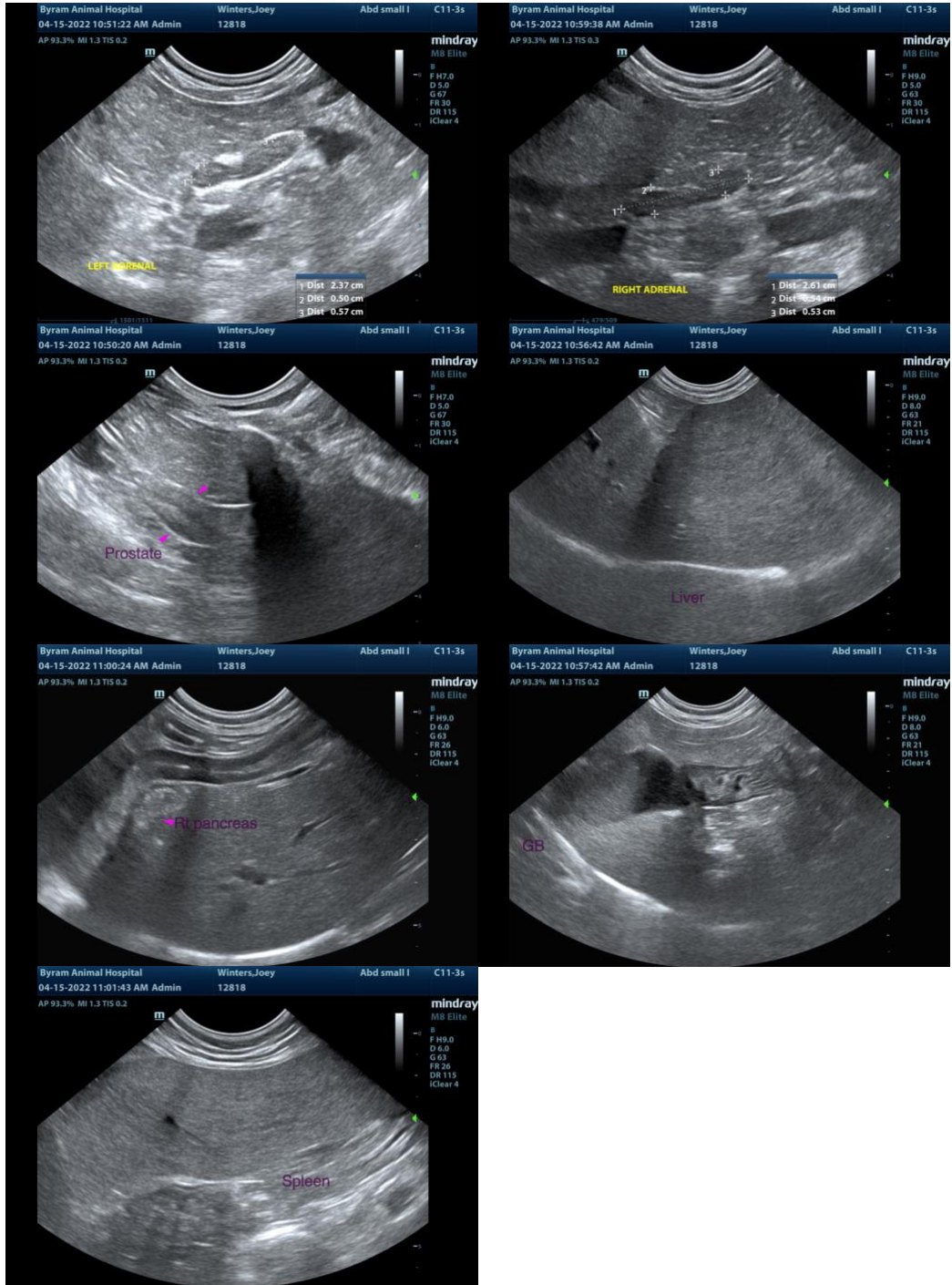
- The diffuse hepatic changes are non-specific and could be consistent with vacuolar hepatopathy, regenerative nodular hyperplasia, and/or age-related remodeling. Inflammatory and infiltrative disease are considered less likely.
- Gall bladder debris, non-mucocele
- The pancreatic changes are most consistent with age-related parenchymal remodeling, potentially secondary to a prior inflammatory episode, early fibrosis or chronic pancreatitis.
- The splenic parenchyma changes are most consistent with a benign process such as lymphoid hyperplasia, extramedullary hematopoiesis or splenitis with a low possibility of infiltrative neoplasia (i.e., lymphoma, mast cell neoplasia).

INTERPRETATION OF THE FINDINGS & FURTHER RECOMMENDATIONS

Serial monitoring (i.e., every 3-4 months) of the patient's liver values is recommended. If values continue to increase, a repeat abdomen ultrasound +/- a more advanced hepatic work-up (i.e., tissue sampling) may be warranted.

Consider testing for hyperadrenocorticism with a low-dose dexamethasone suppression test or ACTH stimulation test if clinical signs (i.e., PU/PD) develop in the future.

Regarding the splenic changes, a fine-needle aspirate can be considered to rule out emerging neoplasia (if clotting status is appropriate).



The information and recommendations provided are based on the images presented by the referring veterinarian/sonographer. No evaluation can be communicated regarding pathology that was not visible in the image/video clips provided.

Thank you for this referral. If the clinical or image interpretation does not parallel your findings or if I can be of any further assistance, please contact me.

Andrea Nicastro, DVM, Diplomate DACVIM (Small Animal Internal Medicine)
info@SonoPath.com