

**DATE PRESENTING CLINICAL SIGNS**

4/14/2022 Apparently "healthy" but numerous biochem abnormalities.

PATIENT

Bandit Doering

Current Medications: Enrofloxacin 68mg ½ SID for 2 weeks (completed)

Lab Results: HCT 27.3, RBC 6.38, HGB 8.9, Na 141, Cl 111, TP 15, Alb 1.8, Glob 13.2, Cholesterol 79, UPC 1.4, USG 1.014.

Date of Previous IntraPet Ultrasound: No previous.

Sedation: Not required to complete full diagnostic ultrasound.

Stat Report: Not requested.

Imaging Performed By: Stephanie Pearce RDCS, RVT.

SPECIES

Canine

BREED

DSH

SEX

Neutered Male

AGE

4/27/2009

WEIGHT

11.88 lbs

INTERPRETED BY

Andrea Nicastro,
DMV, Diplomate
DACVIM (Small Animal
Internal Medicine)

HOSPITAL NAME

North Laurel Animal
Hospital

REFERRING VET

Dr. Cohn

INVOICE

10746

ULTRASONOGRAPHIC EXAMINATION OF THE ABDOMEN**Urinary System**

The urinary bladder, trigone, and pelvic urethra are normal in thickness and the mucosal surface is smooth. The bladder lumen is moderately distended. A small amount of suspended echogenic debris is observed within the lumen. No masses, inflammatory changes or calculi are observed. Ureteral papillae and visualized portion of the proximal urethra, visible to a depth of 1 cm, are normal.

The left kidney presented normal size (3.57 cm in length); normal shape and architecture with smooth peripheral margins. There is a normal 1:3 cortex to medulla ratio with mild loss of corticomedullary distinction. There is no evidence of pyelectasia, nephroliths, infarcts or hydroureter. Renal vasculature is normal.

The right kidney presented normal size (4.15 cm in length); normal shape and architecture with smooth peripheral margins. There is a normal 1:3 cortex to medulla ratio with mild loss of corticomedullary distinction. There is no evidence of pyelectasia, nephroliths, infarcts or hydroureter. Renal vasculature is normal.

Adrenal Glands

The left adrenal gland is normal size (0.47 cm width). Normal shape and glandular echogenicity. The phrenicoabdominal vein and surrounding vasculature are normal.

The right adrenal gland is normal size (0.46 cm width). Normal shape and glandular echogenicity. The phrenicoabdominal vein and surrounding vasculature are normal.

Spleen

The spleen is normal in size (0.89 cm in width at the level of the hilus) with a normal capsular contour. There is appropriate echogenicity and echotexture. No focal lesions are observed. Splenic vasculature is normal.

Liver

The liver is subjectively subjectively prominent to enlarged in size with swollen to slightly irregular peripheral contours. The parenchyma is hyperechoic relative to the spleen and mottled/heterogenous in appearance. A 0.91 x 0.58 cm heterogenous nodule is observed on the left side. No distinct focal lesions are observed, although there is a focal irregular swelling of the capsule deep on the left side. Hepatic vasculature and intrahepatic biliary tracts are of normal volume with no evidence of congestion. The portal vein to caudal vena cava ratio is approximately 1: 1.

The gall bladder lumen is moderately distended. The wall is thin and smooth. A mild to moderate amount of mostly gravity dependent echogenic debris is observed within the lumen. The cystic and common bile ducts are normal.

Gastrointestinal

The stomach and intestine are free of stasis and exhibit normal peristaltic activity. The gastric lumen is not distended. The gastric wall and pylorus are normal in thickness with a normal layering pattern. The pyloric outflow tract is patent. The small intestinal lumen is not dilated. The small intestinal wall thickness is normal with a normal layering pattern and appropriate mural detail. There is disruption in the normal 1:3 muscularis: mucosal ratio in some segments. Discreet masses are not identified. The ileocecal colic junction and colonic wall are normal. No obstructive disease is noted.

Pancreas

The left limb and body are visible with minimal deviation from the normal peripheral contours. The parenchyma is hypoechoic relative to surrounding omental fat, with a few, small hypoechoic nodules seen. The pancreatic duct is visible, but not overtly dilated (0.14 cm in diameter).

Free Abdomen

There is no evidence of free fluid. The mesentery in the cranial abdomen is mildly hyperechoic. One to two colic lymph nodes are visualized, the largest measuring 0.45 cm in length.

ULTRASONOGRAPHIC FINDINGS

Primary Findings

- The hepatic changes could be consistent with a diffuse inflammatory process (i.e., bacterial cholangiohepatitis, lymphoplasmacytic hepatitis). However, in light of the severe hyperglobulinemia, infiltrative neoplasia (i.e., lymphoma) or FIP are also top considerations.
- The cranial peritonitis may be secondary to hepatic, pancreatic, or renal pathology.

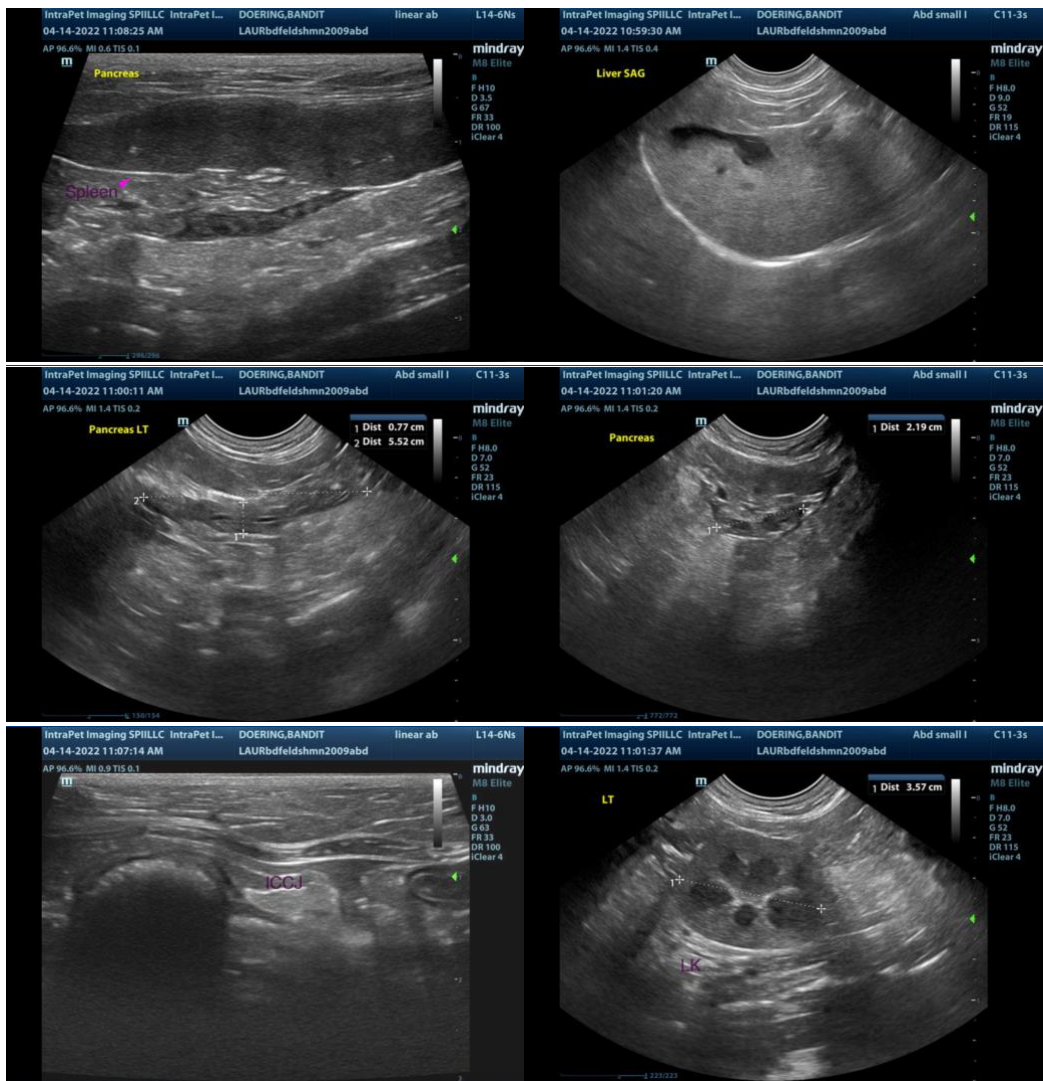
Secondary Findings

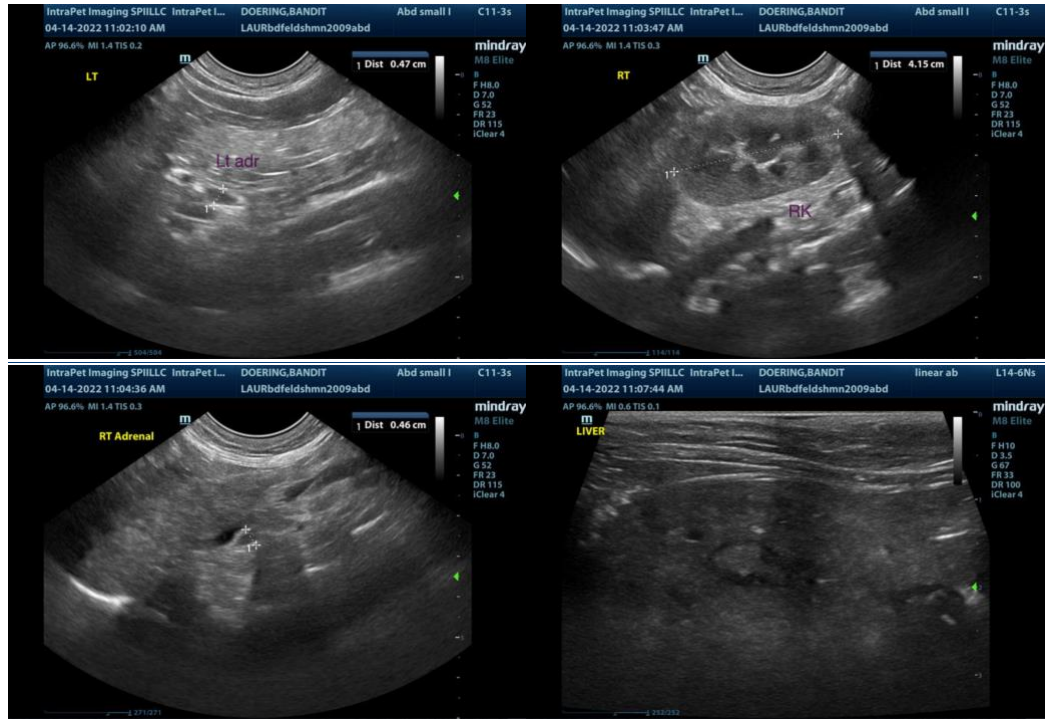
- The pancreatic changes are suggestive of chronic pancreatitis with benign nodular hyperplasia.
- Bowel pattern consistent with inflammatory bowel disease. However, correlation with clinical findings is recommended.
- Minor, age-related renal changes
- The lymph node changes are most consistent with reactive lymphadenitis or lymphoid hyperplasia.

INTERPRETATION OF THE FINDINGS & FURTHER RECOMMENDATIONS

- Given the hyperglobulinemia, three-view thoracic radiographs are recommended to assess for neoplasia in the chest.
- A fine-needle aspirate of the liver is also recommended (if clotting status is appropriate).

- A serum protein electrophoresis should also be considered to help determine if the patient has a monoclonal versus a polyclonal gammopathy.
- Depending on the results of the above diagnostics, a bone marrow aspirate may be warranted to further evaluate for multiple myeloma or other neoplasia.
- Given the presence of a proteinuria, consider initiation of an ACE inhibitor or an angiotensin receptor blocker, with serial monitoring of the patient's renal values, UPC and blood pressure to assess for progression and side effect.





The information and recommendations provided are based on the images presented by the referring veterinarian/sonographer. No evaluation can be communicated regarding pathology that was not visible in the image/video clips provided.

Thank you for this referral. If the clinical or image interpretation does not parallel your findings or if I can be of any further assistance, please contact me.

Andrea Nicastro, DVM, Diplomate DACVIM (Small Animal Internal Medicine)
info@SonoPath.com